



International Journal of Surgery Science

E-ISSN: 2616-3470
P-ISSN: 2616-3462
© Surgery Science
www.surgeryscience.com
2019; 3(3): 352-354
Received: 22-05-2019
Accepted: 24-06-2019

Dr. Arshad Hasan
MCh Resident, Department of
Urology, SCB Medical College and
Hospital Cuttack Odisha, India

Dr. Gourab Kundu
MCh Resident, Department of
Urology, SCB Medical College and
Hospital Cuttack Odisha, India

Dr. Praveen Kumar Yadav
MCh Resident, Department of
Urology, SCB Medical College and
Hospital Cuttack Odisha, India

Dr. Sabyasachi Panda
Assistant Professor, Department of
Urology, SCB Medical College and
Hospital Cuttack Odisha, India

Dr. GP Singh
Associate Professor, Department of
Urology, SCB Medical College and
Hospital Cuttack Odisha, India

Dr. D Hota
Professor, Department of Urology,
SCB Medical College and Hospital
Cuttack Odisha, India

Correspondence
Dr. Arshad Hasan
MCh Resident, Department of
Urology, SCB Medical College and
Hospital Cuttack Odisha, India

Broken and retained percutaneous nephrostomy malecot catheter: A lesson of awareness

**Dr. Arshad Hasan, Dr. Gourab Kundu, Dr. Praveen Kumar Yadav,
Dr. Sabyasachi Panda, Dr. GP Singh and Dr. D Hota**

DOI: <https://doi.org/10.33545/surgery.2019.v3.i3f.194>

Abstract

After the first description of percutaneous nephrostomy (PCN) in 1955 by Goodwin *et al.* it has become commonest & well-tolerated procedure. It is now well-established technique for urinary drainage, urinary diversion, and for access to the collecting system. But it is not free of complications. Significant hemorrhage, perforation of the intra-abdominal organs & septicemia are among the major complications and minor complications mostly catheter-related like catheter dislodgment, hematuria catheter site infection & catheter blockage are mentioned in literature. Although far from being life-threatening, broken and retained nephrostomy catheter is a rare complication. We report such a rare case of a broken and retained Malecot nephrostomy catheter which was retrieved by percutaneous nephrostomy surgery and by open method.

Keywords: Percutaneous nephrostomy, nephrostomy tube, complications, malecot catheter flower, percutaneous surgery

Introduction

PCN is safe and convenient procedure which indications can be for diagnostic and therapeutic purpose. First description of percutaneous nephrostomy (PCN) was done in 1955 by Goodwin *et al.* [1]. It is now well-established technique for urinary drainage in case of upper urinary tract obstruction and infected system, urinary diversion, and for access to the collecting system to instill therapeutic agents or to perform surgery. Various types of nephrostomy tubes are available in the market now but ideal should be biocompatible, has excellent flow characteristics, easy to insert, resists infections, encrustations & dislodgment and should not induce symptoms. Complications of UTIs. Sepsis occurs in 1.3% to 7% of patients, and trauma to adjacent organs caused by the procedure is uncommon. Thoracic complications (pneumothorax, hemothorax, hydrothorax, empyema) occur in 0.1% to 0.2% of nephrostomy tube placements. Late complications include tube dislodgement and blockage. One rare complication is breakage and retention of part of nephrostomy tube. This study describes about one of such rare complication in which part of flower end of malecot catheter entrapped in renal parenchyma and perirenal space which was removed by percutaneous nephrostomy surgery. This complication although not appears life threatening but a nightmare for the surgeon. This extra morbidity of patient put him on another surgical risk so one should be more cautious in dealing of nephrostomy tube especially during removal.

Case report

Case 1-A 45 year female, known chronic kidney disease presented earlier at an outdoor center with decrease urination found to have bilateral ureteric calculi. along with bilateral hydronephrosis 6 months ago. She underwent right double J placement and left percutaneous nephrostomy drain because in left side double j stent could not placed. She underwent right ureterolithotomy followed by left ureterolithotomy in separate sitting.. After post operative recovery malecot nephrostomy tube was removed but the tube came out broken. The retained part of the malecot tube was found to be impacted and could not be taken out. It was found to be impacted due to ingrowth of granulation tissue into the eyes of the Malecot catheter. A non-contrast computed tomography (CT) revealed the “wing” part of the nephrostomy tube engaged inside the renal parenchyma (Figure 1, Figure 2, Figure 3).

Given its location in lower pole of kidney, decision was taken to remove part of tube percutaneous nephrolithotomy. The patient was placed in lithotomy position under general anesthesia. Ureteric catheter was placed in left ureter then patient changed to prone position. Renal anatomy was delineated on fluoroscopy with giving diluted contrast. Part of stem and flower of malecot catheter was in perinephric space near inferior pole with tip embedded in renal parenchyma. So inferior calyceal puncture was done under fluoroscopy. Figure 4 is the fluoroscopic image showing puncture needle and renal calyceal anatomy with retained malecot flower. Tract progressively dilated until 30F Amplatz sheath was placed.

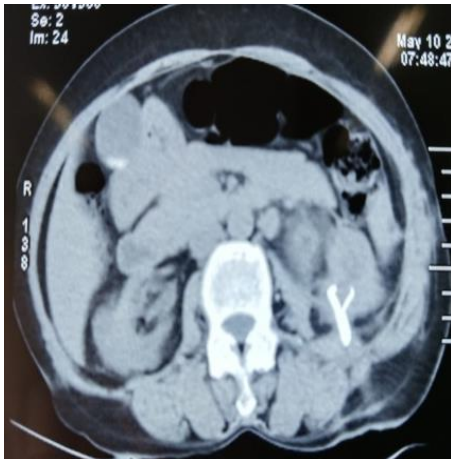

Fig 1: Axial cut section of non-contrast computed tomography showing wing part of broken malecot catheter in renal parenchyma

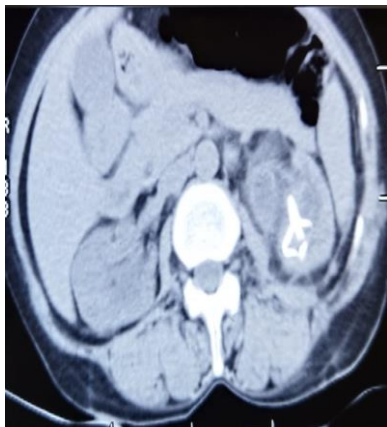

Fig 2: Axial cut section of non-contrast computed tomography showing broken malecot catheter completely in renal parenchyma

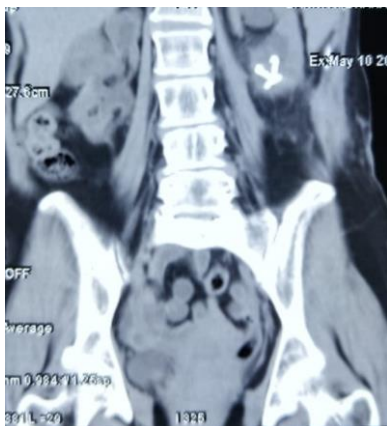

Fig 3: Coronal cut section of non-contrast computed tomography showing part of broken malecot catheter in lower pole of left kidney

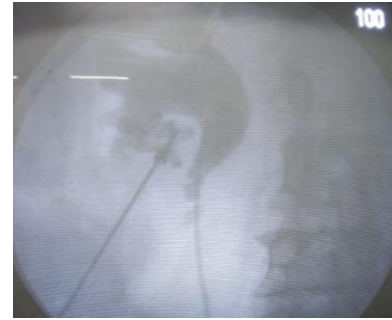


Fig 4: Intra-operative fluoroscopic image showing part of initial puncture needle & renal calyceal anatomy with retained broken malecot flower

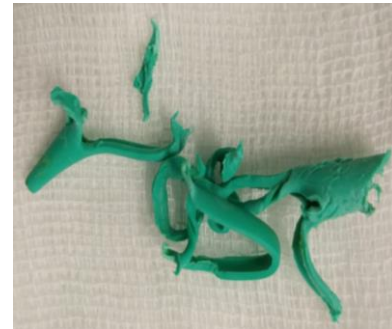

Fig 5: Removed specimen image of part of broken malecot catheter

All parts of malecot catheter were removed after cutting fibrosis and tissue ingrowth. Figure 5 is the removed part of malecot catheter. Final nephrostogram displayed no any retained fragment of malecot catheter without any subsequent bleeding. A DJ-stent was placed. Recovery was without incident and she was discharged the next day.

Case 2: A 55 year female, known diabetic presented earlier at an outdoor center with fever, right flank pain and decrease urination found on evaluation to have right emphysematous pyelonephritis. She underwent right percutaneous nephrostomy drain. After complete control of blood sugar and recovery from emphysematous pyelonephritis malecot nephrostomy tube was removed but the tube came out broken. The retained part of the malecot tube was found to be impacted and could not be taken out. It was found to be impacted due to ingrowth of granulation tissue into the eyes of the Malecot catheter. X-ray kidney ureter bladder showed retain part of malecot nephrostomy tube (Figure 6). A x- ray intravenous urography was done which revealed the “wing” part of the nephrostomy tube engaged inside the renal parenchyma and excreting kidney (Figure 7).

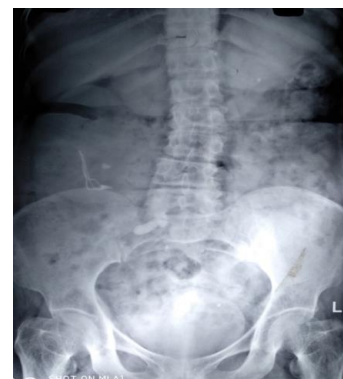

Fig 6: X-ray kidney ureter bladder showed retain part of malecot nephrostomy tube

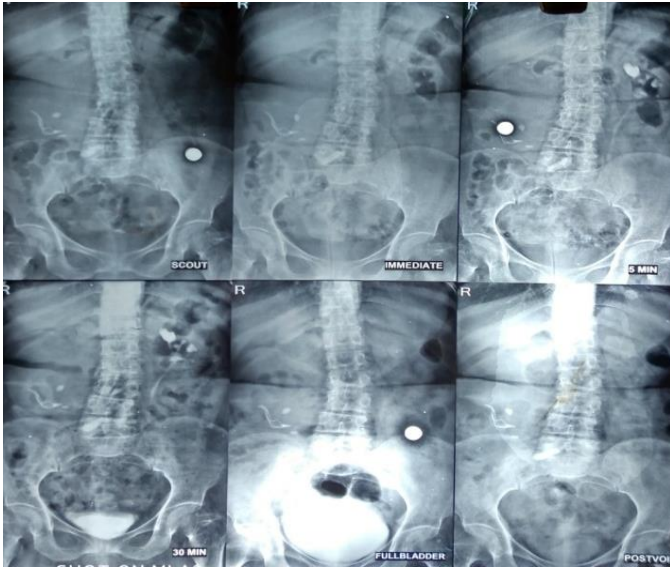


Fig 7: Films of x- ray intravenous urography revealed the “wing” part of the nephrostomy tube engaged inside the renal parenchyma and excreting kidney

Given its location decision was taken to remove part of tube by open surgical exploration. The patient was placed in right flank position under spinal anesthesia. Malecot nephrostomy tube was removed. Post operative recovery was uneventful.

Discussion

Percutaneous nephrostomy drain is an effective method of urinary drainage in upper urinary tract obstruction, infected renal system, urinary diversion, and for access to collecting system to instill therapeutic agents or to perform surgery. These drains are usually either pigtail catheters or Malecot catheters. The external surface of catheters is smooth and most of the times easily removed. However tissue ingrowth into the holes in the drain can develop and creates problem during its removal [2]. Because of large bore size of the hole and same point of all four holes location near the tip, a malecot-type flower tip is theoretically more prone to tissue ingrowth, which can form a tissue bridge running across through the interior of the catheter. Fragmentation of catheter is also known and may occur in the process of removal of a fixed catheter [3]. This is a disastrous iatrogenic avoidable complication, which prevented by not keeping the drain beyond its clinical expiry date of utility. In this study also, flower of the Malecot catheter broke during removal. Although not being a life-threatening situation, this complication can alter the patient's postoperative course and morbidity [4]. Malecot nephrostomy tubes placed in small intrarenal pelves are prone to entrapment secondary to a healing tissue bridge growing over 1 or more of the flanges. Entrapped nephrostomy tubes should not be forcibly removed due to potential significant injury and 1 or incomplete tube removal. Under endoscopic visualization, dense tissue bridges may be recognized and incised successfully to allow for complete nephrostomy tube removal [5]. Various methods are in literature required for removal of retained catheters left for a long time which are prone to infection. Entrapped nephrostomy tube can be removed by open method, Laparoscopic method, endoscopic method or percutaneous approach. In this study, the entrapped nephrostomy tubes were removed percutaneously by puncturing along tube, and cutting of anchoring tissue bridge that had grown over a flange through nephroscope. Percutaneous approach can be considered in such case for safe removal and less burden to extra

morbidity. Endoscopic approach was not considered in our case because half of the tube was lying outside the pelviciceal system. Retained nephrostomy also reported in post-operative complications in which tubeless PCNL would avoid these issues [6]. Laparoscopic removal of retained nephrostomy tube has earlier been described [7]. Percutaneous access to the broken end looked easy and less morbid than laparoscopic and open method. One should take extra cautiousness and should not applied any undue force on the drainage tube during removal. Many factors may influence the likelihood of tube dislodgment and entrapment such as body mass index of patient, distance from skin to the collecting system, degree of hydronephrosis, and factors related to the instrument of drainage. Ideal nephrostomy tube should be durable and able to maintain a stable position within the collecting system; resist kinking in and outside the body; allow for urine, blood/ clots, and stone debris to exit the body; and minimize patient discomfort [8]. So this case study is one lesson for surgeons to avoid a complication that may be extra burden for patients in mental and financial manner.

Conclusion

This is a rare iatrogenic avoidable condition of broken and entrapped malecot percutaneous nephrostomy tube which require extra attention during its removal. Percutaneous removal of this retained malecot catheter is a safe option of treatment

References

1. Goodwin WE, Casey WC, Woolf W. Percutaneous trocar (needle) nephrostomy in hydronephrosis. *J Am Med Assoc.* 1955; 157:891-4. doi: 10.1001 / jama. 1955. 02950280015005. [PubMed] [CrossRef] [Google Scholar]
2. Kumar, Nayyar. *Journal of Endourology Case Reports* 2017, 3.1 <http://online.liebertpub.com/doi/10.1089/cren.2017.0067>
3. Turo R, Horsu S, Broome J *et al.* Complications of percutaneous nephrostomy in a district general hospital. *Turk J Urol.* 2018; 44(6):478-483. doi: 10.5152 /tud.2018.37336
4. Bora Ozveren, MD; Ahmet Sahin, MDCan Urol Assoc J 2016; 10(3-4): E122-4. <http://dx.doi.org/10.5489/cuaj.3285>
5. Sardina JI, Bolton D, Stoller ML *et al.* Entrapped Malecot nephrostomy tube: Etiology and management. *J Urol.* 1995; 153:1882-1883.
6. Anderson JK, Monga M. Management of the retained percutaneous nephrostomy catheter. *JSLS.* 2006; 10:126-8
7. Biyani CS, O'Connor JP, Browning AJ *et al.* Laparoscopic removal of retained nephrostomy tubing. *J Urol* 2003; 170:916-917
8. Bayne D, Taylor ER, Hampson L *et al.* Determinants of nephrostomy tube dislodgment after percutaneous nephrolithotomy. *J Endourol.* 2015; 29:289-92. <http://dx.doi.org/10.1089/end.2014.0387>.