E-ISSN: 2616-3470
P-ISSN: 2616-3462

www.surgeryscience.com
2019; 3(4): 22-25
Received: 14-08-2019
Accepted: 18-09-2019

Rajkiran K Deshpande
DNB Resident, Department of General Surgery, Manipal Hospitals, Bangalore, Karnataka, India

Sumit Talwar
Head of the Department, Department of Minimal Access Surgery, Manipal Hospitals, Bangalore, Karnataka, India

Corresponding Author:
Rajkiran K Deshpande
DNB Resident, Department of General Surgery, Manipal Hospitals, Bangalore, Karnataka, India

A novel laparoscopic approach: (e-TEP) technique in ventral abdominal hernia-our experience

Rajkiran K Deshpande and Sumit Talwar

DOI: https://doi.org/10.33545/surgery.2019.v3.i4a.212

Abstract
Background: Enhanced view totally extra peritoneal (eTEP) repair is the novel method for inguinal hernia management. Igor Belyansky extended the principle of eTEP to ventral and incisional hernia. The eTEP technique is based on the principle that the extra peritoneal space can be created from almost anywhere in the anterior abdominal wall. The classical Totally Extra peritoneal (TEP) technique is considered closest to an ideal hernia repair, but this technique has several drawbacks such as restricted port placement, limited space for dissection and mesh placement, a low tolerance of accidental pneumoperitoneum, and difficulty in teaching and learning the technique. We present our experience with eTEP technique, which overcomes several of these drawbacks.
Methods: We conducted a short term 6 months retrospective analysis of 24 patients in our hospital who underwent eTEP procedure for umbilical hernia and inguinal hernia, with a minimum of 3 months follow-up. Their data were analyzed for operative details, intra-operative and post-operative complications.
Results: Judging from our short term results, for 24 patients we have not come across any post-operative complications like seroma, SSI, recurrence, with a minimum of 3 months follow-up.
Conclusion: Our evaluation of eTEP technique in umbilical and inguinal hernias has found the approach not only novel one but also very feasible and highly effective. This technique provides flexible port set-up optimal for laparoscopic closure of defects, along with placement of wide mesh in the retro-muscular space with no transfascial fixation while restoring abdominal wall dynamics. We suggest that the eTEP technique is the most ideal option for ventral abdominal hernia repair and can be adapted in hospitals with advanced laparoscopic setup.

Keywords: eTEP, ventral abdominal hernia repair, inguinal hernias, umbilical hernia

Introduction

In earlier 19th century ventral hernias were repaired exclusively through open approaches. Many authors described the laparoscopic approach to ventral hernia repair (LVHR), where a barrier mesh is placed in the intraperitoneal underlay position (LeBlanc and Booth, 1993) [1]. This repair relies on wide mesh overlap, penetrating fixation with tacks and transabdominal stitches without defect closure. The merits of LVHR over the open approach are less wound complication rates and faster recovery. However, LVHR elicits some serious complications like adhesive bowel obstruction, mesh erosion, and enterocutaneous fistula from direct contact between the mesh and intraperitoneal viscera (Wake *et al*., 2005; Leibl *et al*., 2005) [2, 3]. To overcome this issue, the transabdominal preperitoneal (TAPP) approach to ventral and incisional hernias has been evaluated (Prasad *et al*., 2011) [4]. However, this method lacks the ability of elevating and closing thin peritoneal flaps even in the hands of expert surgeons. Recently Belyansky *et al*. evaluated the laparoscopic Transversus Abdominis Release (l-TAR), a reconstructive technique restoring the linea alba with retromuscular mesh reinforcement. Similarly to TAPP repairs, l-TAR prevents direct mesh contact with viscera (Belyansky *et al*., 2016) [5]. Despite early success, the intracorporeal closure of the defects challenging with traditional port placement lateral to linea semilunaris.

The new technique is enhanced view totally extraperitoneal (eTEP) technique has been previously reported for laparoscopic inguinal hernia repair (Daes, 2012; Daes, 2016) [6, 7]. The main advantages of this technique are rapid and facile creation of extraperitoneal domain, large operative space, flexible port set-up, and improved tolerance of pneumoperitoneum. It was designed to facilitate learning and mastering of the procedure for the novel surgeon and for complex cases such as large inguinoscrotal, sliding, or incarcerated inguinal hernias, as well as

obese or post-bariatric patients and those with previous pelvic surgeries or a short distance between umbilicus and pubic tubercle (Daes, 2012; Daes, 2016) [6, 7].

The classical Totally Extra peritoneal (TEP) technique is considered closest to an ideal hernia repair, but this technique has several drawbacks such as restricted port placement, limited space for dissection and mesh placement, a low tolerance of accidental pneumoperitoneum, and difficulty in teaching and learning the technique. These disadvantages explain the limited use of the technique outside the circle of experts. We present our experience with eTEP technique, which overcomes several of these drawbacks

Patients and Methods

In this study, we have analyzed the data of 24 patients in Manipal Hospital, Bangalore who underwent an eTEP procedure for the para umbilical and inguinal hernias. Their data were analyzed for operative details, intra-operative and post-operative complications. The duration of study was between August, 2018 to February, 2019.

Inclusion criteria

Patients diagnosed with Para umbilical and inguinal hernias.

Exclusion criteria

Patient unable to tolerate general anaesthesia.

Technique used in the study

In this study, the eTEP was performed as described by as described by Belyansky*et al*. with a few modifications.

eTEP for Paraumbilical hernia (Fig 1)

Positioning of patient and ports

Camera Port: 12mm Supraumbilical (left paramedian), 5mm Suprapubic

Working Ports: Two 5mm – Lumbar, Iliac (MCL) and similar site on contralateral region

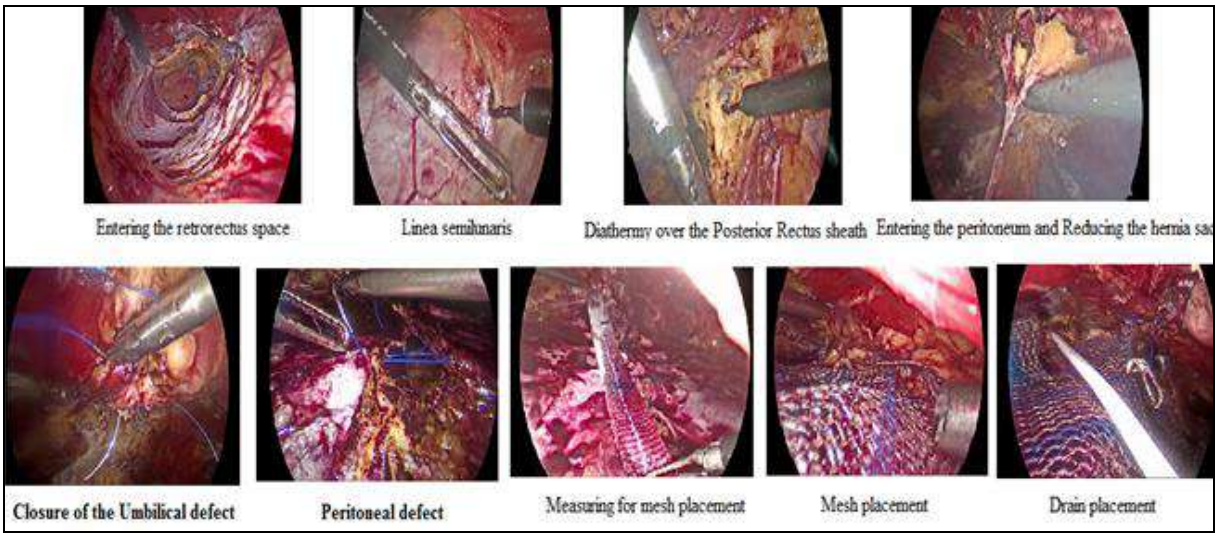

Fig 1: Procedure of e-TEP in the present study

Position

The patient is placed supine with arms tucked by the side and extended at the hips to enable instrumentation without hindrance from the pelvis and thighs.

Procedure

Entering the retrorectus space

An incision of 12-mm was made in the supraumbilical (left paramedian region). The telescope was then introduced here until the midline was crossed and both retro-rectus spaces were dissected. The dissection was carried caudally until the pubic bone was completely visualised. The lateral limit of the dissection is carefully maintained keeping medial to the linea semilunaris to prevent any inadvertent injury to the neurovascular bundle.

Limits of dissection

Superiorly- Xiphoid Process; Laterally- Linea Semilunaris; Inferiorly- Retro-Pubic space

Crossing the midline

Two 5-mm ports were made in the retro-rectus space medial to the linea semilunaris at the midclavicular line at a distance of 5 cm from each other, and similar port placement done on the contra-lateral side. The telescope was shifted to the lower port to visualize the cranial end of the space and the left posterior rectus sheath was incised at its medial margin with a diathermy hook or scissors. The yellow pad of fat was seen that represents the falciform ligament. This was dissected down from the roof to cross the midline and visualise the right posterior rectus sheath. Here, we had modified the technique for our ease. The dissection was continued caudally until we reach umbilicus.

Entering the peritoneum

The peritoneum was opened using diathermy at a safe distance from hernia sac to enter the peritoneal cavity. Peritoneum entered, sac reduced and defect (Both the peritoneal and umbilical) and Linea alba closed using V-Loc™ Prolene.

Placement of Mesh and Drain (Negative suction)

Soft Prolene TM (polypropylene) of appropriate size all around the dissection space, secured using tacks. The mesh size depends on the defect size and the space created. Sometimes a 15x15 cm or 30x30cm was used where the mesh was placed flat from one linea semilunaris to another and from epigastrium to pubis. Our personal preference is to use a soft prolene (polypropylene) macroporous mesh.

Inguinal Hernia

Positioning of patient and ports

Port placement - Camera Port: 12mm I/L Supraumbilical
Working Ports: 2x5mm I/L Paraumbilical and Infraumbilical

Position

The patient was placed supine with arms tucked by the side and extended at the hips to enable instrumentation without hindrance from the pelvis and thighs

Entering the retrorectus space

An incision of 12-mm was made supraumbilical. The dissection was carried caudally until the pubic bone was completely visualized. The other two working ports were introduced under vision on in the location as mentioned above.

Limits of dissection

Superiorly- Umbilicus; Laterally- Linea Semilunaris and ASIS (Antero-superior iliac spine); Inferiorly- Retro-Pubic space; medially (if Unilateral) – Linea Alba

Identification of anatomy

After the initial medial and lateral dissection, the Cooper's ligament was visualized. Small direct hernias were reduced by the dissecting balloon, rendering the defect visible. The cord structures were visualized. Cord lipomas and indirect hernias lie lateral to the cord structures. The location of the external iliac vein should be assessed; it may not yet be eminently clear, but the approximate location should be noted.

Direct hernia

Direct hernias were reduced by applying cephalad traction to the hernia sac with appropriate counter traction. The movement of dissection should be away from the external iliac vessels.

Indirect Hernias

Indirect sacs were usually difficult to reduce compared to a direct hernia. The indirect hernia sac was located on the superolateral aspect of the spermatic cord as it enters the deep inguinal ring. Then it was carefully and gently separated from the cord structures by elevating the cord-sac bundle and then delicately stripping the areolar tissue downward until a window was found between the sac and the cord structures.

Once the sac was separated cephalad, retraction of the sac from its apex typically was reduced. Cord lipomas were visualized during these maneuvers. They were located usually lateral to the cord and course toward the deep ring. Cord lipomas should be reduced cephalad and laterally. If the sac cannot be reduced back into the peritoneal cavity, it should be ligated proximally and left open to drain distally so as to prevent hydrocele formation. Care must be taken to avoid injury to any intra-abdominal sac contents or sliding component.

Placement of Mesh

Once the required dissection was achieved, the mesh was folded and introduced under direct vision, then dragged as far laterally as possible toward the ASIS. Next, the mesh was flattened out across the myopectineal orifice and draped over the cord structures. A single tack was placed at the pubic tubercle; this serves as a fixation point to facilitate arrangement of the mesh in the preperitoneal space.

The mesh was maneuvered so that its upper border lies above a line from the pubic symphysis to the ASIS. It was essential that each firing of the tacker beyond the inferior epigastric artery-vein complex be above a line from the pubic symphysis to the ASIS. This ensures that no tacks are placed in proximity to nerve structures or iliac vessels (the triangle of pain and triangle of doom). Correct placement can be further verified by carefully palpating the tacker head through the abdominal wall and comparing its relation to this line before each firing. No more than one or two tacks are needed in this hazardous location.

If the patient has bilateral pathology, the surgical team's attention is now turned to the contralateral side.

Closure

12 mm port fascia was closed using No-1 vicryl. Skin approximation was performed using 3-0 nylon.

Post-operative care

Fluids were restricted for 4 hours after surgery and start patient on clear fluids followed by liquid diet and later soft diet on the same day or the morning after. Patients are advised regarding early mobilization. Drains were removed (in case of umbilical hernias) before discharge. Analgesics were used in the first 3-5 days routinely. IV medications were switched to oral once soft diet was started. Patients were discharged within 48–72 hr of the procedure.

Results

In this out of 24 subjects, 21 were males and 3 were females. The average age of the patients was found to be 44.96 years.

Out of 24 hernia cases, 6 cases were Paraumbilical Hernia and the remaining 18 cases were inguinal hernia. Among the inguinal hernia cases, 5 were bilateral, 6 were left inguinal hernia, 6 were right inguinal hernia and the remaining 1 case was incisional hernia.

Regarding duration of surgery, in Paraumbilical Hernia it was 2.83 hours and in inguinal hernia it was 1.2 hours. Thus, in inguinal hernia the average time was comparatively lower as that of the Paraumbilical hernia.

The average pain score, based on visual analogue scale (VAS) at 24 and 48 hours in Paraumbilical hernia was 3.16 and 1.66 respectively. Meanwhile VAS score in inguinal hernia was 1.38 and 1.11 respectively. Thus pain score was lower in inguinal hernia as that of the Paraumbilical hernia patients.

Further, regarding mesh size, out of 6 cases in Paraumbilical hernia, 2 cases were placed with 30 x 30 cms mesh and the remaining 4 cases were placed with 15 x 15 cms mesh. Meanwhile, the mesh size for all the inguinal hernia cases were 10 x 15 cms.

The mean average time for hospital stay in Paraumbilical hernia and inguinal hernia were 2.16 and 2 days respectively. The results were shown in Table 1.

Discussion

In the current surgical practice, hernia surgeons are faced with so many different options to repair ventral hernia-from open ones with different mesh positions to various minimally invasive techniques. Most of them were developed in the last decade, and sufficient evidence is lacking (Vorst *et al*., 2015) [8]. Variety of techniques and levels of mesh positioning make decision-making process in ventral hernia surgery difficult. Wide range of techniques with different mesh locations are available such as subcutaneous onlay approach (SCOLA), endoscopic mini/less open sublay operation (EMILOS), robotic transabdominal preperitoneal ventral hernia repair (rTAPP), retromuscular approach eTEP/eRS and IPOM procedure (Luque *et al*.,2015; Schwarz *et al*., 2017; Orthopoulos and Kudsi, 2017) [9, 10, 11].

eTEP approach combines the advantages of the sublay position of the mesh and all benefits from the minimal invasiveness of the procedure. Avoiding foreign bodies in the abdominal cavity would lead to less related complications (Iqbal *et al*., 2007) [12]. In our study, the mean Median length of stay was 2 days, without readmissions and no postoperative complications which is comparable to previous studies (Belyansky *et al*., 2018) [13]. In our study the pain score was very low which might be due to the lack of fixation in eTEP procedure. We report mean operative time of 2 hours in both the cases of hernia, which is line with the previous reports (Penchev *et al*., 2019) [14]. A multicenter report of Belyansky *et al*. also reports an operative time of 218.9 min, including 41 cases with release of transversus abdominis (Belyansky *et al*., 2018) [13]. The greatest disadvantages that we know so far in eTEP procedure are prolonged operative time even in the expert hands in large volume hernia center and technical difficulties during the operation. Also the learning curve for laparoscopic eTEP approach may be steep, requiring advanced laparoscopic skills

Table 1: Operative and perioperative data in e-TEP cases

Description & Analysis	Numbers
Total Number of Cases Studied	24
Number of Male	21
Number of Females	3
Average Age of Patients (in years)	39.66 (Paraumbilical Hernia) 52.94(Inguinal hernia)
Total No. of PUH Cases:	6
Total No. of Inguinal hernia Cases:	18
Avg duration of surgery (Hrs)-(PUH)	2.833
Avg duration of surgery (Hrs)-(Inguinal hernia)	1.2
Average Score of Pain on a scale of 1 - 10 with 10 being highest (VAS)- PUH	3.16 (24hrs) 1.66(48hrs)
Average Score of Pain on a scale of 1 - 10 with 10 being highest (VAS)-Inguinal Hernia	1.38(24hrs) 1.11(48hrs)
Defect Size in cm : for PUH	2x2, 5x4,6x7, 3x3, 2x2& 3x2
Procedure followed for PUH Cases was	e-TEP for 6/6 case
Mesh Size for 2/6 PUH cases was	30x30 cms
Mesh Size for 4/6 PUH cases was	15x15 cms
Mesh Size for Inguinal hernia cases	10x15 cms
Mean duration of stay in the hospital (Paraumbilical hernia)	2.166
Mean duration of stay in the hospital (Inguinal Hernia)	2

Conclusion

Implementation of new techniques can lead to case selection or learning curve effect on the sample results. The design of the study is retrospective. Strong evidence and randomized control trail are needed to prove the potential benefits of the method

References

1. LeBlanc KA, Booth WV. Laparoscopic repair of incisional abdominal hernias using expanded polytetrafluoroethylene: preliminary findings. Surg Laparosc Endosc. 1993; 3:39-41.
2. Wake BL, McCormack K, Fraser C *et al*. Transabdominal preperitoneal (TAPP) vs totally extraperitoneal (TEP) laparoscopic techniques for inguinal hernia repair. Cochrane Database Syst Rev, 2005. DOI:10.1089/lap.2008.0212
3. Leibl BJ, Jager C, Kraft B *et al*. Laparoscopic hernia repair TAPP or/and TEP? Langenbecks Arch Surg. 2005; 390:77-82.
4. Prasad P, Tantia O, Patle NM. Laparoscopic ventral hernia repair: a comparative study of transabdominal preperitoneal versus intraperitoneal onlay mesh repair. J Laparoendosc Adv Surg Tech A. 2011; 21(6):477-483.
5. Belyansky I, Zahiri HR, Park A. Laparoscopic transversus abdominis release, a novel minimally invasive approach to complex abdominal wall reconstruction. Surg Innovation. 2016; 23(2):134-141.
6. Daes J. The enhanced view–totally extraperitoneal technique for repair of inguinal hernia. Surg Endosc. 2012; 26(4):1187-1189.
7. Daes J. The extended-view totally extraperitoneal e-TEP technique for inguinal hernia repair. In: Novitsky YW (ed) Hernia surgery, current principles. Springer, NewYork, 2016, pp. 467-472.
8. Vorst A, Kaoutzanis C, Carbonell A, Franz M. Evolution and advances in laparoscopic ventral and incisional hernia repair. World J Gastrointest Surg. 2015; 27(7):293-305.
9. Luque J, Luque A, Valdivia J, Gra´u J, Menchero J, Moreno J, Jurado J. Totally endoscopic surgery on diastasis recti associated with midline hernias. The advantages of a minimally invasive approach. Prospective cohort study. Hernia. 2015; 19(3):493-501.
10. Schwarz J, Reinpold W, Bittner R. Endoscopic mini/less open sublay technique (EMILOS)-a new technique for ventral hernia repair. Langenbecks Arch Surg. 2017; 402(1):173-180.
11. Orthopoulos G, Kudsi O. Feasibility of robotic-assisted transabdominal preperitoneal ventral hernia repair. J Laparoendosc Adv Surg Tech. 2017; 28(4):434-438.
12. Iqbal C, Pham T, Joseph A, Mai J, Thompson G, Sarr M. Long-term outcomes of 254 complex incisional hernia repairs using the modified Rives-Stoppa technique. World J Surg. 2007; 31(12):2398-2404.
13. Belyansky I, Daes J, Radu V, Balasubramanian R, Zahiri H, Weltz A, Sibia U, Park A. A novel approach using the enhanced-view totally extraperitoneal (eTEP) technique for laparoscopic retromuscular hernia repair. Surg Endosc. 2018; 32(3):1525-1532.
14. Penchev D, Kotashev G2, Mutafchiyski V. Endoscopic enhanced-view totally extraperitoneal retromuscular approach for ventral hernia repair. Surg Endosc, 2019.