



International Journal of Surgery Science

E-ISSN: 2616-3470
P-ISSN: 2616-3462
© Surgery Science
www.surgeryscience.com
2020; 4(2): 27-31
Received: 22-02-2020
Accepted: 24-03-2020

Dr. Quazi Mohammed Azhar Md Aslam

Assistant Professor, Department of
Plastic Surgery Grant Government
Medical College, Mumbai,
Maharashtra, India

Dr. Khan Afroz Shahana

Assistant Professor, Department of
Anesthesiology, Grant Government
Medical College, Mumbai,
Maharashtra, India

Assessment of quality of life after arch preserving segmental mandibulectomy in patients reconstructed with PMMC or free fibula flap

Dr. Quazi Mohammed Azhar Md Aslam and Dr. Khan Afroz Shahana

DOI: <https://doi.org/10.33545/surgery.2020.v4.i2a.393>

Abstract

Aims: The aim of our study was to evaluate by questionnaire the HRQOL who have had mandibular resection of oral cancers and reconstruction with either free fibular flap or PMMC.

Settings and Design: Retrospective study

Methods and Material: The study was done in a tertiary care hospital over a period of 2 years. Adult and consenting patients who had undergone lateral segmental mandibulectomy with successful reconstruction were included.

Statistical analysis: Information from the data was correlated against the socio-demographic and treatment variables using the Mann Whitney U test. Data were recorded and then analysed & $P < 0.05$ were accepted as significant.

Results: Of total 60 patients, Quality of life UW-QOL scores for 12 disease-specific domains show no significant differences between the average scores of the two groups for the shoulder, taste, saliva, mood and anxiety domains. However, there were significant differences between the Free fibula graft and PMMC and groups for the pain, appearance, activity, recreation, swallowing, chewing and speech domains.

Conclusions: The composite QOL score and global QOL were more in patients with free fibula graft compared to patients who received PMMC implying better overall results with free fibula graft. Therefore, we emphasize that free fibula flap remains the preferred option for reconstruction of segmental defects in patients undergoing arch preserving mandibulectomy.

Keywords: Free fibula, PMMC, arch preserving mandibulectomy, health related quality of life

Introduction

Oral cavity cancers pose a major problem in India, where it ranks third after malignancy of cervix and stomach [1]. Definitive management of which consist of adequate surgical resection with reconstruction by microvascular flaps. Segmental mandibulectomy is done in cases of alveolar lesions, the floor of the mouth, buccal mucosa or tongue lesions, which approximate the mandibular bone. To optimize functional and cosmetic outcomes, resection is followed by reconstruction.

Ariyan had described the pectoralis major myocutaneous flap (PMMC) for the first time in 1979 (Hsing). Because of a simpler technique and proximity to the head and neck area, PMMC flap has become the most important reconstruction method (Hsing). However, for better functional and aesthetic results vascularized free flaps have been performed more frequently [2]. If parts of the mandible are present on both sides of the defect, it should be reconstructed with the bone. For posterior segmental mandibulectomy, soft tissue flap PMMC or Anterolateral Thigh flap (ALT) can be considered. Free fibula flap is considered to be the Gold standard technique for the reconstruction of the mandible [3].

Segmental mandibulectomy causes loss of structural and functional integrity of the head and neck region causing problems of oromandibular function which in turn leads to various psychosocial issues because of impairment of day to day social interactions and emotional expressions [4, 5]. Oral cancer surgeries have a definite impact on the quality of life (QoL) which has been defined as the perceived discrepancy between the actual status and ideal standard of the patients [6]. With the advancements of microvascular surgeries, the main goal in the management of such cases is to treat the patient while preserving a satisfactory QoL [7]. Successful reconstruction has long been seen as the ultimate survival of the free flaps rather patient's QoL.

Corresponding Author:

Dr. Quazi Mohammed Azhar Md Aslam

Assistant Professor, Department of
Plastic Surgery Grant Government
Medical College, Mumbai,
Maharashtra, India

Now the health-related quality of life (HRQOL) has become important outcome measures for the patients undergoing treatment.

Very less literature is available with regard to the patient's HRQOL after arch preserving lateral segmental mandibular resections. Hence, the aim of our study was to evaluate by questionnaire the HRQOL who have had mandibular resection of oral cancers and reconstruction with either free fibular flap or PMMC.

Methods

In this retrospective study we analyzed 60 patients' chart records who have undergone arch preserving mandibulectomy and reconstruction with either free fibula flap or PMMC in our tertiary care center from 2014 to 2016. The selection of free or pedicled flap was not randomized, it was dependent upon the availability of plastic surgeon or decision by oncosurgery team. For the purpose of our study patients with tumour arising from an upper jaw, oropharynx, patient who had had any treatment of any modality and disease recurrence and patients in whom central segment mandibulectomy or Posterior segmental mandibulectomy required were excluded. Inclusion criteria were patients requiring lateral segmental mandibular resections, flaps survived completely, age less than 65 years, no previous or synchronous malignancies, no cognitive impairment, at least 12 months after reconstruction.

Questionnaires and data collection: In our study, we used the University of Washington Quality of Life version 4 (UW-QOL-4) questionnaire. The questionnaire was administered to the patient at the end of 12 month postop who were regularly followed up. It is an important outcome parameter providing a broad measure of QOL for patients with head and neck cancer with good acceptability, practicality, validity, reliability, and responsiveness (5, 6). The questionnaire consists of 15 domains: in which 12 are disease-specific items (pain, appearance, activity, recreation, swallowing, chewing, speech, shoulder, taste, saliva, mood, and anxiety), and 3 are global questions. 12 questions have 3-6 response options that are scored on a scale ranging from 0 (worst) to 100 (best). Besides the 15 questions, patients were asked to choose no more than 3 of the 12 disease-specific domains that had been the most important to them in the preceding 7 days. The scoring of the individual domain is according to the UW-QOL guidelines. The standard UW-QOL is available as an Indian version and has been validated for an Indian population [8].

Statistical analysis: The data collated was entered into a worksheet (Excel 05; Microsoft Corp, Washington) and mean (SD - standard deviations) were computed. Information from the scale was correlated against the socio-demographic and treatment variables such as age, sex, site, tumor stage, radiotherapy and comorbidities (diabetes mellitus) using the Mann Whitney test. Data were recorded and then analysed with the help of the Statistical Package for the Social Sciences (SPSS version 20.0, SPSS Inc., IBM). Probabilities of less than 0.05 were accepted as significant.

Results

Of total 60 patients with oral cancer who underwent arch preserving mandibulectomy with immediate reconstruction with either free fibula flap or PMMC were included in the study, all patients completed the questionnaire when back to the hospital 12 months postoperatively for follow up. Of 60 patients who

completed questionnaires, there were 52 men and 8 women with the mean age of 57; the number of patients with Ca buccal mucosa (N=44, 73.33%) was more compared to Ca alveolus (N=16, 26.66%) (Table 1). 11 patients of 60 (18.33%) were classified as T1-T2, while 49 (81.66%) were classified as T3-T4. The postoperative follow-up period was 12 months. There was no significant statistical difference between the PMMF and Free fibula graft groups in age ($p = 0.57$), primary tumor site ($p = 0.751$), T-stage ($p = 0.750$) and perioperative adjuvant radiotherapy treatment ($p = 0.203$) and associated comorbidity like diabetes mellitus. However, only two female patients received PMMC out of 30 patients. Likewise, the number of female patients receiving free fibula graft reconstruction was six.

Quality of life UW-QOL: The scores for 12 disease-specific domains and the importance of each domain are shown in table 2. There were no significant differences between the average scores of the two groups for the shoulder (46.66 ± 28.92 vs 32.0 ± 22.65), taste (39.33 ± 27.0 vs 39.66 ± 22.81), saliva (55.33 ± 35.65 vs 37.66 ± 21.76), mood (43.33 ± 28.56 vs 44.16 ± 28.37) and anxiety (58.00 ± 32.73 vs 42.33 ± 31.69) domains. However, there were significant differences between the Free fibula graft and PMMF and groups for the pain (70.833 ± 22.821 vs 33.33 ± 24.85), appearance (54.16 ± 27.91 vs 40.833 ± 22.24), activity (50.00 ± 29.36 vs 43.33 ± 21.7), recreation (44.16 ± 27.60 vs 32.5 ± 18.74), swallowing (52.66 ± 26.38 vs 35.66 ± 23.73), chewing (46.66 ± 26.04 vs 40.83 ± 32.48) and speech domains (50.33 ± 25.11 vs 45.0 ± 27.38). When patients were asked to select their three most important domains, the speech was considered the most important over the past 7 days, followed by chewing and swallowing. Pain domains were considered the least important to patients.

Discussion

The mandible has a major role in airway protection and support of the tongue, lower dentition, and the muscles of the floor of the mouth permitting mastication, articulation, deglutition, and respiration [9].

Surgical resection leads to anatomical loss causing occlusal impairment and deviated mandible thus, have an influence on function and aesthetics. The free fibula flap as a source of vascularized bone in reconstructive surgery is in wide use¹⁰. While other free flaps are available, the fibula provides the maximum length and bone stock to achieve a satisfactory reconstruction of the lower jaw. In low socioeconomic situations or setups which lack adequate infrastructure, PMMC flap is predominately used.

Reconstruction is often challenging, as treatments have a significant impact on the QOL and daily functioning of cancer patients. These patients often face speech, eating and respiration impairments in combination with facial disfigurement. Therefore, along with survival as a key measure of success in the treatment of patients with oral cancer, health-related QOL has been increasingly recognized as an important tool to be considered in the assessment of treatment outcomes [11]. It provides information about the perceptions of patients.

We chose UW-QOL questionnaire because it is short and easy for patients to complete themselves, thus making it ideal in a busy outpatient setting.

The age in the present study ranged from 37 to 78 years and the mean age was 57. Both extremes had good functions. There was no significant difference in age. In our study, a higher proportion of female patients underwent free fibula surgery in view of cosmetic concern (a deformity of the breast). The 3 most

important domains we observed in our study were similar to those reported by Rogers *et al.* [12] i.e. speech, chewing, and swallowing was more important than the other UW-QoL domains. Approximately 90% of our patients were dissatisfied with chewing.

There is no doubt that the mean score for the chewing domain was only 42.21, similar to that reported by Hsing *et al.* [2]. As for the swallowing domains, more than 50% of our patients believed their function of swallowing was slightly affected. The possible reason was that the pharyngeal tissues were rarely invaded.

Zhang X. *et al.* [13]. showed the lower quality of speech with FF (57.5±20.1 vs 76.1±13.3, $p<0.05$) with a mean follow-up of 5.9 years. Hsing *et al.* showed a better quality of speech with FF compared to PMMF (66.7±27.2 vs 44.7± 35.0, $p<0.05$) from data of patients operated 2 to > 10 years earlier. In our study, the scores of domains like pain, appearance, activity, recreation, speech, swallowing, chewing and speech were higher in the free fibula group than the PMMC group. We also found that domains like shoulder, taste, saliva, mood, and anxiety when compared between the free fibula and PMMC group of patients, were similar. Anxiety, saliva and appearance domains were with high average scores in the free fibula group whereas, in PMMC group pain, speech and mood domains were with high average scores. Similarly, the domains with the lowest scores in the two groups were different. In the free fibula group; pain, taste and mood domains were with lowest scores. In the PMMC group; shoulder, recreation, and swallowing domains were at lower rates. (Table 2)

In addition, looking at studies using the UW-QOL, including 14 items, was used by three studies [2, 14, 15] to measure the quality of life after surgical reconstruction with either FF or PMMF. Both

groups scored similarly on global quality of life, pain, swallowing, chewing, speech, activity, recreation, taste, saliva, anxiety and composite score.

We found that patients who were reconstructed with PMMC had better pain scores compared with those received free fibula graft. Rogers *et al.* in their study about patients treated by primary surgery for oral ca also found that global quality of life was scored well to excellent by 58.1% of participants [12]. Similarly, the global quality of life scores in our study came around 56.11. There was a significant difference between the two groups when the global quality of life was compared between free fibula (64.55±11.51) and PMMC (47.67±12.84) group P value <0.0001. We also found that patients who underwent free fibula graft reconstruction rated UW-QOL composite scale higher (54.08±101.012) compared to the PMMC group (53.60±98.93). Rogers *et al.* [12] in their study on importance-rating using the UW-QOL questionnaire in patients who underwent surgical procedures for head and neck cancer tend to rate speech, chewing and swallowing as the most important domains compared to other domains. Our study also found the same results. This means speech, chewing and, swallowing are the domains significantly affected by the reconstructive surgery.

In summary, the UW-QOL scale is a simple scale that can be used effectively in oral and oropharynx cancer patients. Questionnaires provide a structured snapshot of the patient's point of view. They facilitate multidisciplinary team working with the recognition of poor outcome groups, provide better information for the patient and their care givers, and allow the opportunity to identify problem areas and target intervention [4]. It arms the clinician with useful information and can contribute to decision making based on patient feedback [11].

Table 1: Patients Profile

Age								
	Free Fibula	PMMC	Total	Mean	SD	Mean	SD	P value
<45	5 (16.66)	7(23.33)	12	42	2.64	41.2	2.58	0.5684
>45	25 (83.33)	23 (76.66)	48	62.13	9.33	60.8	9.6	0.5892

Table 2: Patients Profile: Analyses of Ca oral cavity patients who underwent Free fibula or PMMC Flap

Variables	Free Fibula	PMMC	Total	P value	Result
Male	24 (80)	28 (93.33)	52	0.2542	Insig
Female	6 (20)	2 (6.66)	8		
Primary Site					
Buccal Mucosa	23 (76.66)	21 (70)	44	0.7518	Insig
Alveolus	7 (23.33)	9 (30)	16		
T stage					
T1-T2	5 (16.66)	6 (20)	11	0.7501	Insig
T3-T4	25 (83.33)	24 (80)	49		
Adjuvant Radiotherapy					
NO	3(10)	2(6.66)	5	0.2033	Insig
YES	27(90)	28(93.33)	55		
Diabetes mellitus					
NO	23(76.66)	21(70)	44	0.5598	Insig
YES	7(23.33)	9(30)	16		

Table 3: Quality of Life score of oral cavity pateints underwent free fibula or PMMC Flap

Domains	Mean score ± Standard Deviation (mean±SD)		P value	Result
	Free Fibula (n=30)	PMMC (n=30)		
Pain	33.33±24.85	70.833±22.821	0.0001	Sig
Appearance	54.16±27.91	40.833±22.24	0.036	Sig
Activity	50.00±29.36	43.33±21.7	0.034	Sig
Recreation	44.16±27.60	32.5±18.74	0.095	Sig
Swallowing	52.66±26.38	35.66±23.73	0.008	Sig
Chewing	46.66±26.04	40.83±32.48	0.048	Sig
Speech	50.33±25.11	45.0±27.38	0.04	Sig
Shoulder	46.66±28.92	32.0±22.65	0.062	insig
Taste	39.33±27.0	39.66±22.81	0.93	insig
Saliva	55.33±35.65	37.66±21.76	0.092	insig
Mood	43.33±28.56	44.16±28.37	0.91	insig
Anxiety	58.00±32.73	42.33±31.69	0.08	insig
Global QOL	64.55±11.51	47.67±12.84	0.0001	Sig
UW-QOL composite scale	54.08±101.012	53.60±98.93	0.05	Sig

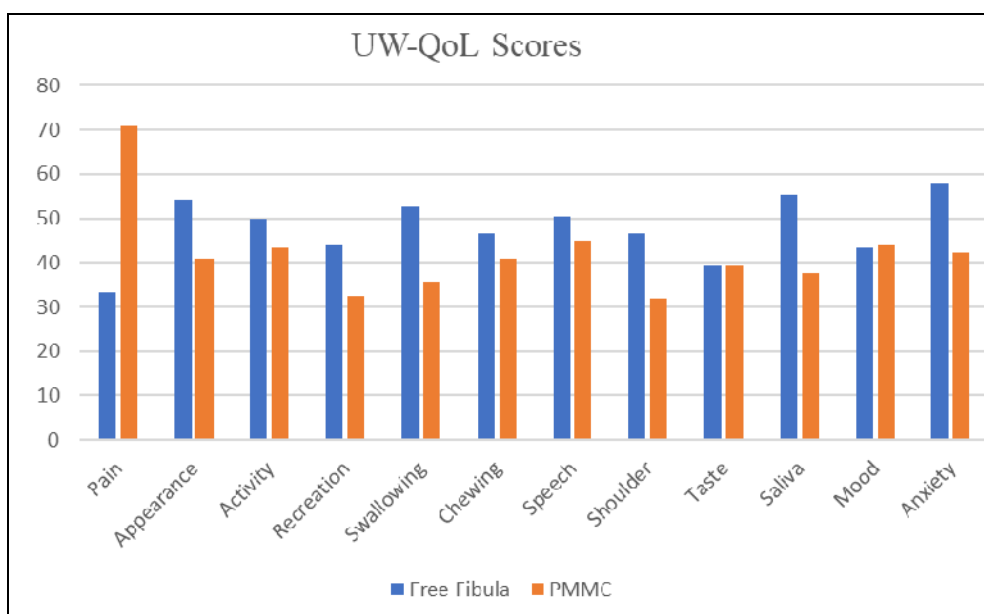


Fig 1: UW-QOL scores in PMMC and free Fibula flap groups (mean). Scores in PMMC group and free flap group differed significantly ($p<0.05$) in pain, appearance, activity, recreation, swallowing, chewing and speech.

Conclusion

In summary, though the two groups had comparable morbidity as some domains such as shoulder, taste, saliva, mood, and anxiety were similar. The composite QOL score and global QOL score as assessed using the UW-QOL scale (version 4) were more in patients with free fibula graft compared to patients who received PMMC implying better overall results with free fibula graft. Therefore, we emphasize that free fibula flap remains the preferred option for reconstruction of segmental defects in patients undergoing arch preserving mandibulectomy.

References

1. Wong YK, T Sai WC, Lin JC *et al.* Socio-demographic factors in the prognosis of oral cancer patients. *Oral oncol* 2006, 998-1007.
2. Hsing CY, Wong YK, Wang CP, Wang CC, Jiang RS, Chen FJ *et al.* Comparison between free flap and pectoralis major pedicled flap for reconstruction in oral cavity cancer patients-a quality of lifeanalysis. *OralOncol* 2011;4 7(6):522-527.
3. Delacure M. Reconstruction of mandible. *Indian J Plast Surg.* 2007; 40:28-34.
4. Evans PR, Montgomery PQ, Gullane PJ. Principles and practice of head and neck oncology. UK: Martin Dunitz, 2003.
5. Jones E, Lund VJ, Howard DJ, Greenberg MP, McCarthy M. Quality of life of patients treated surgically for head and neck cancer. *J Laryngol Otol.* 1992; 106:238-42.
6. Morton RP. Evaluation of quality of life assessment in head and neck cancer. *J Laryngol Otol.* 1995; 109:1029-35.
7. Urken ML, Buchbinder D, Weinberg H, Vickery C, Sheiner A, Parker R *et al.* Functional evaluation following microvascular oromandibular reconstruction of the oral cancer patient: a comparative study of reconstructed and nonreconstructed patients. *Laryngoscope.* 1991; 101:935-50.
8. D'cruz AK, Yueh B, Das AK, Mcdowell JA, Chaukar DA, Ernest AW. Validation of the University of Washington quality of life questionnaires for head and neck cancer patients in India. *Indian J Cancer.* 2007; 44:147-54.

9. Zhu *et al.* Measures of health-related quality of life and socio-cultural aspects in young patients who after mandible primary reconstruction with free fibula flap. *World journal of surgical oncology.* 2013; 11:250.
10. Coletti DP, Ord R, Liu X. Mandibular reconstruction and second generation locking reconstruction plates: outcome of 110 patients. *Int J Oral Maxillofac Surg* 2009; 38:960-963.
11. Xiao Y, Zhu J, Cai X, Wang J, Liu F, Wang H. Comparison between anterolateral thigh perforator free flaps and pectoralis major pedicled flap for reconstruction in oral cancer patients-A quality of life analysis. *Med Oral Patol Oral Cir Bucal.* 2013; 18(6):e856-61.
12. Rogers SN, Laher SH, Overend L, Lowe D. Importance-rating using the University of Washington Quality of Life questionnaire in patients treated by primary surgery for oral and oro-pharyngeal cancer. *J craniomaxillo fac Surg.* 2002; 30:125-32.
13. Xu Zhang, Meng-Jie Li, Qi-Gen Fang, Zhen-Ning Li, Wen-Lu Li, Chang-Fu Sun. Free Fibula Flap: Assessment of Quality of Life of Patients With Head and Neck Cancer Who Have Had Defects Reconstructed. *J Craniofac Surg.* 2013; 24:6.
14. Li W, Zhang P, Li R, Liu Y, Kan Q. Radial free forearm flap versus pectoralis major pedicled flap for reconstruction in patients with tongue cancer: assessment of quality of life. *Med Oral Patol Oral Cir Bucal.* 2016; 21(6):e737-e42.
15. Zhang X, Li MJ, Fang QG, Sun CF. A comparison between the pectoralis major myocutaneous flap and the free anterolateral thigh perforator flap for reconstruction in head and neck cancer patients: assessment of the quality of life. *J Craniofac Surg.* 2014; 25(3):868-71.