



E-ISSN: 2616-3470

P-ISSN: 2616-3462

© Surgery Science

www.surgeryscience.com

2020; 4(2): 35-36

Received: 28-02-2020

Accepted: 30-03-2020

Diop A

General Surgery Department,
General Hospital Idrissa Pouye,
Senegal

KA I

General Surgery Department,
General Hospital Idrissa Pouye,
Senegal

Faye AC

General Surgery Department,
General Hospital Idrissa Pouye,
Senegal

Hitier M

Associate Professor, Department of
General Surgery, PKDAS Institute
of Medical Sciences, Kerala, India

NOC PM

General Surgery Department, Pau
Hospital Center, France

Diop PS

General Surgery Department,
General Hospital Idrissa Pouye,
Senegal

Couderc P

General Surgery Department, Pau
Hospital Center, France

Fall B

General Surgery Department,
General Hospital Idrissa Pouye,
Senegal

Corresponding Author:

Diop A

General Surgery Department,
General Hospital Idrissa Pouye,
Senegal

Acute cholangitis on a choledochal foreign body at a herbal tea drinker: About an observation

Diop A, KA I, Faye AC, Hitier M, NOC PM, Diop PS, Couderc P and Fall B

DOI: <https://doi.org/10.33545/surgery.2020.v4.i2a.395>

Abstract

Foreign bodies from the main bile duct are rare. We report the case of a 61-year-old patient who presented an acute cholangitis on a choledochal foreign body after sphincterotomy. Under laparoscopy, we did a cholecystectomy and a choledocotomy with choledocscopy which allowed us an extraction of three choledocious lithiasis. Operative sequences were simple under cover of an adapted antibiotic therapy.

Keywords: Choledocal foreign body, choledocotomy, choledocscopy

Introduction

Foreign bodies from the main bile duct are rare. In the absence of previous biliary surgery or bilio-digestive fistula, the passage of these foreign bodies into the bile ducts is often due to entero-biliary reflux from the duodenum. We report the case of a 61-year-old patient who presented an acute cholangitis on a choledochal foreign body after sphincterotomy.

Clinical case

It was a 61-year-old patient who benefited an ERCP + sphincterotomy in 2014. The patient subsequently presented several minimally angiocholitis episodes treated medically. The admission examination had found an afebrile patient at 37 °C with conjunctival jaundice. The abdominal examination found pain in the right hypochondrium at the palpation. Biology had shown a CRP elevated to 51, a leukocytosis predominantly neutrophilic, hepatic cytolysis at 5 N, a predominantly conjugated hyperbilirubinemia, a cholestasis at 3 N, prothrombin level at 86% and normal lipaemia. Biliary MRI found an oblong-shaped lithiasis enclosed at the level of the common bile duct, measured at 30 mm in length x 9 mm in transverse diameter with the presence of dilation of the overlying bile duct measured at 14 mm in diameter (Figures 1 and 2). Under laparoscopy, we did a cholecystectomy and a choledocotomy with choledocscopy. The dormia probe allowed an extraction of three choledocious lithiasis, one 4 cm high formed around a twig of thyme (Figure 3 and 4) which is probably brought up by the path of sphincterotomy and remained in place for several months. Operative sequences were simple under cover of an adapted antibiotic therapy. Cholangiography control had proved the emptiness of the bile duct without fistula.

Discussion

Foreign bodies of the main bile duct are for the most part residual objects of previous biliary intervention ^[1]. They are often revealed by complications following the formation of stones (repeated cholangitis) ^[2]. Biliary MRI is the reference exam for making the diagnosis ^[3]. Extraction can be performed by choledocscopy ^[4]. In case of failure, it becomes the prerogative of open surgery ^[5].

Conclusion

Foreign bodies of the main bile duct are extremely rare. In our clinical case, the antecedent of sphincterotomy produced a biliary reflux. The natural form of the alimentary foreign body has favored its anchorage in the choledochal wall with long-term lithogenic process.

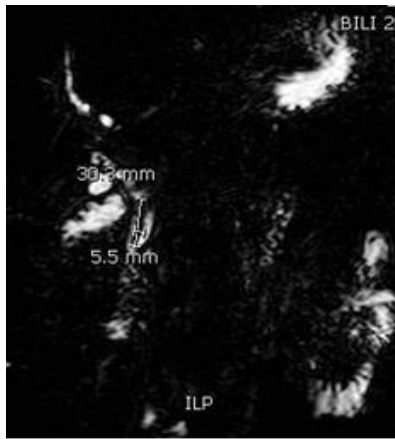


Fig 1: Biliary MRI with an oblong-shaped lithiasis

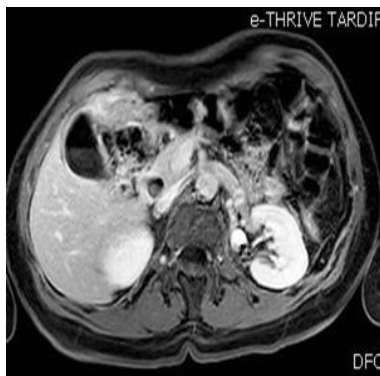

Fig 2: Biliary MRI with dilation of the overlying bile duct

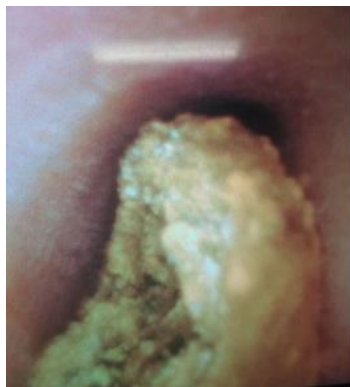

Fig 3: Choledochous lithiasis



Fig 4: Sprig of thyme (after extraction)

References

1. Meltzer SJ. Recurrent pancreatitis caused by vegetable matter obstruction. *Am J Gastroenterol* 1986; 81:1091-2.
2. Perney P. Pancréatite aiguë à corps étrangers. 2 observations. *Presse Med* 1993; 22:1397-404.
3. Kim YH, Kim YJ, Park WK, Lee SK, Kwon JH, Woo SK. Fish bone as a nidus for stone formation in the common bile duct. *Korean J Radiol.* 2004; 5:210-3.
4. Uomo G. Necrotizing acute pancreatitis due to a common bile duct foreign body. *Am J Gastroenterol* 1994; 89:1109-10.
5. Prochazka V, Krausova D, Kod'ousek R, Zamecnikova P. Foreign material as a cause of choledocholithiasis. *Endoscopy.* 1999; 31:383-5.