



E-ISSN: 2616-3470

P-ISSN: 2616-3462

© Surgery Science

www.surgeryscience.com

2020; 4(2): 91-98

Received: 14-02-2020

Accepted: 16-03-2020

Dr. Hima Bindu Gurram

Assistant Professor, Dept of
Pathology, Katuri Medical College
& Hospital, Guntur, Andhra
Pradesh, India.

Histopathological study of vertebral and paravertebral Lesions at a tertiary care hospital

Dr. Hima Bindu Gurram

DOI: <https://doi.org/10.33545/surgery.2020.v4.i2b.402>

Abstract

Aim & Objectives: The aim is to study the various histopathological lesions involving vertebrae and paravertebral region and also diagnose number of malignancies involving vertebral regions along with radiological correlation.

Methodology: It was a cross sectional study and conducted at the Department of Pathology, Katuri Medical College from during the year 2017 to 2019.

Results: Among 200 cases, 64 cases constitute the non-neoplastic lesions. In the present study, Majority of the lesions affected the lumbar vertebrae (48.5%), followed by thoracic (38%), cervical (7.5%), sacral vertebrae (3%) and paravertebral region (3.0%). In the present study there are 75 cases of neoplastic lesions that involved the vertebrae. Out of these 28 (14%) cases are benign neoplastic lesions and 47 (23.5%) are malignant neoplasms. The common benign lesion noted was schwannoma in 12 (41.3%) cases, 11 (37.9%) cases of meningiomas, 03(10.3%) cases of hemangiomas 01(2.4%) case of neurofibroma, 01 (3.4%) case of ganglioneuroma. Of the 15 primary malignant lesions, radiological diagnosis of malignancy was made in 10 cases and in the remaining 5 cases an opinion of suspicious malignancy was given. On histopathological examination these 5 cases also turned out to be the seat of primary malignancy.

Conclusion: Fine-needle aspiration biopsy of radiologically suspected vertebral and paravertebral disc lesions in patients with a history of a known malignancy is useful to confirm the presence of metastases. Thorough assessment of the specimen adequacy, and correlating with the clinical and radiologic findings, a definitive diagnosis can be made in most cases.

Keywords: Neoplastic lesions of vertebral bodies, Paraspinal lesions, metastatic bone tumors

Introduction

FNAC / FNAB has progressed during recent years to gain the popularity and has documented encouraging results to the extent of declaring cytodiagnosis, as an alternative to frozen sections, conventional needle biopsies and excision biopsies.

Initially in 1920's needles were used to obtain cells and tissue fragments to isolate micro-organisms or to diagnose malignancy. This (FNAC) procedure remained as an "oasis" since then and is a simple, inexpensive procedure. It remains the first choice for the initial investigation and diagnosis of both superficial and deep lesions [1-5].

It is important in the diagnosis of benign or malignant neoplastic conditions. It is also useful in the diagnosis of inflammatory, infectious and degenerative conditions. It is used as alternative or compliment to frozen section examination for intraoperative diagnosis.

The scope of FNAC is not just limited to easily accessible superficial lesions but has extended widely with more aspirations of deep seated mass lesions. Imaging investigations provide accurate delineation and depiction of size, site and extent of lesions but it is not possible to provide an etiological diagnosis in all cases. Therefore, final decision regarding patient management depends on histological diagnosis and so biopsy is almost always necessary before therapy can begin. This technique has particular importance in vertebral lesions where open biopsies require extensive procedure and also exposing the patient to great risks. 6-10

The use of needle aspiration biopsy in diagnosing vertebral lesions was introduced by Coley *et al*¹ and the frequency and popularity of needle aspiration biopsy was increased due to efforts of De Santose *et al*^[2]. The present study includes computed tomography (CT) guided biopsies and aspirations for studying vertebral and paravertebral lesions. This procedure provides image as well as tissue diagnosis in the same sitting without any trauma to intervening structures thereby reducing the subsequent complications encountered with blind procedures.

Corresponding Author:

Dr. Hima Bindu Gurram

Assistant Professor, Dept of
Pathology, Katuri Medical College
& Hospital, Guntur, Andhra
Pradesh, India.

Aims and objectives

This study was undertaken to assess

1. Histopathological Findings of various vertebral lesions
2. Histopathological and Radiological Correlation.
3. To diagnose the number of malignancies involving the vertebral lesions.

Materials and Methods

The technique for aspiration biopsy of a specific area is similar, regardless of the organ or the type of structure that is being evaluated. In case of FNAC of vertebrae and bony lesions the approach should follow the least invasive tissue and bony pathway.

Equipments

- A) For CT guidance: CT scanner machines.
- B) For aspiration:
 1. 10 cc disposable plastic syringes
 2. Sterile disposable lumbar puncture needle with a 45° bevel (20, 21 or 23 gauge) and having length three and half inches^[44].
 3. Glass slides and 0.4 mm thickness cover slips
 4. Coplin jar containing 95% ethyl alcohol as fixative.
 5. Skin marking pen
 6. Spirit and beta dine
 7. Sterile gauze pads
 8. Sterile gloves
 9. Sterile drapes

Pre-procedure

1. The related clinical history was obtained and clinical examination was performed with special attention towards the bony lesion
2. Brief explanation of the procedure to the patient was given
3. Written informed consent was taken

Procedure

1. First preliminary CT scans through the lesion were taken so as to obtain the shortest and easily accessible route into the lesion.
2. Distances were calculated, taking the most prominent nearest bony prominence as the reference landmark. Depth for insertion of the needle was calculated by drawing a line from the lesion up to the skin^[3, 4].




Fig 1: Fine cutting aspiration needles (FNA Needles), (A) Spinal needle, (B) Chiba needle aspirating cutting needles, (C) Crown, (D) Greene, (E) Franseen

Imaging modalities for needle guidance

Fluoroscopy, CT scan, nuclear medicine, ultrasound and MRI have been used for imaging guidance in vertebral biopsies. The lesion morphology, size and location often determine the type of imaging used during biopsy. CT guided needle biopsy have been proven effective for vertebral biopsy. CT represents the most commonly used imaging modalities for vertebral biopsy. CT is able to visualize both bone and soft tissues and delineates a safer path for needle placement by avoiding vital structures. Larger sclerotic or lytic lesions can be identified and biopsied by CT.

Results

Table 1: Depicting the overall distribution of lesions

| Non-neoplastic | Neoplastic lesions | | No Pathology | Total |
|----------------|--------------------|-----------|--------------|-------|
| | Benign | Malignant | | |
| 64 | 28 | 47 | 61 | 200 |

Total of 200 cases were identified affecting the vertebral and paravertebral regions. Out of them 61 cases did not show any specific pathology and these include cases showing only normal bone and its trabecular and fibrocartilage nous disc material. This may be attributed to non-inclusion of representative area of the lesion in the aspirated material. Non-neoplastic lesions involving the vertebral lesions comprise a total of 64 cases of which included inflammatory lesions, lipomeningomyelocele, keratinous cyst, meningomyelocele and dermoid cyst. There were 75 cases of neoplastic lesions out of which 28 were benign and 47 were malignant.

Table 2: Depicting Non neoplastic lesions

| Nature of lesion | Number of cases |
|---------------------------|-----------------|
| Non specific inflammation | 28 |
| Tuberculous infection | 32 |
| Keratinous cyst | 01 |
| Lipomeningomyelocele | 01 |
| Meningomyelocele | 01 |
| Dermoid Cyst | 01 |
| Total | 64 |

Among 200 cases, 64 cases constitute the non-neoplastic lesions affecting the vertebral and paravertebral regions. The most common non-neoplastic lesion is tuberculous infection constituting 32 cases, followed by non-specific inflammatory lesions comprising 28 cases. The other four cases included one case each of keratinous cyst, lipomeningomyelocele, meningomyelocele and dermoid cyst.

Table 3: Depicting the benign neoplastic lesions

| Type of benign neoplasm | Number of cases |
|-------------------------|-----------------|
| Schwannoma | 12 |
| Meningiomas | 11 |
| Ganglioneuroma | 01 |
| Neurofibroma | 01 |
| Hemangioma | 03 |
| Total | 28 |

Out of 200 cases affecting the vertebral and paravertebral regions, benign lesions constitute 28 cases. Among them the most common benign neoplastic lesion is schwannoma (12 cases), followed by meningioma (11 cases), hemangiomas (03 cases) and one case each of neurofibroma and ganglioneuroma.

Table 4: Depicting the malignant lesions

| Primary Malignant Tumours | No. of Cases | Total | Grand Total |
|---|--------------|-------|-------------|
| Myeloma | 05 | 15 | 47 |
| Ependymoma | 02 | | |
| Small round cell tumor | 03 | | |
| Epithelioid Angiosarcoma | 01 | | |
| Malignant Peripheral Nerve sheath tumor | 01 | | |
| Pacoima | 01 | | |
| Chordoma | 01 | | |
| Diffuse fibrillary astrocytoma | 01 | | |
| Secondary Deposits | | | |
| Adenocarcinoma | 20 | | |
| Squamous cell carcinoma | 11 | | |
| NHL | 01 | | |

Table 5: Depicting distribution of secondary deposits

| Type of secondary deposits | | Number of cases | Total |
|----------------------------|---------------------------|-----------------|-------|
| Adenocarcinoma | Well differentiated | 07 | 20 |
| | Moderately differentiated | 00 | |
| | Poorly differentiated | 13 | |
| Squamous cell carcinoma | Well differentiated | 07 | 11 |
| | Moderately differentiated | 01 | |
| | Poorly differentiated | 03 | |
| NHL | - | 01 | 01 |
| Total | | | 32 |

Out of the 200 cases, the malignant lesions constitute to 47 cases, of which 15 cases are the primary lesions which include

05 cases of multiple myeloma, 03 cases of small round cell tumor, 02 cases of ependymoma and each one case of epithelioid angiosarcoma, malignant peripheral nerve sheath tumor, PEComa, Chordoma and diffuse fibrillary astrocytoma.

There are 32 cases of Secondary deposits out of which adenocarcinomatous deposits are 20 cases, Squamous cell carcinoma are 11 cases and one case of Non-Hodgkin's lymphoma. Among the 20 adenocarcinomatous deposits 07 are well differentiated and 13 are poorly differentiated adenocarcinomatous secondary deposits. Among the 11 cases of Squamous cell carcinoma secondary deposits, 07 are well differentiated, 01 case of moderately differentiated and 03 cases are poorly differentiated Squamous cell carcinoma secondary deposits.

Maximum number of non neoplastic lesions (47 cases) occurred between 21 and 60 years of age, with 13 cases occurring in 21-30 years age group, 12 cases each in 31-40 years and 41-50 years age groups and 10 cases in 51-60 years age group. Benign neoplasms predominantly occurred in 41-50 years (8 cases), 31-40 (6 cases) and 21-30 (5 cases). Malignant lesions are most common between 31 and 60 years with 10 cases in 31-40 years age group, 14 cases each in 41-50 years and 51-60 years age groups.

Among the non-neoplastic lesions, the most common lesion is being Koch's spine which occurred in all ages from 10 years to elderly age (71- 80yrs). The next common non-neoplastic lesion is non- specific inflammation 26 out of 28 cases occurring between 21 and 70 years of age. Other non- neoplastic lesions include keratinous cyst, lipomeningomyelocele, meningomyelocele and dermoid cyst which occurred below 30 years of age.

Table 6: Age incidence in benign neoplastic lesions

| Type of benign neoplasm | 0-10 years | 11-20 years | 21-30 years | 31-40 years | 41-50 years | 51-60 years | 61-70 years | 71-80 years | Total |
|-------------------------|------------|-------------|-------------|-------------|-------------|-------------|-------------|-------------|-------|
| Schwannoma | - | 01 | 03 | 01 | 03 | 02 | - | 02 | 12 |
| Neurofibroma | - | - | - | 01 | - | - | - | - | 01 |
| Ganglioneuroma | - | - | - | 01 | - | - | - | - | 01 |
| Meningioma | - | - | 02 | 01 | 04 | 02 | 02 | - | 11 |
| Hemangioma | - | - | - | 02 | 01 | - | - | - | 03 |
| Total | 00 | 01 | 05 | 06 | 08 | 04 | 02 | 02 | 28 |

Among the 28 benign neoplastic lesions encountered in vertebral bodies and paravertebral regions, the most common is Schwannoma (12 cases) followed by meningioma (11 cases). Schwannoma occurred in patients from 11 to 80 years of age whereas Meningiomas affected individuals between 21 and 70

years of age. Out of three cases of hemangiomas encountered in the present study, two occurred in 31-40 years age group and one case occurred in 41-50 years age group. Single case each of Neurofibroma and ganglioneuroma occurred in 31-40 years age group.

Table 7: Age incidence of malignant lesions affecting the vertebral and Para vertebral Bodies

| Type of malignant neoplasm | 0-10 years | 11-20 years | 21-30 years | 31-40 years | 41-50 years | 51-60 years | 61-70 years | 71-80 years | Total |
|--------------------------------|------------|-------------|-------------|-------------|-------------|-------------|-------------|-------------|-------|
| Adenocarcinoma | - | - | - | 06 | 04 | 06 | 04 | - | 20 |
| Squamous cell carcinoma | - | 01 | - | - | 06 | 03 | 01 | - | 11 |
| Myeloma | - | - | - | - | 03 | 02 | - | - | 05 |
| Ependymoma | - | - | 01 | 01 | - | - | - | - | 02 |
| Small round cell tumor | 01 | - | - | 02 | - | - | - | - | 03 |
| Epithelioid angiosarcoma | - | - | - | 01 | - | - | - | - | 01 |
| NHL | - | - | - | - | - | 01 | - | - | 01 |
| MPNST | - | - | - | - | 01 | - | - | - | 01 |
| PEComa | - | 01 | - | - | - | - | - | - | 01 |
| Chordoma | - | - | - | - | - | 01 | - | - | 01 |
| Diffuse fibrillary astrocytoma | - | - | - | - | - | 01 | - | - | 01 |
| Total | 01 | 02 | 01 | 10 | 14 | 14 | 05 | - | 47 |

Among the 47 malignant lesions affecting the vertebral bodies, majority are Adenocarcinomatous secondary deposits (20 cases) occurring in 3rd to 6th decade of life. Other malignant lesions affecting vertebral bodies include Squamous cell carcinoma affecting in 4th to 6th decades, Multiple myeloma affecting in 4th to 5th decade, Ependymoma, small round cell tumor, epithelioid angiosarcoma, MPNST, NHL and PEComa affecting the patient in 2nd decade. Chordoma and Diffuse fibrillary astrocytoma affected the patient in 6th decade.

Among the non neoplastic lesions tuberculosis has equal distribution in both sexes affecting 16 males and 16 females. Other lesions show slight male preponderance. On the whole the non- neoplastic lesions show male preponderance with M: F ratio of 1.4:1.

Table 8: Sex incidence in benign neoplastic lesions

| Type of lesion | Male | Female |
|----------------|------|--------|
| Schwannoma | 10 | 02 |
| Neurofibroma | – | 01 |
| Ganglioneuroma | 01 | – |
| Meningioma | 02 | 09 |
| Hemangioma | 01 | 02 |
| Total | 14 | 14 |

Among the benign neoplastic lesions, schwannoma affected both sexes with male preponderance occurring in 10 males and 02 female patients. Meningioma is the next common lesion which has involved predominantly females affecting 09 women patients and 02 male patients. Hemangioma also showed female preponderance, 2 cases occurring in women and 1 case occurring in males. As a whole benign neoplastic lesions had slight equal sex preponderance with M:F ratio of 1:1.

Table 9: Sex incidence of malignant tumors affecting the vertebrae

| Type of Lesion | Males | Females |
|--|-------|---------|
| Adenocarcinoma | 14 | 06 |
| Squamous cell carcinoma | 06 | 05 |
| Myeloma | 02 | 03 |
| Ependymoma | 01 | 01 |
| Small round cell tumor | 01 | 02 |
| Epithelioid angiosarcoma | 01 | - |
| Non-Hodgkin’s Lymphoma | 01 | - |
| Malignant Peripheral Nerve Sheath Tumour | - | 01 |
| PEComa | 01 | - |
| Chordoma | - | 01 |
| Diffuse fibrillary astrocytoma | - | 01 |
| Total | 27 | 20 |

Most of the malignant lesions affecting the vertebral bodies and paravertebral regions show male preponderance. Adenocarcinomatous secondary deposits affected 14 males and 06 females. Squamous cell carcinomatous deposits in vertebrae affected 06 males and 05 females. Multiple myeloma has slight female preponderance involving 02 male and 03 female patients. Small round cell tumor also has slight female preponderance occurring in one male and in two female patients. Ependymoma has equal sex distribution. Other malignant tumours lesions such as epithelioid angiosarcoma, Non-Hodgkin’s lymphoma, Malignant at Peripheral Nerve Sheath tumour (MPNST) and PEComa affected male patients. On the whole, the malignant lesions have male preponderance with M: F of 1.35:1.

Discussion

The present study was undertaken at Department of Pathology,

Katuri Medical College & Hospital. The study period was 2017 – 2019.

Vertebral lesions are not uncommon. The lesions involving the vertebral region included de novo lesions as well as metastatic lesions. Vertebrae are common site for metastatic deposits. The primary may be from GIT, Prostrate, Kidney, Thyroid etc. Although accurate delineation and depiction of the site, size and extent of spinal lesions is provided by imaging, it is not possible to arrive at an etiological diagnosis in all cases. Therefore the final decision regarding patient management depends on the histopathological diagnosis. So biopsy is almost always necessary before therapy is initiated.

CT guided biopsy is an evolving procedure in the image ology and it is a useful procedure in musculoskeletal lesions, since it allows a tissue diagnosis and generally obviates the need for an invasive surgical open biopsy.³ In many instances by open biopsy the exact site of the lesion can be missed or only very little part of the lesion is obtained and this is now overcome by CT guided biopsy. Also the time taken for the CT guided biopsy procedure is less, it is an outpatient procedure and there is no need of operation Theatre. It is of slight cost effective when compared to the open biopsy technique.

The present study included total of 200 cases involving the vertebral bodies and the paravertebral regions from 2017 to 2019 at the Department of Pathology, Katuri Medical College, Chinakondrupadu, Guntur along with the relevant radiological details obtained from the Department of Radiology of Katuri Medical College & General Hospital. The age incidence ranged from 20 to 80 years, with a median age of 55.5 years. The age distribution in the present study is close to the findings of Merce Jorda *et al*^[11] and Bommer *et al*^[12].

Table 10: Depicting the most common vertebrae involved in the vertebral lesions

| Site of the lesion | Present study | M. Kang <i>et al</i> ^[13] |
|--------------------|---------------|--------------------------------------|
| Lumbar | 97 (48.5%) | 39 (44.82%) |
| Thoracic | 76 (38%) | 38 (43.67%) |
| Cervical | 15 (7.5%) | 06 (6.89%) |
| Sacral | 06 (3.0%) | 04 (4.59%) |
| Paravertebral | 06 (3.0%) | - |

Table 10 depicts the involvement of lesions at different levels in the vertebral column. Majority of the lesions affected the lumbar vertebrae (48.5%), followed by thoracic (38%), cervical (7.5%), sacral vertebrae (3%) and paravertebral region (3.0%). This study correlated with that of M. Kang *et al*^[13] showing lesions predominantly involving lumbar (44.82%) and thoracic vertebrae (43.67%). Cervical vertebrae involvement in the present study is 7.5%, which correlated with that of M. Kang *et al*^[13] where the cervical vertebral involvement is 6.89%.

The 200 lesions included in the present study are categorized into three groups, namely cases comprising no specific pathology, non- neoplastic lesions and neoplastic lesions. No specific pathology lesions are 61 (30.05%), non-neoplastic lesions are 64 (32%), benign neoplastic lesions 28 (14%) and malignant lesions are 47 (23.5%).

No specific pathology lesions which comprised 61 (30.05%) cases showed normal bone trabecular with marrow elements and a few with fibrocartilage nous disc material. There is no evidence of any pathology in these 61 cases. The failure to identify any pathology in these cases might be due to inadequate sampling or the CT guided needle has not entered the lesion proper^[7]. In the study done by Israh Akhtar *et al*^[14] out of 124 cases of vertebral lesions by FNAB revealed no specific

pathology in 16.13% cases thus correlating with the present study. All the patients with no specific pathology didn't have a clinical evidence of malignancy [14]. The present study also correlated with the study done by Carson *et al.* [15] which showed 6 cases (10%) with no specific pathology out of total number of 57 cases.

The non-neoplastic lesions involving the vertebrae in the present study included 64 cases. The majority of non-neoplastic lesions were inflammatory and infective lesions. The most common infective lesions were Koch's spine comprising 32 cases, followed by non specific inflammatory lesions comprising 28 cases. There were 01 case of keratinous cyst, 01 case of lipomeningomyelocele, 01 case of meningomyelocele and 01 case of dermoid cyst. Tuberculous infection is the most common non neoplastic lesion in the present study with equal sex predilection (affecting 16 cases each in both men and women). Age incidence affected in the tuberculosis ranged from 21-60 years with 08 cases affecting at 21-30 years, 05 cases affected between 31-40 years and 06 cases each affected at the ages ranging between 41-60 years. This has correlated with the studies done by M. Kang *et al* [13]. Tuberculosis is the most common non neoplastic lesion in the study done by clinical centre of Sarajevo University, Bosnia with 06 cases (29.3%) affected out of 32 cases.

Dermoid cysts are of developmental in origin. In the spine they may occur at intramedullary, intradural, extra medullary or extra spinal in location.

The prevalence of tuberculosis is around 30 million globally and approximately one third of cases are found in India. 1 to 3% of 10 million patients have involvement of bones and joints. Vertebral tuberculosis is the most common form of skeletal tuberculosis comprising about 50-70% of all bone and joint tuberculosis and may manifest as bony vertebral pain or as paraphrases [16].

In the present study there are 75 cases of neoplastic lesions that involved the vertebrae. Out of these 28 (14%) cases are benign neoplastic lesions and 47 (23.5%) are malignant neoplasms. The common benign lesion noted was schwannoma in 12 (41.3%) cases, 11 (37.9%) cases of meningiomas, 03(10.3%) cases of hemangiomas 01(2.4%) case of neurofibroma, 01 (3.4%) case of ganglioneuroma. In the study done by Israh Akhtar *et al.* [14], benign lesions constituted 5.64% of cases which included schwannoma and hemangiomas.

Table 11: Depicting the involvement of schwannoma at various vertebral levels

| Vertebral level | Number of cases |
|-----------------|-----------------|
| Cervical | 01 |
| Thoracic | 07 |
| Lumbar | 03 |
| Sacral | 01 |
| Total | 12 |

In the present study, schwannomas mainly affected males and meningiomas affected females. Out of 12 cases of schwannoma 07 cases affected the thoracic vertebrae. Neurogenic tumors are the most common cause of a mass lesion in the thoracic paravertebral region in the general adult population. Schwannomas are rare in people <20 years of age and are largely asymptomatic. In the present study the age incidence of schwannomas ranged from 31-50 years of age. Grossly, they appear as sharply circumscribed, encapsulated spherical soft-tissue masses and do not have nerve fibers passing through them. On CT scan schwannomas appear as well-circumscribed,

round masses that are of homogenous soft-tissue density. Vertebral hemangiomas is considered to be a lesion of bone usually of dysembryogenetic origin or a hamartomatous lesion. The prevalence of hemangiomas seems to increase with age and is high after middle age, with a slight female predilection. Three cases of hemangioma included in the present study affected two females and one male patient.

In the present study there were 47 (23.5%) cases of malignant lesions involving the vertebrae and included 15 primary malignant tumors and 32 secondary deposits. The secondary deposits predominantly affected males. Adenocarcinomatous secondary deposits were common comprising 20 cases, followed by squamous cell carcinoma 11 cases. The primary malignant tumors included Multiple myeloma (05) cases, small round cell tumor (03) cases, ependymoma (02) cases, 1 case each of epithelioid angiosarcoma, Non-Hodgkin's Lymphoma, Malignant peripheral nerve malignant lesions adenocarcinomatous deposits are the most common which correlated with the study done by Bommer *et al* [12]. It also correlated with the study done by Israh Akhtar *et al.* [14], which showed 33.87% of malignancies among which adenocarcinomas were predominant followed by squamous cell carcinoma. The most common primary site of malignancy which resulted in vertebral metastases was breast followed by lung and prostate. The most common age group affected was 4th-7th decade. The patients affected by secondary deposits included 21 males and 11 females with a ratio of 1.9 1and in a study done by Israh Akhtar *et al.* [14] also shows male predominance which was correlating with the present study. Also the age and sex incidence in the present study correlated with those of Kang *et al* [13] whose study included 78 patients in which metastatic deposits were most common in vertebral bodies.

Among the primary malignant neoplasms, myeloma was most frequently encountered, followed by lymphoma and Ewing's sarcoma. The incidence of Multiple myeloma in the present study correlated with that of Israh Akhtar *et al* [14]. The vertebral body is the most common site of involvement by plasmacytoma due to its rich red marrow content, but the tumor frequently extends to the pedicles. Plasmacytoma usually manifests with a single collapsed vertebra. The tumor preferentially replaces the cancellous bone, whereas the cortical bone is partly preserved or even sclerotic, resulting in a hollow vertebral body or pedicle. The cortical thickening in the arrangement of plasmacytoma appears to be unique to this tumor and results in a "mini brain" appearance on axial images.

Lymphoma of bone is a rare extra nodal manifestation of non-Hodgkin lymphoma, accounting for only about 1%–3% of all lymphomas.

Peak prevalence occurs in the 5th–7th decades, with a strong male predilection and a single case of Non Hodgkin Lymphoma in the present study is also made. Spinal involvement in lymphomas results much more frequently from late metastatic dissemination of Hodgkin's and non-Hodgkin's lymphoma.

Lymphomatous involvement may manifest as paraspinal, vertebral, and epidural lesions, either in isolation or in combination. Vertebral involvement results more frequently from hematogenous spread than from osseous invasion from adjacent lymph nodes. Lymphomatous involvement is caused by tumor spread from the medullary cavity along the small vascular channels that run through the cortex. It can be seen with other small round cell tumors such as Ewing sarcoma. Contiguous vertebral involvement has also been reported.

Ewing sarcoma is an undifferentiated high-grade tumor with proliferation of uniform small round cells. Necrosis is common.

Primary vertebral Ewing sarcoma is usually seen in the 2nd decade of life (mean age -19.3years), with a slight male predilection. The age groups of three cases of Ewing’s sarcoma included in the present study were between 2nd and 3rd decades out of which two were females and one was male. Lesions may be lytic, sclerotic, or mixed with associated vertebral compression.

Table 12: Depicting the benign lesions at various levels of vertebral column

| Vertebral level | Number of cases |
|-----------------|-----------------|
| Cervical | 05 |
| Thoracic | 15 |
| Lumbar | 05 |
| Sacral | 03 |
| Paravertebral | - |
| Total | 28 |

The table 12 depicts the distribution of 28 benign lesions at various levels of vertebral column, among which thoracic vertebrae are most commonly affected followed by other sites of vertebral column which correlated with the study done by Robert *et al* [17], which showed 20 benign lesions affecting the vertebral column. In the present study majority of the benign lesions especially schwannomas have correlated both radio logically as well as histopathologically. Out of 12 cases of schwannomas, 10 have correlated and in two cases radio diagnosis was not given which on histopathology turned out to be schwannomas. Out of the 11 cases of meningiomas only few (04) have been correlated, While the hemangioma, ganglioneuroma and neurofibroma are diagnosed histopathologically, such possibility was not considered radio logically.

Table 13: Depicting the Primary malignant neoplasms at different levels of vertebral column

| Vertebral level | Number of cases |
|-----------------|-----------------|
| Cervical | 03 |
| Thoracic | 06 |
| Lumbar | 03 |
| Sacral | 02 |
| Paravertebral | 01 |
| Total | 15 |

The above table displays 15 primary malignant lesions affecting the vertebral column out of the total 47 malignant cases. Of the 15 primary malignant lesions, radiological diagnosis of malignancy was made in 10 cases and in the remaining 5 cases an opinion of suspicious malignancy was given. On histopathological examination these 5 cases also turned out to be the seat of primary malignancy. This helped the patients for the appropriate and prompt treatment and thereby avoiding the chances of recurrences. In the present study primary malignancies mainly affected the thoracic vertebrae whereas in Robert *et al*. [17] study they mainly affected the lumbar region.

Table 14: Depicting the Secondary deposits affecting the different levels of the vertebral column

| Vertebral level | Number of cases |
|-----------------|-----------------|
| cervical | 06 |
| Thoracic | 10 |
| Lumbar | 12 |
| Sacral | 02 |
| Paravertebral | 02 |
| Total | 32 |

Out of the total 47 malignant lesions 32 were the secondary deposits affecting the vertebral column in which the lumbar vertebrae is most commonly affected. Adenocarcinomatous deposits are common followed by Squamous cell carcinoma which has correlated with Bommer *et al*. [12] study. Radio diagnosis was correct in all the secondary deposits which have diagnosed as malignancy by CT guided procedure and which turned out to be correct by histopathology too. The accuracy of CT guided biopsy in malignant, primary and secondary lesions was very high when compared to infective, inflammatory and in benign lesions.

Conclusion

We conclude that, FNAB can provide additional clues to aid in the subsequent workup and treatment of cases diagnosed with an unsuspected malignancy and other non-neoplastic lesions. Thorough assessment of the specimen adequacy and correlating with the clinical and radiologic findings, a definitive diagnosis can be made in most cases.

Acknowledgment

The author would like thankful to Department of Pathology for providing all the facilities to carry out this work.

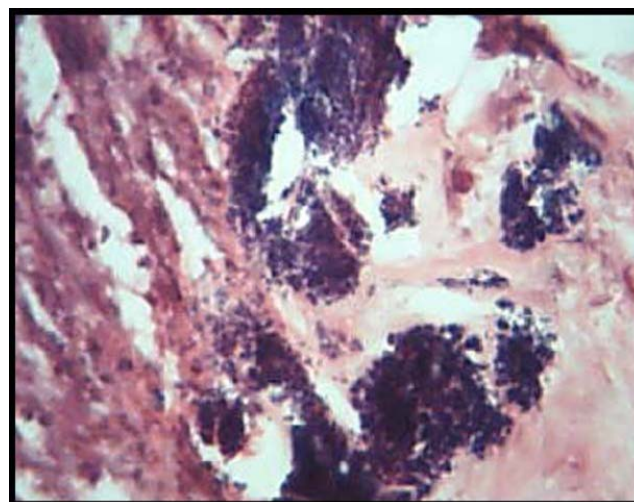


Fig 2: Microphotograph showing abscess with bacterial clumps (H&E X 100)

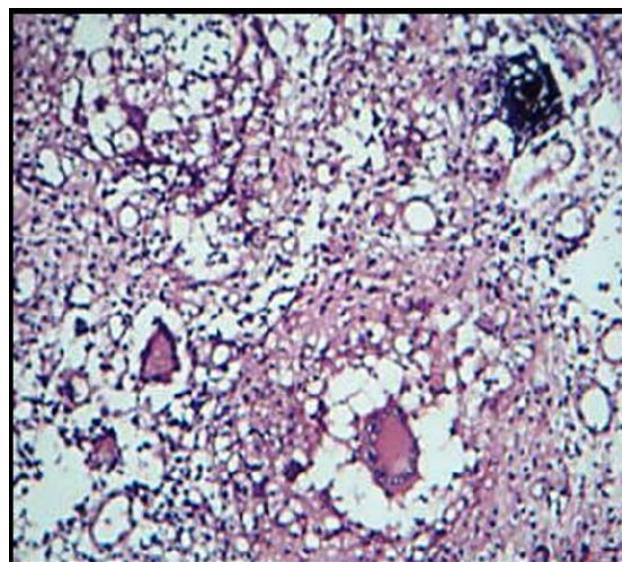


Fig 3: Microphotograph showing Tuberculous osteomyelitis with granulomas (H & E X 100)

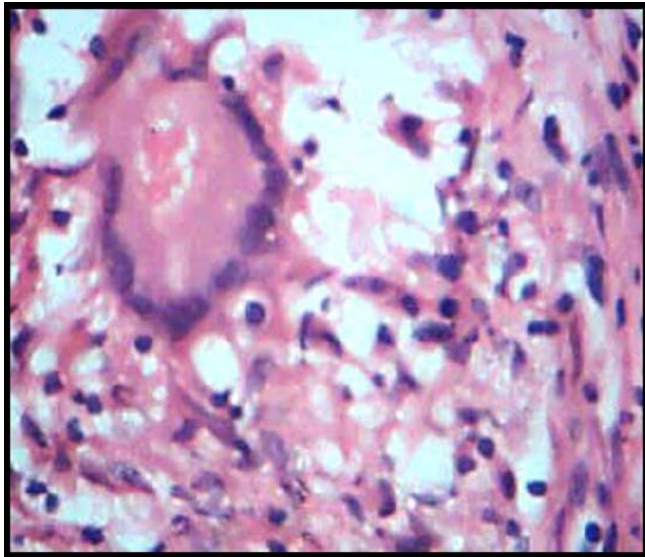


Fig 4: Microphotograph showing Tuberculous osteomyelitis with Langhan's type of giant cell (H & E X 400)

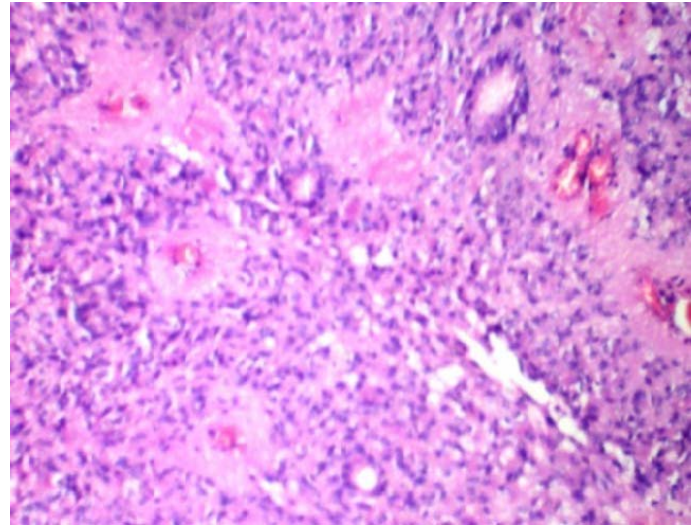


Fig 7: Microphotograph showing perivascular rossettes in Ependymoma (H & E X100)

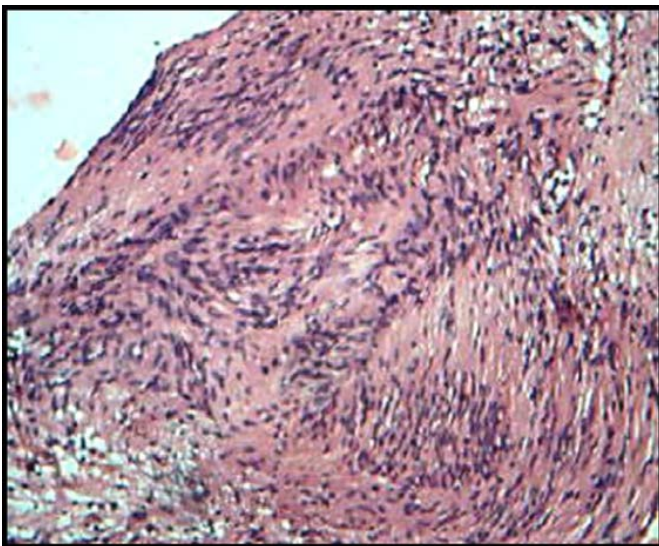


Fig 5: Microphotograph showing schwannoma with Antoni A pattern and verocay bodies (H & E X 400)

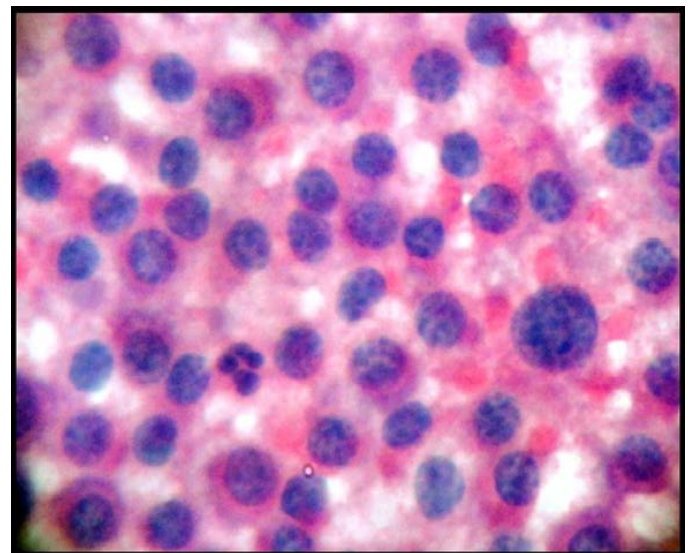


Fig 8: Microphotograph of Myeloma showing malignant plasma cells with eccentrically placed hyper chromatic nucleus exhibiting anisokaryosis (H & E X 400)

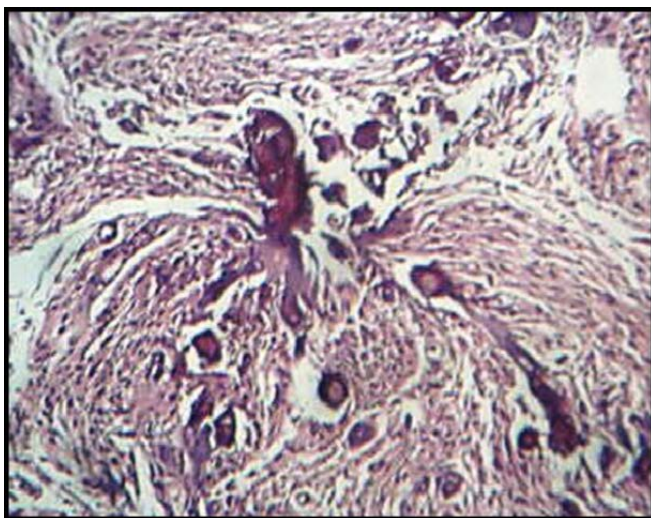


Fig 6: Microphotograph showing Meningioma with psammomatous calcifications (H & E X 100)

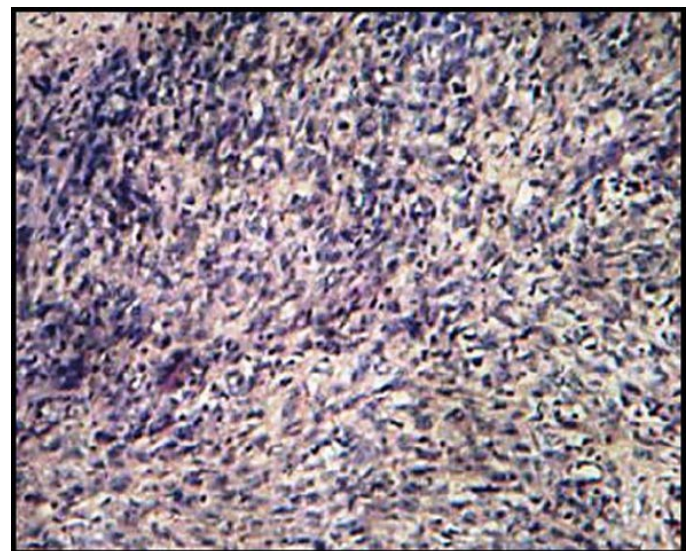


Fig 9: Microphotograph of MPNST showing spindle cells arranged in Storiform pattern (H & E X100)

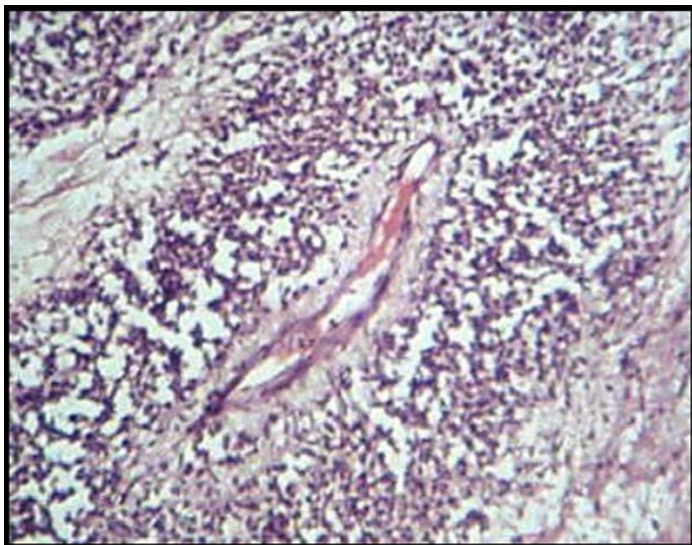

Fig 10: Microphotograph of MPNST showing tumor cells arranged around blood vessel (H & E X100)

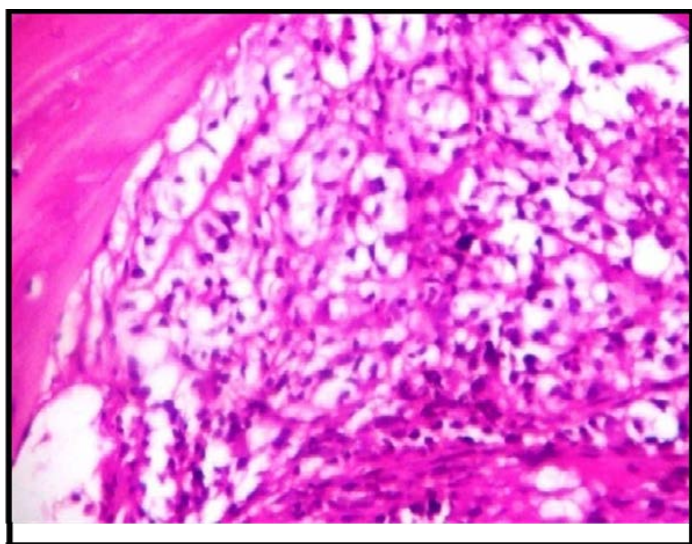


Fig 11: Microphotograph showing metastatic adenocarcinoma clear cell variant (H & E X400)

Conflict of interest: None

References

1. Coley BI SG, Ellis EB. Diagnosis of bone tumors by aspiration Am J Surg. 1931; 13:215–24.
2. De Santos LA, Lukeman JM, Wallace S *et al*. Percutaneous needle biopsy of bone in the cancer patient AJR Am J Roentgenol. 1978; 130:641–9.
3. Naseem A Ansari, Nawal W Derias. Origins of Fine needle aspiration cytology J Clin Pathol. 1997; 50:541-543
4. Steven J Hajdu, Myron R Melamed *et al*. The diagnostic value of aspiration smears, American Journal of Clinical Pathology. 1973; 59:350-56
5. Leyden O.O. Uber infectiose pneumonie Dtsch Med Wschr. 1983; 9:52-54.
6. Menetrier P. Cancer primitif Du poumaon Bull Soc Anat (Paris). 1886; 11:643.
7. Dudgeon LS, Patrick CV. A new method for the rapid microscopical diagnosis of tumours Br J Surg. 1927; 15:250-61.
8. Martin HE, Ellis EB. Biopsy by needle puncture and aspiration Ann Surg. 1930; 92:169-81.

9. Snyder RE, Coley BL. Further studies on the diagnosis of bone tumors by aspiration biopsy Surg Gynecol Obstet. 1945; 80:517–22.
10. Robertson R.C., Ball R.P. Destructive spine lesions; Diagnosis by Needle Biopsy J. Bone & J. Joint Surg. 1935; 17:749-758.
11. Merce Jorda M.D. Ph.D., Luis Rey *et al*, Fine Needle Aspiration Cytology of Bone, accuracy and pitfalls of cytodiagnosis, Cancer Cytopathol. 1999; 90:47-54.
12. Bommer KK, Ramzy I, Mody D. Fine needle aspiration biopsy biopsy in the diagnosis and management of bone lesions *Cancer (Cancer Cytopathol)* 1997; 81:148-56.
13. Kang M, Gupta S, Khandelwal N, Shankar S, Gulati M, Suri S. CT guided FNAB of spinal lesions Acta radiological 1999; 40:474-478.
14. Israh Akhtar M.D, Rhyne Flowers M.D, Anwer Siddiqi MD, Ken Heard B.S.C.T. (ASCP), Mithra Baliga MD. Fine Needle Aspiration Biopsy of Vertebral and Paravertebral Lesions, *Retrospective Study of 124 Cases Acta Cytol.* 2006; 50:364-371.
15. Carson HJ, Castelli MJ, Reyes CV, Gattuso P, Fine Needle Aspiration biopsy of Vertebral lesions: Cytologic, pathologic and clinical correlation of 57 cases, *Diagn Cytopathol* 1994; 11: 348-51.
16. Jain AK, Kumar S, Tuli SM. Tuberculosis of spine. *Spinal Cord.* 1999; 37:362-9.
17. Robert Casadei, Eugenio Rimondi *et al*, Percutaneous CT guided biopsy of spine- result of 430 spine biopsies, 2007.