



E-ISSN: 2616-3470
P-ISSN: 2616-3462
© Surgery Science
www.surgeryscience.com
2020; 4(2): 142-145
Received: 01-02-2020
Accepted: 03-03-2020

Shivaji H Vidyarthi
Assistant Professor, Department of
General Surgery, J.L.N Medical
College Ajmer, Rajasthan, India

Mahesh Kumar Jangir
Postgraduate Resident,
Department of General Surgery,
J.L.N Medical College Ajmer,
Rajasthan, India

Amit Singh
Associate Professor, Department of
General Surgery, R.V.R.S Medical
College, Bhilwara, Rajasthan,
India

A prospective study for comparison between graham's omentopexy v/s figure of eight closures in cases of peptic perforation

Shivaji H Vidyarthi, Mahesh Kumar Jangir and Amit Singh

DOI: <https://doi.org/10.33545/surgery.2020.v4.i2c.407>

Abstract

Aim/Background: The prospective study is planned to compare results of: Graham's omentopexy v/s figure of eight stitch in case of peptic perforation.

Material and Method: A study of 50 patients admitted with peptic perforations at J.L.N. Medical College & Associated group of Hospitals, Ajmer were undertaken from January 2012 to December 2013. The patients suspected of peptic perforations undergoing emergency laparotomy were divided into 2 groups (Graham's omentopexy and Figure of eight closure) of 25 patients each based on the technique of Simple Randomization.

Results: In our study figure of 8 stitches with omentopexy is have less postoperative complications compare with Gramh's omentopexy(leak 1 v/s 3, wound infection 4 v/s 8, fistula 0 v/s 3, death 1 v/s 2).

Conclusion: Closure by figure of 8 stitch was found to be a superior surgical technique over Graham's omentopexy for the closure of peptic perforation.

Keywords: Figure of eight stitch, graham's omentopexy, peptic perforation, fecal fistula

Introduction

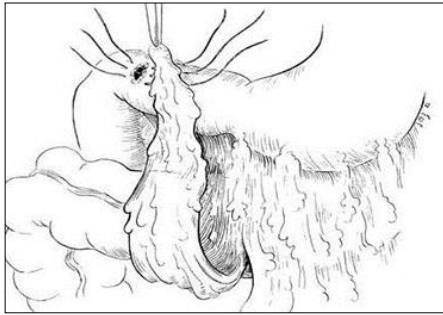
Perforated peptic ulcer is one of the most serious complications of peptic ulcer disease, and is characterized by mortality rates ranging from 6.2% to 27% [1, 2]. So selection of the most appropriate operative approach becomes an important issue for surgeons. Safe and effective surgical treatment is fundamental to achieve favourable outcomes. Several surgical procedures have been devised to treat complicated peptic ulcer. Omentopexy is commonly used in emergency management of duodenal ulcer perforation. Omentopexy was first described by Cullen Jones in 1929 and was later modified by Graham in 1937 [3]. Various complex procedures have been described for treatment of duodenal perforations. These include resection of the perforation bearing duodenum and gastric antrum in the form of a partial gastrectomy, conversion of the perforation into a pyloroplasty, or the closure of the perforation using a jejunal serosal patch or jejunal pedicle. In patients who present with unstable hemodynamics, these procedures may neither be feasible nor desirable because each of the aforementioned options not only prolongs the surgical time but also requires a high degree of surgical expertise and facilities, which may not be available in the emergency setting. We tried to find out a technique that could decrease the leakage rate from the perforation repair site and compare Graham's omentopexy with Figure of eight repair of peptic perforation in term of morbidity and mortality.

1. Graham's Omentopexy: It was first described by Roscoe Graham in 1938. Laparotomy pads are placed around the perforation to contain any further spill while the sutures are being placed. After placing three or four sutures (silk 2-0 RB), a vascularized (pedicled) tongue of omentum is mobilized and brought superiorly to close the defect.

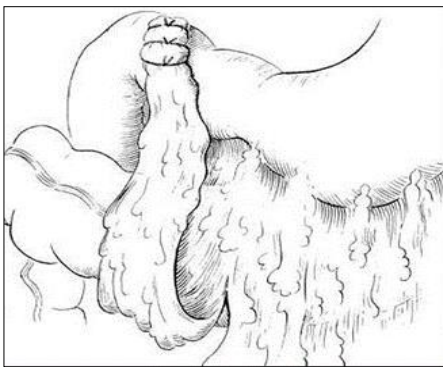
2. Figure of eight closure with omentopexy: In this technique the needle was passed into the duodenum at some distance away from the ulcer (Point A), taken out through the ulcer and then again passed through the ulcer into the duodenum and taken out through all layers of the walls of the duodenum on the distal side (point B). Now, these were not tied but the needle was taken to the proximal side of the ulcer (point C) and passed into the duodenum and taken out through the

Corresponding Author:
Amit Singh
Associate Professor, Department of
General Surgery, R.V.R.S Medical
College, Bhilwara, Rajasthan,
India

ulcer and again passed into the duodenum through the ulcer and taken out distally through the duodenal wall (point D). Now, the suture was tied to make it a figure-of-8. The closed ulcer was covered by live omentum and sutures were applied to the stomach and the duodenum wall to fix the omentum to cover the ulcer area. The suture material used was atraumatic silk.



a) Placement of omental patch over perforation site.



b) Sealed perforation with pedicled omental patch

Fig a-b: Graham's Omentopexy

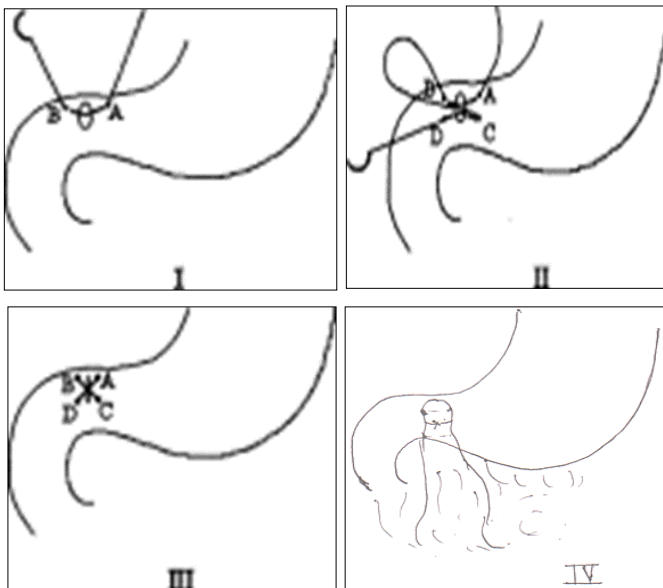


Fig 2: Figure of eight closure with omentopexy

The following advantages were found with this technique

1. The suture can be taken from a relatively longer distance by even a small needle.
2. There is lesser tendency to cut through because the pressure at one point is divided into two directions, and the pressure is exerted on four points instead of two points. When a simple stitch is applied, there are more chances of cut

through the friable and edematous walls because pressure is directed towards one point.

3. The edges of the ulcer do not tend to evert by the effect of the figure-of-8 stitch and approximation of edges has been found to be satisfactory.
4. The cross of the figure-of-8 comes over and supports the most friable and edematous central part of the ulcer.

On completion of the procedure using one of the above mentioned methods, 32Fr. Drain was placed in the pelvis. The abdominal incision is then closed in layers.

Material and Methods

A study of 50 patients admitted with peptic perforations at J.L.N. Medical College & Associate group of Hospitals, Ajmer was undertaken from January 2012 to December 2013. These 50 cases were studied thoroughly according to the Perfora. The details of 50 patients were sorted in a master chart for convenience of analysis & presentation. The patients suspected of peptic perforations undergoing emergency laparotomy were divided into 2 groups of 25 patients each based on the technique of Simple Randomization.

Group A: Graham's omentopexy

Group B: Closure by figure of eight stitch with omentopexy

Inclusion Criteria

All patients diagnosed with perforated peptic ulcer that are fit to undergo surgery.

Exclusion Criteria

- a. Very large perforations exceeding 20 mm in size
- b. Patients having severe co-morbidities malnourished patient.
- c. The patient who were initialing included in study and died before the evidence of leak or died during hospital stay before starting oral liquids.
- d. All gastric perforation where biopsy revealed gastric malignancy.

The patients with peptic perforations admitted to our hospital were treated as follows:

A detailed history of patient was taken when the condition of the patient is stable. In critically ill patients, the patients were resuscitated and history was taken after the patient is stabilized. The hospital records were also reviewed to obtain appropriate epidemiological information regarding age, sex, occupation, and clinical presentation, duration of symptoms, past history of chronic duodenal ulcer, investigations and mode of treatment. This data was essential to evaluate the condition of the patient at the time of admission, duration between perforation and surgery, mode of treatment patient received and post-operative complications and follow up of the patients for the period of 1 month.

The data was also essential to evaluate the efficacy of figure of eight stitch with omentopexy in closure of peptic perforations against Simple closure reinforced with Omentum. Patients were also followed up to know whether they develop recurrence of ulcer symptoms in order to know the effectiveness of operation. The data was also compared with other series to see their conclusion were also true in our patients.

Examination

All the patients with suspected peptic perforations were examined thoroughly and base line findings were recorded. Repeated examination of the patients was done during resuscitation and till the diagnosis was confirmed.

Investigations

Plain x-ray of abdomen (Erect), blood grouping and Rh typing, Hb%, TLC, DLC, ESR, Blood urea, serum creatinine, blood sugar, serum electrolyte, HBsAg and HIV.

In plain x-ray abdomen of erect posture, gas under diaphragm indicated hollow viscus perforation.

The variables studied and analyzed are: Age, Sex, Duration of (problem prior to admission) perforation, General condition of the patient at the time of admission, Site & Size of perforation, Type of surgery, Post-operative complications, Duration of hospital stay, Outcome of the patient.

Results

From January 2012 to December 2013 a total of 50 patients with peptic perforations were studied from surgical units of J.L.N. Hospital, Ajmer. There is a gradual increase in incidence of peptic perforation in old age group, highest in age more than 60 years and lowest in age group 11-20 years. [Table1] Perforation is more common in males with Male: Female ratio in present study is 9:1.

In this series of study, there was an obvious relationship between the smoking, alcohol and tobacco, when compared with non smokers and non-alcoholics, the incidence is convincingly high in case of smokers and alcoholics. NASID was an important contributing factor in the occurrence of peptic perforation. It is seen that 60% of cases were taking NSAID the ratio was 1.5:1. In our series 58% of patients had previous history of peptic ulceration symptoms.

Large group of patients (30) had delayed presentations (>24 hours). The delayed presentation had significant impact on increased morbidity / mortality of the patients. The poorer the general condition of the patient, poor is the final outcome of the patient. [Table 2]

The common mode of presentation of these patients was abdominal pain, vomiting, distension, fever and commonest signs were tenderness, rigidity, guarding, dehydration, shock, absent bowel sounds. [Table3]

Plain X-ray abdomen in erect position was done in all 50 patients and pneumoperitoneum (free air under the diaphragm) was found in all 50 patients. The site of perforation was first part of duodenum in maximum (86%) number of case, where gastric perforations were in 14% of cases only. The size of the perforation is directly proportional to quantity of peritoneal fluid. This finding is directly related to presentation with shock at the time of admission.

Two groups of 25/25 each selected on random basis, one group treated with simple closure reinforced with omentum and 2nd with closure by figure of eight stitch with omentopexy. In this study series, 36 patients had smooth recovery and 14 patients had suffered from various complications of which 3 patients had expired. The most common postoperative complication was wound infection in 12 cases and biliary fistula in 3 cases, which was one of definitive reasons for prolonged hospital stay. In this study series 3 patients had expired; these patients presented with severe shock and septicaemia and died due to multi-organ failure. [Table 4] In our study figure of 8 stitches with omentopexy is have less postoperative complications compare with Gramh's omentopexy (leak 1 v/s 3, wound infection 4 v/s 8, fistula 0 v/s 3, death 1 v/s 2). [Table 5]

The average postoperative hospital stay in our series was 11.48 days for closure by figure of eight stitch with omentopexy and 14.20 days for simple closure reinforced with omentum with a p value of <0.05. In this present study of 50 patients, 3 patients died and follow up was done in 47 patients for 1 month. These

patients were advised with proton pump inhibitor with anti H. pylori therapy.

Discussion

The present study was conducted on 50 patients admitted in various surgical wards of J.L.N. Hospital, Ajmer. Peptic perforation is one of the commonest surgical emergencies requiring hospitalization and early management.

In our study we found 30% cases were more than 60 years of age and 60% cases were more than 40 years. Therefore peak age incidence is 40-70 years (60%). Similar results were seen in Kalpesh Jani *et al.* Who found greater prevalence amongst the older age group (30-60). [Table 1] [4]. In our study peptic perforation was more common in male. The male: female ratio is 9:1. The explanation for this high incidence in the male was that they were subjected to more stress and strain of life. The incidence of smoking and alcohol consumption may also be contributory factors. Our results are similar to Kalpesh Jani *et al.* found male: female ratio 8.1: 1 [4].

In our study peptic perforation was more common in smokers and alcoholics 84% as compare to non smoker and non alcoholics (16%) (Ratio 5.25:1). Smoking was an important contributing factors in peptic perforation. Smoking and alcohol impairs healing of ulcer and favors recurrence of ulcer and subsequent perforation possibly by suppression of mucosal prostaglandin synthesis.

In our study, peptic perforation was found to be more common (30/50) 60% in NSAID's users as compared to non NSAID's user 40% (20/50) (i.e. – 1.5:1). These findings are almost comparable to Odense *et al.* in 2001(75%) who had a slightly higher percentage in NSAID users as compared to control [5]. In our study we found that the perforation was located at 1st part of duodenum in 86% cases and in 14% cases it was gastric.

In the present study we also found that the age, site of perforation, size of perforation, duration of perforation, preoperative shock are the risk factors for the outcome of perforated peptic ulcer. Poor results and increased morbidity in form of leak was seen in patients who presented late and where perforation size was more. In our cases mortality was higher in patients with late presentation.

In our study we found figure of 8 stitch with omentopexy technique for perforated peptic ulcer, a better technique than Graham's omentopexy in terms of leak, fistula and death. Similar results were observed by Gupta *et al.* who found that figure of 8 stitch technique was better closure option. [Table 5] [6] In our study operative morbidity rate was 28% the most common complication was found to be wound infection (24%) 12 cases. Four cases (16%) in group of perforation that were closed by figure of 8 stitch with omentopexy and 8 cases (32%) in group of Graham's omentopexy. This was followed by leak and fistula 6 cases (12%) all in group of Graham's omentopexy. [Table 5]

The technique of Graham's omentopexy does not provide adequate release of tension over suture line which is evident in cases where figure of 8 sutures reinforced with omentum is used. Laparoscopic surgery for the management of perforated peptic ulcers has advantages associated with minimally invasive surgery, such as lower surgical site infection, shorter hospital stays, and less postoperative pain [7].

However, concerns remain regarding the laparoscopic treatment of perforated peptic ulcers. The incidence of leakage at the repair site may be higher than that of open surgery, and the reported leakage rates after laparoscopic repair range from 3.8-16%, and this method should be considered only in selected patients with low surgical risk [7, 8].

Table 1: Shows the age incidence.

Age group (in years)	No. of cases	Percentage
11 – 20	1	2
21 – 30	8	16
31 – 40	11	22
41 – 50	8	16
51 – 60	7	14
>60	15	30

Table 2: Shows impact of duration on the outcome

Duration (in hrs)	No	General condition of the patient on admission		Recovery		
		Good/Average	Shock	Good	Complications	Death
0 – 12	2	2	--	1	1	--
12 – 24	18	15	3	10	8	--
>24hours	30	18	12	16	14	3

Table 3: Shows signs of study patients

Signs	No. of cases
Dehydration	45
Shock	15
Pallor	20
Distension	30
Tenderness	50
Rigidity	46
Absent bowel sounds	40

Table 4: Shows postoperative complications.

Complications	No. of cases	Percentage
Leak	3	6%
Wound infection	12	24%
Fistula	3	6%
Death	3	6%

Table 5: Type of surgery with its postoperative complications

Complications	Simple closure with omentopexy		Figure of eight stitch with omentopexy		P value
	No. of cases	Percentage (%)	No. of cases	Percentage (%)	
Leak	3	12	0	0	NA
Wound infection	8	32	4	16	>0.05
Fistula	3	12	0	0	NA
Death	2	8	1	4	>0.05

Conclusion

Closure by figure of 8 stitch was found to be a superior surgical technique over Graham's omentopexy for the closure of peptic perforation in term of post-operative complications and mortality. Figure of 8 stitch closure of peptic perforation is not a difficult technique, does not require any special training and easily performed by beginners.

References

- Moller MH, Adamsen S, Thomsen RW, Moller AM. Multicentre trial of a perioperative protocol to reduce mortality in patients with peptic ulcer perforation. *Br J Surg.* 2011; 98:802-810.
- Jung Jun Yoon, Hyung Ook Kim, Kyung Jung UK, Sung Ryol Lee. Laparoscopic Single Figure of Eight Suturing Omentopexy for the Treatment of a Perforated Duodenal Ulcer. *J Minim Invasive Surg.* 2019; 22(1):23-28.
- Cellan-Jones CJ. A rapid method of treatment in perforated duodenal ulcer. *Br Med J.* 1929; 36:1076-1077.
- Jani K, Saxena AK, Vaghasia R. Omental plugging for large sized duodenal peptic perforations: A prospective randomized study of 100 patients. *Southern Medical Journal.* 2006; 99(5):467-471.
- Tayside. Odense Sonia Herhandez Luis Albero: Incidence of peptic perforation in NSAID's usages in *Journal of Clinical Epidemiology.* 1998-2002, 55.
- Gupta SP. A Safer Technique of Closure of Peptic Ulcer Perforation. *Indian J Surg.* 2011; 73(5):361-362. DOI 10.1007/s12262-011-0336-0
- Lunevicius R, Morkevicius M. Systematic review comparing laparoscopic and open repair for perforated peptic ulcer. *Br J Surg.* 2005; 92:1195-1207.
- Lunevicius R, Morkevicius M. Management strategies, early results, benefits, and risk factors of laparoscopic repair of perforated peptic ulcer. *World J Surg.* 2005; 29:1299-1310.