



# International Journal of Surgery Science

E-ISSN: 2616-3470

P-ISSN: 2616-3462

© Surgery Science

<https://www.surgeryscience.com>

2024; 8(1): 22-26

Received: 15-11-2023

Accepted: 18-12-2023

**Dr. Khushboo Sachdeva**

PG Resident, Department of  
General Surgery, GS Medical  
College, Hapur, Uttar Pradesh,  
India

**Dr. Madhubala Gaur**

Professor and Head, Department  
of General Surgery, GS Medical  
College, Hapur, Uttar Pradesh,  
India

**Dr. Tripti Mahatme**

Associate Professor, Department of  
Paediatrics, GS Medical College,  
Hapur, Uttar Pradesh, India

**Dr. Bhaskar Kumar**

Associate Professor, Department of  
General Surgery, GS Medical  
College, Hapur, Uttar Pradesh,  
India

**Dr. Vishal Agrawal**

Prof Dept of General Surgery, GS  
Medical College, Hapur

## A comparative study of inguinal hernia repair by open versus laparoscopic technique in Paediatric age group

**Dr. Khushboo Sachdeva, Dr. Madhubala Gaur, Dr. Tripti Mahatme, Dr.  
Bhaskar Kumar and Dr. Vishal Agrawal**

DOI: <https://doi.org/10.33545/surgery.2024.v8.i1a.1044>

### Abstract

**Background:** Herniotomy, often known as open surgery, has traditionally been the established method for treating inguinal hernias in children. The enhancement of paediatric Laparoscopic hernia repair and the accumulation of expertise in Laparoscopic technique have become crucial proficiencies. The adoption of laparoscopic repair for inguinal hernias in children is characterized by its rapidity, cost-effectiveness, esthetic benefits, minimal invasiveness, high feasibility, and reduced discomfort levels. This approach enables the diagnosis and correction of contralateral hernias in the same setting.

**Aims and Objectives:** Our study aimed to compare the outcomes of inguinal hernia repair in two study groups: open hernia repair and laparoscopic hernia repair.

**Materials and Methods:** The ongoing prospective study was conducted in the Department of General Surgery, G S medical college and hospital Hapur, involving a total of 85 children. During a prospective research conducted of 85 children received either laparoscopic surgery (35) or open surgery (34) for the treatment of primary inguinal hernia (PIH). The study recorded and compared the duration of the operation, complications during and after the surgery, postoperative pain, length of stay after the surgery, cosmetic outcomes, and the size of the testis to identify any changes in outcomes. The patients were monitored for a mean duration of 3.5 months.

**Conclusion:** The study's data indicated that the Laparoscopic approach has several advantages, including less postoperative discomfort, the ability to diagnose and manage CPPV in one procedure, a quicker return to normal activities, improved cosmetic outcomes, cost-effectiveness, feasibility, and reduced pain.

**Keywords:** Herniotomy, surgery, cosmetic, Laparoscopic, paediatric

### 1. Introduction

The term "hernia" originates from the Latin word "rupture." A hernia is characterized as an anomalous bulging of an organ or tissue through a structural flaw in its enclosing walls. Hernias can arise in several locations across the body, but they most frequently affect the abdominal wall, specifically the inguinal region.

In India, inguinal hernia repair is a frequently performed surgical procedure due to its high occurrence rate and the availability of various effective treatment methods.

Progress in perioperative anesthesia and operating technique has transformed this procedure into an outpatient ambulatory operation characterized by minimal recurrence rates and morbidity. Considering the results achieved, the primary factors to be taken into account in hernia repair are the quality of life and the speed of recovery.

Around 75% of abdominal wall hernias are located in the groin region. The lifetime prevalence of inguinal hernia is 27% in males and 3% in females. Out of all the surgeries conducted to correct inguinal hernias, 90% are carried out on males, and the remaining 10% are performed on females.

The technique of choice for inguinal hernia repair until the early 1990s was open anterior surgical surgery with mesh prostheses. However, the development of laparoscopy in that period altered the approach to this procedure. The laparoscopic approach offers advantages such as a reduced occurrence of persistent pain and a quicker resumption of work. The laparoscopic method offers notable benefits for patients with bilateral hernias, recurrent hernias that were previously fixed using an anterior approach, and femoral hernias. To establish a long-lasting repair, a comprehensive understanding of groin anatomy is necessary, regardless of the method used.

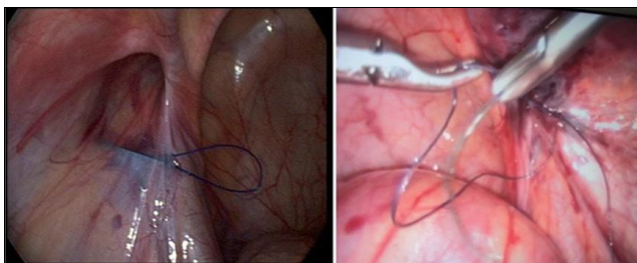
**Corresponding Author:**

**Dr. Tripti Mahatme**

Associate Professor, Department of  
Paediatrics, GS Medical College,  
Hapur, Uttar Pradesh, India

Abdominal wall hernias exclusively arise in areas where the aponeurosis and fascia lack coverage from striated muscle. The places that are most frequently affected are the inguinal, femoral, and umbilical areas, as well as the linear alba, the lower portion of the semilunar line, and locations where previous incisions have been made. The neck, or opening of a hernia, is situated at the deepest layer of muscle and connective tissue, while the hernia sac is covered by the peritoneum and bulges out from the neck. The size of a hernia sac does not necessarily correspond to the size of the hernia defect.

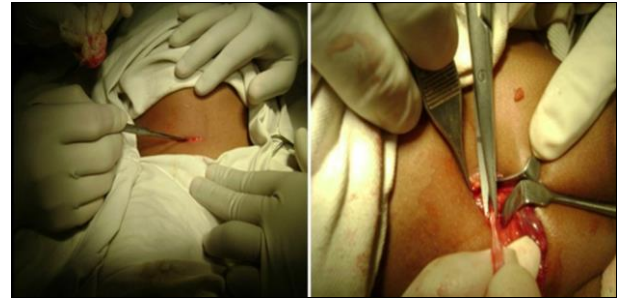Laparoscopic hernia repair is becoming a preferred option to open herniotomy for young patients, offering superior outcomes. The prevalence of inguinal hernias in boys is estimated to be around 80-90%. Approximately 33% of hernias in children manifest within the initial 6 months of their life. If the closure of the processus vaginalis is delayed or inadequate, it can gradually stretch and eventually develop into a hernia. The highest occurrence of this condition is most prevalent during the first year of life. Boys are disproportionately affected, with a prevalence roughly six times higher than that of girls. Additionally, the condition is more commonly observed on the right side rather than the left side. According to a study, 10% of hernia instances are bilateral [1]. The initial Laparoscopic repair of inguinal hernia was documented in the 1990s [2]. Since then, numerous techniques have been documented, which can be categorized into two distinct classes [2]. The intra-corporeal approach involved the dissection, ligation, and division of the sac, which closely resembled the traditional inguinal herniotomy [3, 4]. The symptoms of LH are identical to those of OH. Recent research indicates that the age, size, and body weight of patients do not pose restrictions in laparoscopic repair [5, 6]. The laparoscopic method offers a spacious operative field, which facilitates the procedure's relative simplicity. However, it poses a difficulty for pediatric surgeons when operating on little infants. Consequently, surgeons who lack experience are hesitant to conduct laparoscopic repair in children, particularly in neonates or infants in the early age range [7, 8, 9]. Considering the challenges associated with open repair in this age range, LH offers certain advantages. The open repair procedure in infants requires technical expertise due to the inherent challenges associated with this approach, such as the delicate nature of the hernia sac and the susceptibility of the spermatic cord [10, 11]. As a result, the risks of recurrence and testicular atrophy are higher in newborns or tiny infants [12, 13].



**Fig 1:** Laparoscopic repair inguinal hernia

By contrast, laparoscopic repair offers a direct and uncomplicated method for addressing inguinal hernias, allowing for repair to be carried out with minimal handling of the spermatic cord. These procedures are conducted on children using general anesthesia. Laparoscopy is employed to examine the contralateral internal ring [14]. Becmeur *et al.* and Tsai *et al.* outlined a method in which they surgically removed the processus vaginalis and subsequently sealed the inguinal ring.

They asserted that their approach yielded outstanding outcomes, with recurrence rates ranging from 0 to 1.2% [15]. There are two distinct methods for treating paediatric hernias: open repair and laparoscopic repair. Laparoscopic surgery involves many procedures, such as purse string or z-suture. The objective of this study is to evaluate the outcomes and complications of open inguinal hernia repair in children with two laparoscopic repair techniques: Z suture and purse string. The study will focus on both early and late issues. Based on this study, it is evident that LH is a viable alternative to open repair. However, further research is required to establish a definitive superiority of one treatment over the other. This review seeks to compare LH with OH in terms of surgical time, patency of the contra-lateral deep ring, post-operative complications, and recurrence rates.



**Fig 2:** Open repair of inguinal hernia

## 2. Aim of the study

In our study we aimed to compare between the outcomes and complications of the conventional opened repair and the laparoscopic repair of paediatric inguinal hernia.

## 3. Materials and Methods

This study aimed to compare the outcomes, benefits, and downsides of laparoscopic surgery vs open repair in the management of paediatric inguinal hernia. A comparative study was conducted at the Department of General Surgery, G S medical college and hospital Hapur, over a period of one year. The ethical committee has granted approval for this investigation. A total of 85 children, aged between 2 and 14 years, who were diagnosed with either inguinal hernia or congenital hydrocele, were divided into two groups.

A comprehensive inquiry was conducted to gather pertinent information, and a thorough examination was carried out to determine their suitability for anesthesia. Each of these patients was scheduled for surgery.

The laparoscopic operation was conducted using the conventional method of three 5mm ports, while maintaining an intra-abdominal pressure of 8-10mm Hg. The internal ring was completely eliminated utilizing the purse string or z suture technique with 3-0 vicryl. If the contralateral side was determined to be open, a comparable surgery was carried out. A skin crease incision was utilized to accomplish an open herniotomy. The sac was ligated with a 3-0 RB Vicryl suture. A small incision was made in the distant sac to avoid the development of hydrocele after the surgery. The wound was sutured using a layered closure technique. All surgeries required written informed consents from the guardians of all patients.

**3.1 Statistical analysis:** In this study obtained data were presented as mean +/-SD, ranges number and ratio. Statistical analysis result was analysed using number in study by student T test and ranges (categories data) by Chi square test and fishers exact test also used for proportions. P value less than 0.05 was considered statistically significant.

#### 4. Study parameters

**Table 1:** Shows post operative parameters

Serial no.	Parameters
1	Operation time
2	Size of incision
3	Intraoperative complications
4	Intraperitoneal pressure
5	Postoperative pain
6	Recovery
7	Postoperative complications
8	Discharge
9	Recurrence
10	Cosmesis
11	Testicular atrophy

Table 1 displays the evaluated parameters. The evaluation of postoperative pain was conducted by employing the Children and Infant Postoperative Pain Score for children under the age of 3, and the Children's Hospital of Eastern Ontario Pain Score for patients aged 3 and above. The Verbal Response Score was used to examine older children as well. Acetaminophen was administered to children in need of pain relief at a dosage of 15 mg/kg each dose, every 6 hours, for analgesic purposes. Patients were discharged upon achieving hemodynamic stability, without any lingering effects from anesthesia, with good tolerance for oral eating, and being able to walk.

The parents of the patients were instructed to schedule follow-up appointments for their children in the outpatient department on designated days. The participants underwent evaluation for postoperative discomfort, postoperative complications, scar cosmesis, recurrence, and any changes in testicular size compared to their preoperative condition. The patients were monitored for an average duration of 3.5 months in order to assess the short-term results.

**Table 2:** Demographic data and results exclusively of unilateral repairs

S No	Parameters	Open(n=34)	Lap(n=35)	P-Value
1	Age	4.17±0.95	6.59±5.62	0.01
2	<b>Sex</b>			
	M	32 (94.12%)	30 (85.71%)	0.449
	F	2 (5.88%)	5 (14.29%)	0.449
	<b>Side of hernia</b>			
	Right	18 (52.94%)	26 (74.29%)	0.0652
	Left	16 (47.06%)	9 (25.71%)	0.0652
3	Time in minutes	32.68±12.35	26.37±15.05	0.06328
4	<b>Pain</b>			
	Nil	0	2 (5.7%)	
	Mild	32 (94.12%)	30 (85.7%)	0.449
	Moderate	2 (5.88%)	3 (8.57%)	0.986
	<b>Recovery</b>			
	<3hrs	32 (94.12%)	26 (74.3%)	0.0245
	>3&<6hrs	2 (5.88%)	9 (25.71%)	0.0245
6	<b>Discharge</b>			
	<36hrs	33 (97.06%)	31 (88.57%)	0.391
	48hrs	1 (2.94%)	4 (11.43%)	0.295
7	Complications	5/34(14.7%)	4/35(11.4%)	0.993
	Hydrocele	1 (2.9%)	2 (5.7%)	
	Scrotal edema	2 (5.8%)	0	
	Peritoneal bleed	0	2 (5.7%)	
	Erythema	2 (5.8%)	0	
	Recurrence	0	0	
8	<b>Cosmesis</b>			
	Excellent	0	35(100%)	
	Good	34(100%)	0	

Out of the 85 children, 77 were male and 7 were female. Among them, 61% had clinically right-sided hernias, 32% had left-sided hernias, and 7% had hernias on both sides. LS was performed on a total of 51 patients, out of which 35 children underwent purely unilateral (UL) repairs.

The results, specifically comparing the restorations of the left shoulder (LS) and right shoulder (OS), are presented in Table 2. The average age of children undergoing orthopedic surgery (OS) was substantially lower than those undergoing laparoscopic surgery (LS). The discrepancy arose from the pediatric surgeon operating on a higher number of extremely young children, which can be attributed to referral bias. Excluding these children, there was no significant disparity in age between the OS and LS groups. LS demonstrated a slightly faster performance compared to OS, with a time of 25.31 minutes versus 30.65 minutes. However, this difference was not found to be statistically or clinically significant, as indicated by a p-value of 0.06. The disparity in pain perception between LS and OS was negligible.

A higher percentage of children who underwent LS experienced a delay in immediate postoperative recovery (less than 3 hours) compared to other procedures (P=0.02). However, the length of hospital stay was not significantly different between the two groups (P=0.39). All patients, with the exception of one individual in the OS group, were discharged within a 10-hour timeframe following the surgical procedure. In the LS group, nearly all individuals, except for four, were discharged within a comparable timeframe. Patients who were detained overnight were detained either due to geographical distance (3 patients in the LS group) or parental concerns (1 patient each in the LS and OS group).

The rates of complications were comparable (P=0.99). Two occurrences of laparoscopic procedures resulted in trivial peritoneal hemorrhage caused by needle damage. Temporary hydroceles, lasting only a few days, were found in two individuals that underwent laparoscopic surgery and in one case that underwent traditional surgery. Two instances experienced mild swelling of the scrotum after undergoing OS, although this swelling decreased on its own within a few days. Two instances who had standard procedures exhibited erythema along the suture line, which subsequently disappeared with the use of oral antibiotics. The aesthetic appearance in the left side (LS) was better than in the right side (OS). Twenty-two percent of infants who had LS had CPPV, which were corrected simultaneously.

#### 5. Discussion

Inguinal hernia is a prevalent issue in children, and herniotomy is the established therapeutic method against which all other treatment options are assessed. It is acknowledged for its simplicity in execution, high rate of success, and minimal incidence of problems.

However, in line with the boom in minimally invasive surgery across all surgical disciplines, laparoscopy is also becoming increasingly popular for pediatric hernia surgery. Nevertheless, there is disagreement regarding its broader acceptance as the preferred technique.

Several advanced methods for treating post-inflammatory hyperpigmentation (PIH) have emerged in recent years. The most often used and well-established procedure is the traditional 3-port method, which involves suturing the internal ring inside the body. There is a consensus that it is necessary to examine if laparoscopy offers any substantial benefits compared to open surgery in the treatment of PIH.



### 5.1 Operative time

During open surgery, a significant amount of effort is spent on accessing the surgical site, achieving sufficient visibility, and accurately identifying and separating the sac from the cord structure. When using LS from inside the area of interest, there is no bleeding, and the magnification provides a stunningly clear view of the anatomy, allowing for precision surgery. However, the most time-consuming procedure is still the suturing process within the body, which requires a high level of hand-eye coordination, particularly while navigating the back and middle half-circle of the internal ring, around the iliac and inferior epigastric veins. We discovered that LS was slightly faster.

### 5.2 Postoperative pain

The disparity in postoperative discomfort experienced after open heart surgery (OH) versus laparoscopic hysterectomy (LH) is a topic of debate. Certain reports indicate a decrease in discomfort, while others indicate an increase in pain immediately after surgery when comparing LH to OH. The pain perception was observed to be lower in the LH group, regardless of the method. Aside from the parietal discomfort resulting from port installation, capnoperitoneum induces visceral pain through peritoneal and diaphragmatic straining as well as acidosis. Both the utilization of smaller ports and the implementation of caudal analgesia would not entirely eliminate pain subsequent to laparoscopy. Therefore, there is a notable disparity in the level of pain experienced after surgery between patients who underwent LH and OH procedures. LH results in reduced postoperative pain following surgery.

### 5.3 Recovery and Discharge

A higher number of patients undergoing LH experienced delayed recovery from the effects of anesthesia. This could be attributed to the requirement for more profound anesthesia and muscle relaxation during intubations in LH. Surgical procedures, such as OH, can effectively be carried out on patients wearing a face mask, particularly when caudal analgesia is delivered at the same time.

All of the patients were not discharged on the same day as their operation. The average duration of hospitalization following laparoscopic repair was shorter compared to open repair in our study.

There was a statistically significant difference in the duration of hospitalization between the two operations.

## 6. Conclusion

The open inguinal hernia repair is a highly effective procedure for repairing hernias in children. However, in comparison to the laparoscopic treatment, the open surgery has a longer duration, extended hospitalization, increased need for post-operative pain relief, and inferior cosmetic outcomes. The present study demonstrates that Laparoscopic herniotomy is a secure and efficient procedure for pediatric patients. Additionally, it offers a more comfortable experience for patients, as compared to traditional surgical approaches.

### 6.1 Conflict of Interest

Not available

### 6.2 Financial Support

Not available

## 7. References

1. Singer C. Galen on Anatomical procedures. London: Oxford University Press; c1956.

2. Lobe TE, Schropp KP. Inguinal hernias in pediatrics: initial experience with laparoscopic inguinal exploration of the asymptomatic contralateral side. *J Laparoendosc Surg.* 1992;2:135-40.
3. Miltenburg DM, Nutterm JG, Jaksie T, Kozinetz C, Brandt ML. Laparoscopic evaluation of pediatric inguinal hernia- A meta-analysis. *J Pediatr Surg.* 1997;33:874-879.
4. Birk D, Formentini A, Poch B, Kunz R, Beger HG, Facs MD. The value of intraoperative laparoscopic examination of the contralateral inguinal ring during hernia repair in children. *J Laparoendosc Adv Surg Tech A.* 1998;8(6):373-9.
5. Wills VL, Hunt DR. Pain after laparoscopic cholecystectomy. *Br J Surg.* 2000;87:273-284.
6. Kurkchubasche A, Tracy T. Unique features of groin hernia repair in infants and children. In: Fitzgibbons R, Greenburg A, editors. *Nyhus and Condon's hernia.* Philadelphia: Lippincott Williams & Wilkins; c2002. p. 435-5.
7. Erez I, Rathause V, Vacian I, *et al.* Preoperative ultrasound and intraoperative findings of inguinal hernia in children: a prospective study of 642 children. *J Pediatr Surg.* 2002;37:865-868.
8. Bose SM. Changing face of health care and our responsibilities. *Ind. J Surg.* 2003;65(1):17-19.
9. Udwardia TE. Hence this special issue [editorial]. *Ind. J Surg.* 2003;65(1):20-21.
10. Holcomb GW, Miller KA, Chaignaud BE, Shew SB, Ostlie DJ. The parental perspective regarding the contralateral inguinal region in a child with a known unilateral inguinal hernia. *J Pediatr Surg.* 2004;39:480-2.
11. Chan KL, Tam PKH. Technical refinements in laparoscopic repair of childhood inguinal hernias. *Surg Endosc.* 2004;18:957-960.
12. Manoharan S, Samarakkody U, Kulkarni M, Blakelock R, Brown S. Evidence-based change of practice in the management of unilateral inguinal hernia. *J Pediatr Surg.* 2005;40:1163-1166.
13. Ekstein P, Szold A, Sagie B, Werbin N, Klausner JM, Weinbroum AA. Laparoscopic surgery may be associated with severe pain and high analgesia requirements in immediate postoperative period. *Ann Surg.* 2006;243:41-46.
14. Saranga Bharathi R. Comparative study of laparoscopic versus conventional surgery for congenital inguinal hernia in children. MS thesis. University of Pune; c2007.
15. Saranga Bharathi R, Arora M, Baskaran V. How we "Seal" the internal ring in pediatric inguinal hernias. *Surg Laparosc Endosc Percutan Tech.* 2008;18(2):192-194.
16. Parelkar SV, Oak S, Gupta R, Sanghvi B, Shimoga PH, Prakash A, *et al.* Laparoscopic inguinal hernia repair in the pediatric age group- experience with 437 children. *J Pediatr Surg.* 2010;45(4):789-92.
17. Alzahem A. Laparoscopic versus open inguinal herniotomy in infants and children: a meta-analysis. *Pediatr Surg Int.* 2011;27(6):605-12.
18. Shalaby R, Ismail M, Samaha A, Yehya A, Ibrahim R, Gouda S. Laparoscopic inguinal hernia repair; experience with 874 children. *J Pediatr Surg.* 2014;49:460-4.
19. Zani A, Eaton S, Hoellwarth ME, Puri P, Tovar J, Fasching G, *et al.* Management of pediatric inguinal hernias in the era of laparoscopy: results of an international survey. *Eur J Pediatr Surg.* 2014;24(1):9-13.
20. Esposito C, Escolino M, Cortese G, Aprea G, Turra F, Settimi A, *et al.* Twenty-year experience with laparoscopic

inguinal hernia repair in infants and children: considerations and results on 183 hernia repairs. Surg Endosc. 2017;31(3):1461-8.

**How to Cite This Article**

Sachdeva K, Gaur M, Mahatme T, Kumar B, Agrawal V. A comparative study of inguinal hernia repair by open versus laparoscopic technique in paediatric age group. International Journal of Surgery Science. 2024;8(1):22-26.

**Creative Commons (CC) License**

This is an open-access journal, and articles are distributed under the terms of the Creative Commons Attribution-Non Commercial-Share Alike 4.0 International (CC BY-NC-SA 4.0) License, which allows others to remix, tweak, and build upon the work non-commercially, as long as appropriate credit is given and the new creations are licensed under the identical terms.