



E-ISSN: 2616-3470  
P-ISSN: 2616-3462  
© Surgery Science  
www.surgeryscience.com  
2019; 3(3): 207-211  
Received: 14-05-2019  
Accepted: 18-06-2019

**Dr. Jamal K AL-Qaysi**  
Department of Surgery, College of  
Medicine, AL- Iraqia University,  
Iraq

## Management of post-operative enterocutaneous fistula

**Dr. Jamal K AL-Qaysi**

**DOI:** <https://doi.org/10.33545/surgery.2019.v3.i3d.171>

### Abstract

A consecutive series of 22 patients who developed enterocutaneous fistula within 12 days of abdominal surgery. All the patients were treated conservatively with total bowel rest and intravenous hyperalimentation. In 13 (53%) spontaneous fistula closure occurred, in an average period of 20 days. In 9 patients, the fistula failed to close. Three patients died from intra-abdominal sepsis before surgery. In six patients, surgery was performed, but was effective in only 2 cases. Thus the fistula eventually closed in 15 patients, additional 3 cases died of septicemia with persistent of fistula in one patient. It appears that conservative treatment is highly recommended for early management of enterocutaneous fistula.

**Keywords:** Fistula, enterocutaneous, management

### Introduction

The anterior abdominal wall comprises the skin, Fascia which are the superficial fatty layer Camper's fascia and the deep fibrous (Membranous) layer Scarpa's fascia. There is no deep fascia in the trunk. The abdominal muscles (and their respective aponeuroses), These comprise, external oblique, internal oblique, transversus abdominis, rectus abdominis and pyramidalis muscles, the other layers are transversalis fascia, extraperitoneal fat, and parietal peritoneum. The rectus sheath encloses the rectus muscles. The sheath is made up from the aponeuroses of the muscles of the anterior abdominal wall. The linea alba represents the fusion of the aponeuroses in the midline. Throughout the major part of the length of the rectus the aponeuroses of external oblique and the anterior layer of internal oblique lie in front of the muscle and the posterior layer of internal oblique and transversus behind the rectus muscle. The lateral border of the rectus is the linea semilunaris can usually be identified in thin subjects. It crosses the costal margin in the transpyloric plane.

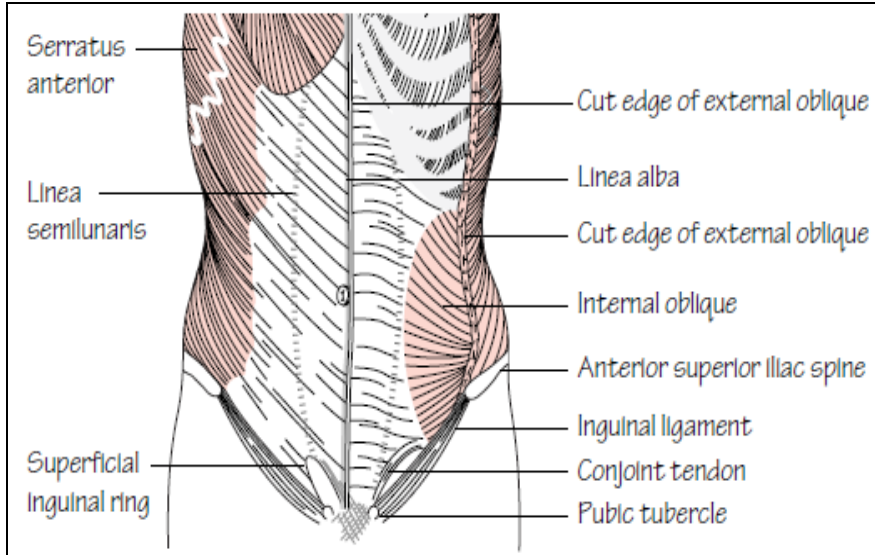
Three tendinous intersections firmly attach the anterior sheath wall to the muscle itself. They are situated at the level of the xiphoid, the umbilicus and the last one is between these two. These give the abdominal 'sixpack' appearance in muscular individuals. The gut is divided into foregut, midgut and hindgut, supplied, respectively, by the coeliac, superior mesenteric and inferior mesenteric arteries. The foregut extends from the oesophagus to the entrance of the common bile duct into the second part of the duodenum. The midgut extends down to two-thirds of the way along the transverse colon. And the hindgut extends down to include the upper half of the anal canal.

The enterocutaneous fistula is an abnormal connection between one part of elementary tract from the lower third of the esophagus to the ano-rectal junction and the skin can occur as a result of most commonly follows a surgical complication of leak from an anastomosis or suturing, abdominal trauma or an inadvertent enterotomy during dissection or after radiotherapy to the abdomen. The frequency of this complication has been shown to increase with the number of previous laparotomies. Until recently the morbidity and mortality from enterocutaneous fistula were high. The classic papers of Edmunds and colleagues [1]. And Chapman and his co-workers [2]. As a result of surgical intervention, though the increased ease of intravenous fluid replacement, the use of peri-operation antibiotics [3, 4]. And enteral [5, 6]. And parenteral nutritional support [6, 7]. Have brought about reduction in mortality rates in some series, figures of over 20 percent [8]. Post-operative oesophageal fistula can result from surgical resection of tumour or repair of tracheo-oesophageal fistula. Gastric fistula can result from surgical removal of gastric tumour or surgical procedure for gastric ulcer. Post operative duodenal fistula can

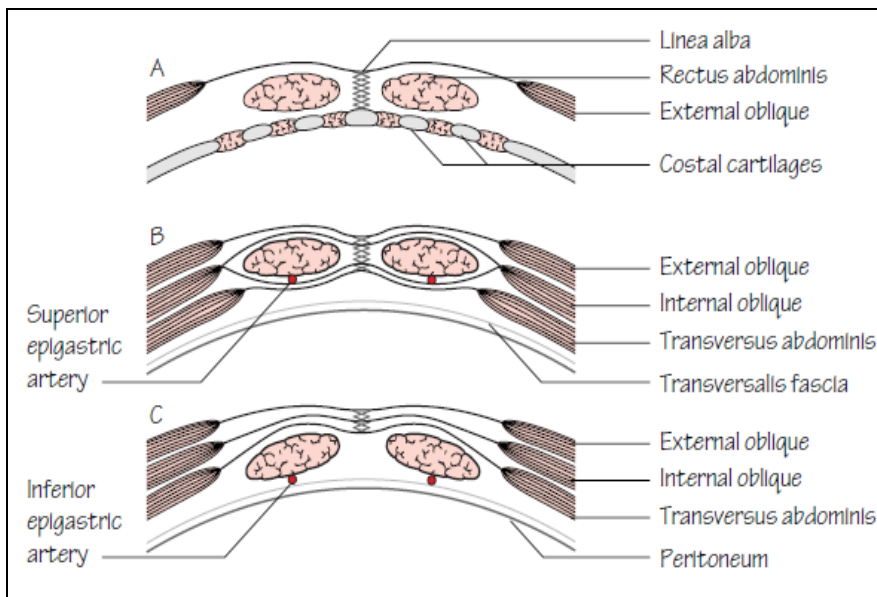
**Correspondence**  
**Dr. Jamal K AL-Qaysi**  
Department of Surgery, College of  
Medicine, AL- Iraqia University,  
Iraq

result from repair of perforated Duodenal Ulcer, or following transduodenal removal of biliary stone impacted at the Ampulla

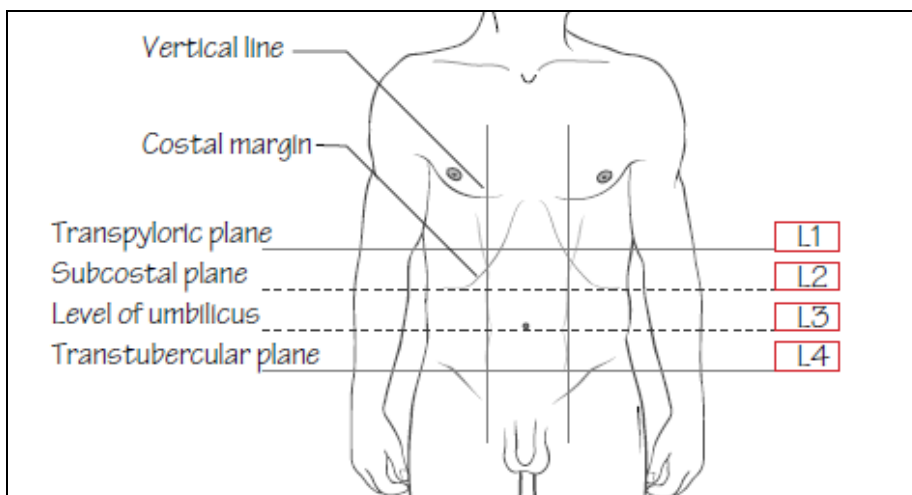
of Vater. Post operation bowel fistula usually follows the breakdown of an anastomosis of many diseases.



**Fig 1:** The vertical section of the abdominal wall



**Fig 2:** The transverse section of the abdominal wall.



**Fig 3:** The surface anatomy of the abdomen.

**Patients and Methods:** Twenty two patients with external enterocutaneous fistula arising at different levels of gastrointestinal tract following surgical intervention to treat certain pathologic conditions, were studied and analyzed in Baghdad medical city and Al- Ramadi general hospital from November 1994 to April 1998. The following table show the sex, location and primary pathology and surgery from which fistula were developed.

**Results:** Table (1) shows age and sex distributions, and Table (2) shows the Location and primary pathology and surgery from which fistula were developed.

**Table 1:** Shows age and sex distributions

Age	No. of patients	Percentage
0-9	0	0%
10-19	2	9%
20-29	4	18%
30-39	6	27%
40-49	5	22.5%
50-59	5	22.5%
<b>Sex:</b> 90% were male and 10% were female		

**Table 2:** Location and primary pathology and surgery from which fistula were developed

Fistula location	No. of patient	Primary disease	Surgery from which fistula developed
Oesophageal	1	Oesophago-gastric tumour	Total gastrectomy Roux in Y oesophago jujenostomy
Gastric	1	Gastric polyp	Open gastric - polypectomy
Duodenal	2	Choledocholithiasis	Transduodenal sphincterotomy
	1	Perforated DU	Closure of perforation
	1	Erosive bleeding Gastritis	Sub total gastrectomy Gastro-jujenostomy
Small bowel	2	Bullet injury	Resection & anastomosis
	2	Stab injury	Resection & anastomosis
	1	Acute abdomen (gangrenous bowel)	Resection & anastomosis
	2	Intestinal obstruction. Post- appendicectomy	Fibrinolysis
Colon	2	Stab injury (resection and anastomosis)	Closure of colostomy
	3	Bullet injury (resection and anastomosis)	Closure of colostomy
	2	Carcinoma colon (resection and anastomosis)	Closure of colostomy
	1	Gangrenous perforated appendix	Appendicectomy
	1	Obstructed paraumbilical hernia	Herniotomy- herniorrhaphy

## Discussion

Management of patients with enterocutaneous fistulae can be very challenging, especially when the fistula output is high (Usually defined as >500 mL of effluent/day). The majority of fistulae can be expected to heal spontaneously, provided there is no distal obstruction or disease at the fistula site. Reasons for failure of spontaneous healing also include epithelial continuity between the gut and the skin and an associated complex abscess. In 13 out of 22 patients (53 percent) with postoperative enterocutaneous fistula conservative treatment was successful, in 6 patients the fistula failed to close and operation was necessary. Three of these patients eventually died of septic complications. In one patient. The fistula persisted. Six patients died and mortality was (22.2%).

**1-Oesophageal fistulae:** One case of oesophageal Fistula was developed after removal of lower 5 cm of oesophagus and upper 1/3 of stomach for oesophago-gastric tumour It was presented at the 5<sup>th</sup>, post- operative day, diagnosis by swallowing water soluble dye. Management: conservatively.

**Result:** Patient died of speticemia at the 20<sup>th</sup>, Post- operative day.

**2-Gastric fistula:-**One case of gastric fistula appeared following gastric polypectomy patient already have had partial gastrectomy (Bilroth II) operation. It was presented at the 5<sup>th</sup>. Post- operative day and diagnosis made by Ba- meal & follow through. Management conservatively.

**Result:** Patient died at 16<sup>th</sup>.Post- operative day from septicemia.

**3-Duodenal fistula:-**Two cases of duodenal fistula occurred following trans-duodenal sphincterotomy for removal of

impacted stone at Ampulla of Vater. Day of presentation: 12<sup>th</sup> Post-operative day, diagnosis:- by Ba- meal & follow- through, Management: conservatively.

**Result:** one fistula closed by 28<sup>th</sup>. Post-operative day. The other closed by 30<sup>th</sup> post- operative day. Third case of duodenal fistula occurred after repair of perforated DU. Day of presentation: Tube drain continue to drain fluid. Diagnosis, Barium- meal & follow through, management, conservatively.

**Result:** fistula closed by 10<sup>th</sup> post- operative day. The 4<sup>th</sup> Case of duodenal blow out result after total gastrectomy and Bilroth II gastro-Jujenostomy for massive uncontrolled bleeding erosive gastritis. Day of presentation: 3<sup>rd</sup> post- operative day, diagnosis: Drain continue to drain bloody fluid, management conservatively.

**Result:** Patient died at 18<sup>th</sup> post- operative day from septicemia.

**4-Small intestinal fistula:** Seven cases of small bowel fistula occurred after the following operation. Four cases after resection and end to end anastomosis for stab wound and bullet Injury, Three cases presented with intestinal obstruction due to previous pathology, perforated gangrenous, appendicitis, acute abdomen with gangrenous bowel, day of presentation: fistulae developed between 4- 10 post- operative day. Diagnosis: Clinical finding and Ba- meal & follow through, management. Four cases with traumatic injury closed spontaneously on conservative treatment by 12, 10, 21, 27<sup>th</sup>. Respectively, three cases operated upon as there were distal obstruction, two cases nothing could be done as there were multiple fistulae and matting of intestine.

**Result:** one patient died of septicemia. Other patients developed recurrent fistula.

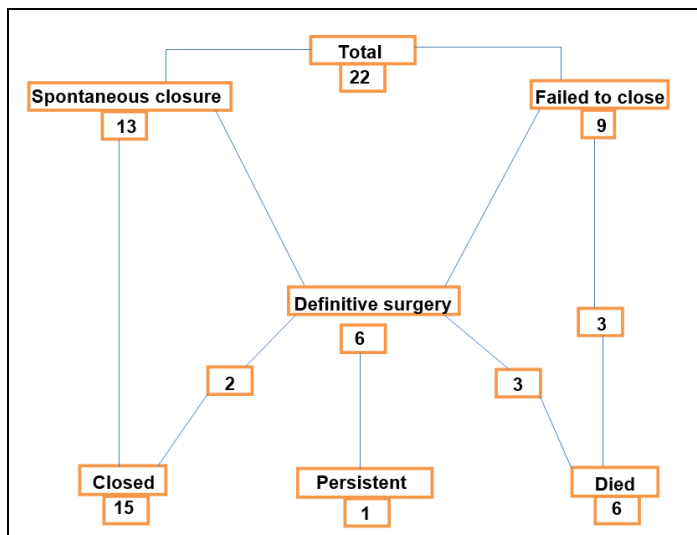
**5-Colonic fistula:-**Nine cases of large bowel fistula occurred after the following surgery. Five cases following closure of colostomy for traumatic bullet and stab wound, two cases following resection and end to end anastomosis for carcinoma of colon after closure of colostomy, one case following obstructed paraumbilical hernia, herniotomy and herniorrhaphy were done, day of presentation: Between 3-8 post-operative days, Diagnosis: fistulogram, treatment: five case of traumatic injury closed spontaneously after 14-25<sup>th</sup> post-operative day. Two cases managed by defunctioning transverse colostomy, one case treat by Fistulectomy after good pre-operative preparation, one case operated upon as there were multiple fistula and matting of whole bowel.

**Result:** Two cases managed by defunctioning colostomy died, one case with multiple fistula died.

#### Overall results

- The overall spontaneous closure rate of surgically created intestinal tract fistula were 13 cases out of 22 cases (53%).
- Direct surgical closure corrected an additional 2 cases (9%) of fistula, this producing an overall closure rate of 15 cases (68%).
- 6 cases were died, 3 cases of them died before the operation from intra-abdominal abscesses & the other 3 cases died post-operatively from septicemia.
- One case with recurrence of fistula post- operatively.

#### Summary of the result of presentation



Our results with intravenous hyperalimentation totally agree with those reported from north America<sup>[11, 12]</sup>, in a report from Philadelphia and honstin (Macfodyen) *et al.* 1973<sup>[13]</sup>, there were 6 duodenal fistulae closed spontaneously in about 20- 33 days, similar to our study. Poor results from definitive surgery of such fistulae deserve attention. Although simple, most authorities point out that it is rare for a fistula to remain closed if the opening in the bowel is simply sutured, which was the technique used in 3 of our patients. Ideally the segment of bowel containing the fistula opening should be excised (as was done in 3 cases) and a careful end to end anastomosis should be performed. Regarding nutrition, although most authorities now agree that adequate nutrition is the cornerstone of therapy in patients with fistulae, we have not used elemental diets, as advised by Bury *et al* (1972)<sup>[12]</sup> preferring to use intravenous

hyperalimentation. In his patients, most of whom had a high output fistula. Our results show that this treatment is safe. Elemental diets is particularly appropriate and is probably the nutritional therapy of choice in all low output fistulae the other controversial point is to decide when conservative treatment should end and surgery be performed. For instance, Fischer (1975)<sup>[14]</sup> advised surgery at a much earlier stage than Macfadyen *et al*<sup>[13]</sup>. Our study suggests that the principles outlined by Cameron (1977)<sup>[15]</sup> are sound and well worth following He suggested that in the early stages, soon after the fistula was developed intra-abdominal abscesses must be drained, but no attempt at definitive surgery should be made because of the risk of damaging more bowel is high. Later after 4-6 weeks or so, when it is evident that no progress is being made on conservative therapy, radiological evaluation (Fistulography and small bowel meal & follow through or enema) is required to search for factors that could be responsible for the persistent fistulous drainage, lack of bowel continuity, a large adjacent abscess cavity, persistent or recurrent inflammatory bowel disease and the presence of distal obstruction are all absolute indications for definitive surgery. The correct time for this delayed surgery is 5-6 weeks after the fistula has first developed. Surgery undertaken at an earlier time is likely to be quit difficult and the surgery will cause further fistula formation.

#### Conclusion

The adjuvant use of intravenous nutrition and complete bowel rest in the management of entero-cutaneous fistula, markedly decrease the morbidity and mortality rate<sup>[6-8, 10]</sup>. It must be emphasized that in the successful management of patients with entero-cutaneous fistula, some basic principles of therapy must be observed like distal bowel obstruction, the presence of a foreign body and Intra-abdominal Infection must be controlled<sup>[4]</sup>. In this series, 100% of entero-cutaneous fistula were secondary to operative complications. Several studies<sup>[14, 15]</sup> have emphasized the importance of early operative closure of entero-cutaneous tract fistula, in order to reduce the morbidity and mortality rate and to obtain optimal results. However 70% of patients were referred cases from other provincial hospitals were tired & malnourished and early operative intervention in the presence of malnutrition is not advisable and may be detrimental, even if the regimen of bowel rest and intravenous hyperalimentation does not lead to successful spontaneous fistula closure. The patient is generally in better nutritional & metabolic condition to withstand operative procedure. Fistula formation is an avoidable complication being most commonly due to technical error in anastomosis, improper pre-operative bowel preparation including or trapping the bowel by stitching during closure of abdomen during laparotomies.

#### References

1. Edmunds LH, Williams GM, Welch CC. External fistula arising from the gastro-intestinal tract. *Ann surg.* 1960, 445-71.
2. Chapman R, Foran R, Dunphy JE. Management of intestinal fistula. *Ann J surg.* 1964; 17-157-64.
3. Soeters PB, Ebid AM, Fischer JE. Review of 404 patients with gastro intestinal fistula; impact of parenteral feeding. 1974: 190:189-202.
4. Antibiotic's in colonic surgery in preventing complication in management of external cutaneous fistula. *S J. Ann R. coil sury Engl.* 1990; 729(3):163-4.
5. Blackett RL, Hill GL. Post operative external small bowel fistula a study of consecutive series of patients treated with

- intravenous hyperalimentation Br J surg. 1978; 6(65):755.
6. Thomas RJS, Rosalio R. The use of parenteral nutrition in the management of external gastro intestinal fistulae Surg. 1987; 48:535-9.
  7. Siges-sera A, Jaurrieta E, Sitges-creus A. Management of post-operative enterocutaneous fistulas: the roles of parenteral nutrition and surgery Br J. surg. 1982; 69:147-50
  8. Thomas RJS. The response of patient with fistula of the gastro intestinal tract to parenteral nutrition gynecol. 1981; 153:77-81.
  9. Irving M, Beadle C. External intestinal fistula: nursing and surgical procedures. Clin Gastrointestinal. 1982; 11:32-36
  10. Blackett RL, Hill GL. Post-operative external bowel fistulas? - A study of a consecutive series of patients treated with intra- Venous hyperalimentation. Br. J. surg. 1978; 6:775-778.
  11. Aguire A, Fischer E, Welch. The role of surgery and hyperalimentation in therapy of gastro-intestinal cutaneous fistulae Ann. surg. 1974; 180:393-401.
  12. Bury KD, Stephens RV, Randall HT. Use of achemically defined liquid elemental diet, for nutritional management of fistulae of the elementary tract Am. J. surg. 1971; 121:174-183.
  13. Macfadyen B, Vdudrck SJ, Aruberg RL. Management of gastrointestinal fistula with parenteral hyperalimentation. Surgery. 1973; 74:100-105.
  14. Fisher JE. The management of high output intestinal fistulas. Advances in surgery. Chicago year book, 1975, 9
  15. Cameron A. treatment of external small intestinal fistulas operative surgery, 3<sup>rd</sup>. ed London Butterworths. 1977, 467-475.