



International Journal of Surgery Science

E-ISSN: 2616-3470
P-ISSN: 2616-3462
© Surgery Science
www.surgeryscience.com
2019; 3(3): 349-351
Received: 19-05-2019
Accepted: 21-06-2019

Dr. Ajay Kumar
Associate Professor in General
Surgery, Rajshree Medical
Research Institute, Bareilly,
Uttar Pradesh, India

Assessment of efficacy of critical view of safety (CVS) in laparoscopic cholecystectomy in avoiding the occurrence of bile duct injury

Dr. Ajay Kumar

DOI: <https://doi.org/10.33545/surgery.2019.v3.i3f.193>

Abstract

Background: Diseases of the gallbladder commonly manifest as gallstones, gallbladder inflammatory conditions and gallbladder cancer. Cholecystectomy has been gold standard surgical treatment of Cholelithiasis and cholecystitis. The critical view of safety (CVS) is a method of target identification, the targets being the cystic duct and the cystic artery. Hence; the present study was undertaken for assessing the efficacy of critical view of safety in laparoscopic cholecystectomy in avoiding the occurrence of bile duct injury.

Materials & methods: A total of 75 consecutive patients of gallbladder disease were included in the study. Complete demographic details of all the patients were obtained. Hematological and biochemical profile of all the patients was done preoperatively. All the procedures were performed under the hands of skilled and experienced surgeons. Post-operative assessment of all the patients was done.

Results: Aberrant anatomy was found to be present in 2 patients, where as it was absent in 73 patients. Critical view of safety was achieved in 100 percent of the patients of the present study. Aberrant anatomy was encountered only in two cases. Those cases were converted into open cholecystectomy.

Conclusion: Critical view of safety method of ductal identification is an effective technique.

Keywords: Critical view of safety, laparoscopic cholecystectomy

Introduction

Diseases of the gallbladder commonly manifest as gallstones, gallbladder inflammatory conditions and gallbladder cancer. Cholecystectomy has been gold standard surgical treatment of Cholelithiasis and cholecystitis. The gallbladder should be removed not because it contains stones but it forms them. Laparoscopic surgery has induced a tremendous revolution in the treatment of gallbladder disease ^[1-3]. Open cholecystectomy which had been performed unchallenged for over a century, faced an abrupt end with advent of laparoscopic cholecystectomy. Open surgical removal had been traditionally considered the last therapeutic resort for symptomatic Cholelithiasis before the advent of laparoscopy, whereas lithotripsy and cholecystectomy had been commonly favoured as less invasive alternatives ^[4]. The laparoscopic procedure has been shown to offer the advantage of decreased pain, shorter convalescence, reduced operative stress and limited inflammatory response. Bile duct injury usually manifest either as biliary leak or biliary obstruction. Over the past few decades, surgeons have spent considerable amount of time developing a safe way of Calot's triangle dissection and cystic duct identification. The critical view of safety (CVS) is a method of target identification, the targets being the cystic duct and the cystic artery ^[5, 6]. Hence; the present study was undertaken for assessing the efficacy of critical view of safety in laparoscopic cholecystectomy in avoiding the occurrence of bile duct injury.

Materials & methods

The present study was conducted in the department of general surgery of Rajshree Medical Research Institute, Bareilly, Uttar Pradesh. It included assessment of efficacy of achieving of critical view of safety in laparoscopic cholecystectomy in avoiding the occurrence of bile duct injury. A total of 75 consecutive patients of gallbladder disease were included in the study. Exclusion criteria for the present study included:

- Pregnant subjects

Correspondence
Dr. Ajay Kumar
Associate Professor in General
Surgery, Rajshree Medical
Research Institute, Bareilly,
Uttar Pradesh, India

- Patients with bleeding disorder
- Patients with cirrhosis with portal hypertension
- Patients with generalized peritonitis

Complete demographic details of all the patients were obtained. Hematological and biochemical profile of all the patients was done preoperatively. All the patients were subjected to laparoscopic cholecystectomy. All the procedures were performed under the hands of skilled and experienced surgeons. Post-operative assessment of all the patients was done. All the results were assessed by SPSS Software. Chi- square test and Mann-Whitney U test were used for assessment of level of significance. P- value of less than 0.05 was taken as significant.

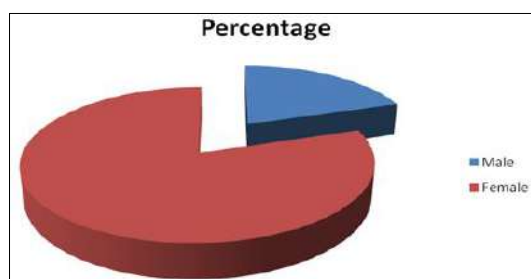
Results

50 percent of the patients belonged to the age group of 30 to 50 years. Mean age of the patients of the present study was 48.6 years. 80 percent of the patients of the present study were females, while the remaining 20 percent were males. Pain was the most common clinical symptom encountered in patients in the present study found to be present in 100 percent of the patients. Dyspepsia and vomiting were the next in number found to be present in 46.67 percent and 5.33 percent of the patients. Aberrant anatomy was found to be present in 2 patients, where as it was absent in 73 patients. Spillage was found to be present in 25.33 percent of the patients, while it was absent in 74.67 percent of the patients. Critical view of safety was achieved in 100 percent of the patients of the present study. Aberrant anatomy was encountered only in two cases. Those cases were converted into open cholecystectomy. Mean duration of procedure in the present study was 59.45 minutes.

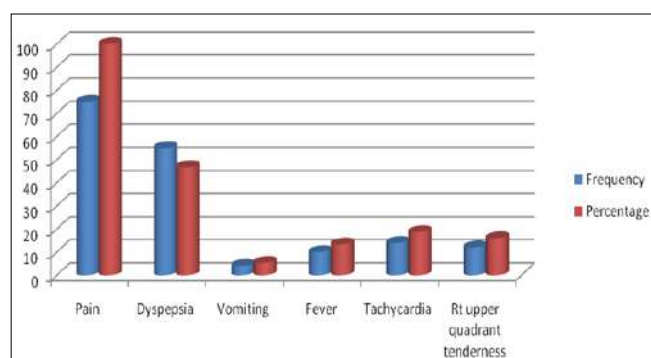
Table 1: Distribution of subjects according to age group

| Age-group (years) | Frequency | Percentage |
|-------------------|-----------|------------|
| Less than 30 | 23 | 30.67 |
| 30- 50 | 39 | 50 |
| More than 50 | 13 | 17.33 |
| Total | 75 | 100 |

Mean age (years) \pm SD= 48.6 years \pm 14.2



Graph 1: Gender distribution of subjects



Graph 2: Distribution of clinical manifestations

Table 2: Distribution of patients according to aberrant anatomy

| Aberrant anatomy | Frequency | Percentage |
|------------------|-----------|------------|
| Yes | 2 | 2.67 |
| No | 73 | 97.33 |
| Total | 75 | 100 |

Table 3: Distribution of patients according to presence of spillage

| Spillage | Frequency | Percentage |
|----------|-----------|------------|
| Present | 19 | 25.33 |
| Absent | 56 | 74.67 |
| Total | 75 | 100 |

Table 4: Achievement of Critical View of safety

| Critical view of safety | Frequency | Percentage |
|-------------------------|-----------|------------|
| Achieved | 75 | 100 |
| Total | 75 | 100 |

Table 5: Number of cases converted to open cholecystectomy

| Parameter | Frequency | Percentage |
|--|-----------|------------|
| No. of cases converted to open cholecystectomy | 2 | 2.67 |

Table 6: Duration of procedure

| Duration of procedure | Value |
|-----------------------|-------|
| Mean (minutes) | 59.45 |
| SD (minutes) | 10.48 |

Discussion

Critical view of safety has three requirements. First, calot's triangle must be cleared of fat and fibrous tissue both on its dorsal and ventral aspects. It does not require the exposure of common bile duct. The second requirement is that the lowest part of gallbladder is to be separated from the cystic plate. The third requirement is that two structures and only two should be seen entering the gallbladder. Once the criteria has fulfilled, critical view of safety has been achieved [7-9]. Hence; the present study was undertaken for assessing the efficacy of achieving of critical view of safety in laparoscopic cholecystectomy in avoiding the occurrence of bile duct injury.

In the present study, 50 percent of the patients belonged to the age group of 30 to 50 years. Mean age of the patients of the present study was 48.6 years. 80 percent of the patients of the present study were females, while the remaining 20 percent were males. Pain was the most common clinical symptom encountered in patients in the present study found to be present in 100 percent of the patients. Dyspepsia and vomiting were the next in number found to be present in 46.67 percent and 5.33 percent of the patients. Aberrant anatomy was found to be present in 2 patients, where as it was absent in 73 patients. Singh K *et al.* assessed the frequency and the relevance of anatomical variations of extra hepatic biliary system in patients undergoing LC. The study included 740 patients of cholelithiasis undergoing routine LC performed by a single surgeon by achieving a critical view of safety. During dissection, vascular and ductal anomalies were noted and assessed for their relevance in LC. Operative findings revealed 197 (26.62%) vascular anomalies and 90 (12.16%) ductal anomalies. Vascular anomalies are more frequent than the ductal anomalies, and surgeon should be alert regarding their presence [10].

In the present study, spillage was found to be present in 25.33 percent of the patients, while it was absent in 74.67 percent of the patients. Critical view of safety was achieved in 100 percent of the patients of the present study. Aberrant anatomy was

encountered only in two cases. Those cases were converted into open cholecystectomy. Mean duration of procedure in the present study was 59.45 minutes. Singh R *et al.* undertook a prospective study in 1340 patients having two groups, Group-A (CVS-700 patients) and Group-B (Infundibular technique -640 pts). CVS was achieved in 98.1% of pts and there was no conversion, bile leak and BDI (group-A). Where as in Group-B-32 conversion, 5 BDIs occurred and out of which 3 were major BDIs. The operating time taken in Group-A (90-110minutes) was significantly higher than group-B (60-80 minutes). They concluded that the results of this study leave no doubt of CVS being safe, feasible and superior to infundibular technique in preventing BDI ^[11]. Zarin M *et al.* assessed whether CVS technique is faster and safer compared to conventional infundibular technique. Total of 438 patients were divided into two groups. Group-A in which LC was done using infundibular technique while Group-B with CVS technique. Two groups were compared for operating time and BDI. The operative time was significantly reduced for LC using CVS technique (50 mints vs. 73 mints). Minor leaks were comparable but there was a significant difference in major leak between the two techniques. Although the “critical view of safety” requires more dissection as compared to infundibular technique, but once learnt and mastered, it is faster and safer identification technique during laparoscopic cholecystectomy ^[12].

Conclusion

From the above results, the authors conclude that the critical view of safety method of ductal identification is an effective technique. However; further studies are recommended.

References

1. Litynski GS. Highlights in the History of Laparoscopy. Frankfurt, Germany: Barbara Bernert Verlag, 1996, 165-168.
2. Glenn F. Trends in surgical treatment of calculus disease of biliary tract. Surg Gynecol Obstet. 1975; 140:877-84.
3. Antoniou SA, Antoniou GA, Koch OO, Pointner R, Granderath FA. Meta-analysis of laparoscopic vs open cholecystectomy in elderly patients. World J Gastroenterol. 2014; 20(46):17626-34.
4. Archer SB, Brown DW, Smith CD, Branum GD, Hunter JG. Bile duct injury during laparoscopic cholecystectomy: results of a national survey. Ann surg. 2001; 234:549-58.
5. Jabłońska B, Lampe P. Iatrogenic bile duct injuries: etiology, diagnosis and management. World J Gastroenterol. 2009; 15(33):4097-104.
6. Strasberg SM1, Brunt LM. Rationale and use of the critical view of safety in laparoscopic cholecystectomy. J Am Coll Surg. 2010; 211(1):132-8.
7. Heistermann HP1, Tobusch A, Palmes D. Prevention of bile duct injuries after laparoscopic cholecystectomy. The critical view of safety. Zentralbl Chir. 2006; 131(6):460-5.
8. Yegiyants S1, Collins JC. Operative strategy can reduce the incidence of major bile duct injury in laparoscopic cholecystectomy. Am Surg. 2008; 74(10):985-7.
9. Giménez ME, Houghton EJ, Zeledón ME, Palermo M, Acquafresca P, Finger C *et al.* The critical view of safety prevents the appearance of biliary injuries? Analysis of a survey. ABCD, Arq. Bras. Cir. dig. 2018; 31(2):e1380.
10. Singh K, Singh R, Kaur M. Clinical reappraisal of vasculobiliary anatomy relevant to laparoscopic cholecystectomy. J Min Access Surg. 2017; 13:273-9.
11. Singh R, Brunt LM. Critical view of safety (CVS) prevents

bile duct injury: is it a myth or reality? J Gastrointest Dig Syst. 2018; 8:58.

12. Zarin M, Khan MA, Khan MA, Shah SAM. Critical view of safety faster and safer technique during laparoscopic cholecystectomy? Pakistan Journal of Medical Sciences. 2018; 34(3):5074-577.