



International Journal of Surgery Science

E-ISSN: 2616-3470
P-ISSN: 2616-3462
© Surgery Science
www.surgeryscience.com
2017; 1(1): 07-09
Received: 04-10-2017
Accepted: 05-11-2017

Ashish Kumar
MCh, Post Graduate,
Department of Urology RIMS,
Imphal, Manipur, India

KH Somarendra
Registrar, Department of Urology,
RIMS, Imphal, Manipur, India

S Rajendra Singh
Professor, Department of Urology
RIMS, Imphal, Manipur, India

Penile strangulation by metallic ring: A case report

Ashish Kumar, KH Somarendra and S Rajendra Singh

Abstract

Penile strangulation is an urological emergency. It occurs whenever any constricting object is placed for erotic or auto-erotic purposes or to intensify sexual performance. Any delay in management might lead to reduced blood flow leading to edema and irreversible ischaemia of the penile tissue and sometimes, gangrene. Here, we report a case who presented to emergency with acute urinary retention and penile swelling secondary to metallic ring strangulation of penis. Patient was taken to operation room to release the ring. But safe decompression of the penis can be very challenging as in our case where the strangulating object is a hard metal ring. Early release of the strangulation helps to preserve the urethral and erectile function.

Keywords: Penile strangulation, metallic nut, decompression, vascular obstruction

Introduction

An attempt to maintain a prolonged erection in order to improve sexual performance is typically associated with penile strangulation. It is a rare condition but an urgent intervention is obligatory. There are various objects which are reported to be usually used by adults and adolescents for penile entrapments. These can be metallic or nonmetallic in nature. Objects such as rubber bands, hair, or thread are reported to be the offending objects in paediatric age groups [1]. The offending metallic objects include nuts, washers, wedding rings, ball bearings, steel rings etc [2, 3]. If such patients with strangulating objects are not managed in due course of time, it may result in the development of a penile compartment syndrome. The severity of vascular obstruction may range from mild non-significant vascular obstruction which is completely recoverable on decompression to tissue ischaemia and penile necrosis [4].

There is no implicit instructions for the removal of such objects due to their varied nature in terms of metallic or nonmetallic, different shapes and sizes [5] but an urgent intervention is required to avoid penile skin loss, erectile dysfunction, urethrocutaneous fistula and ultimately penile loss.

Case report

A forty year old male presented at the surgical emergency RIMS, Imphal with a 0.8 cm wide by 0.3 cm thick metallic ring around the penis fixed at the peno-scrotal junction. The patient had put the ring 20 hours prior to presentation. The patient reported a normal erectile function prior to the incident. Patient rolled over a metallic ring over the penile shaft while he was under the effect of alcohol in order to increase sexual pleasure.

Patient noticed a swelling of the penile shaft and the glans penis distal to the ring approximately eight hours after the application of the ring. An attempt to remove the ring by the patient was unsuccessful. There was no previous history of cock ring usage to enhance sexual performance. He had no co-morbidities and had no prior history of any mental illness.

The patient appeared to be calm on examination, though he complained of pain. General physical assessment was normal with a clear mental state. Examination of the genitalia revealed a edematous and swollen penis with a strangulating ring fixed tightly at the peno-scrotal junction. (Image 1).

The patient was taken up for removal of the strangulating ring in emergency OT. The problem was how to cut the 0.8 cm by 0.3 cm thick and tightly fitting metallic ring. The procedure was done under spinal anaesthesia. The ring was cut at two places (Image 3) using a K - wire cutter (Image 2) and was removed safely with no injury to the penis.

After the completion of the procedure, the patient was catheterized per urethra. The patient was discharged 2nd post operative day in stable condition after the removal of catheter.

Correspondence
Ashish Kumar
MCh, Post Graduate,
Department of Urology RIMS,
Imphal, Manipur, India

The patient was followed up in OPD after 7 days. A complete resolution of edema was observed. The patient reported a normal erectile function.

Discussion

The penis is a very sensitive and delicate organ. Even a minor injury may cause serious discomforts. Any trauma to the penis needs urgent intervention [6].

The very first case of penile strangulation was reported in 1755 [4]. The largest series of cases were reported in 1948 by Dakin [7].

The offending agents in pediatric and adult age groups reported in literature are very different. The most common strangulating objects in children are found to be hair tourniquets whereas in adults, metallic and non-metallic objects are often found to be the cause for self-strangulation of penis. The cases range from adolescents from the age of 13 years to geriatric cases upto 81 years of age [8, 9].

Penile strangulation can result in severe consequences depending upon extent of vascular obstruction with mild vascular compromise that is reversible on decompression to severe gangrene of the penis and even may cause renal impairment [4]. There can be edema, maceration, or local infections complicating to Fournier gangrene or necrosis of the penile tissue which may even extend to involve the urethra [10]. Fibrosis of the penile shaft and erectile dysfunction are seen as late complications in few cases. Huang *et al.* found deterioration of renal function as one of the complications [11].

According to severity, Bhat Al *et al.* (1991) has graded such injuries as [12].

Grade I: Distal penile edema with no evidence of skin ulceration or any injury to urethra.

Grade II: Distal penile edema with injury to skin and constriction of corpus spongiosum. No urethral injury. Decreased penile sensation.

Grade III: Injury to skin and urethra but no urethral fistula. Loss of distal penile sensation.

Grade IV: Complete division of corpus spongiosum leading to urethral fistula and constriction of corpus cavernosa with loss of distal penile sensation.

Grade V: Gangrene, necrosis, or complete amputation of distal penis.

The cases presenting after 72 hours or more, are more likely to sustain higher-grade injuries.¹³ The duration of hospital stay is directly proportional to the time of incarceration as observed by Xu T *et al.* [14].

The management of such cases can be challenging depending on the object used for entrapment and injury caused by it. The nonmetallic objects can be cut off easily, but a thick and hard steel or iron ring is very challenging to remove with a saw, drill or a chisel. Cutting metal using drills produces a lot of heat. The metal needs to be cooled in order avoid tissue heating. Simultaneously, the metal must be cut at multiple sites in order to prevent any injury to the penile skin during removal [3]. In our case, we have used a K wire cutter which has rarely been reported to be used in the management of such cases.

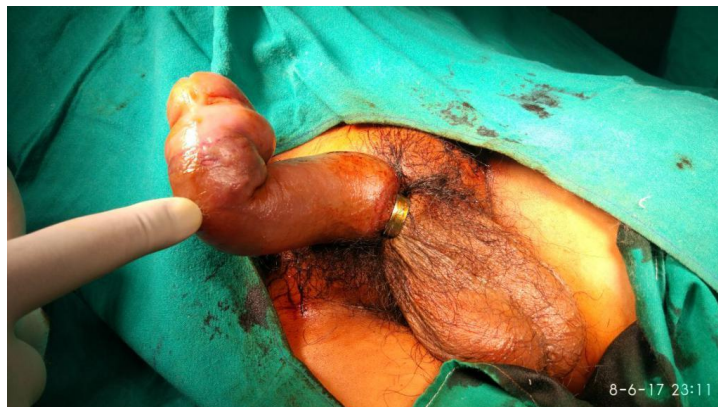


Image 1: Strangulating ring fixed at the peno-scrotal junction

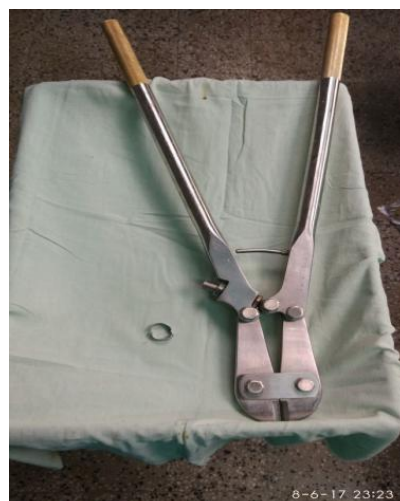

Image 2: K wire cutter



Image 3: Ring cut at two places for safe removal

Conclusion

Strangulation of the penis is a rare clinical emergency but may result in severe consequences. Therefore immediate attention, quick diagnosis and instant treatment are essential. With apt intervention and removal of the offending object, most of the patients do extremely well with no need for any further intervention. Removal of the offending devices can be extremely challenging. The management of such cases demand a skillful use of instruments, inventiveness and an integrative approach. However, the use of K wire cutter is simple, safe, cost effective and hence a novel option in the management of penile strangulation.

References

1. Noh J, Kang TW, Heo T, Kwon DD, Park K, Ryu SB. Penile strangulation treated with the modified string method. *Urology*. 2004; 64:591.
2. Patel C, Kim R, Delterzo M, Wang R. Prolonged penile strangulation with metal clamps. *Asian J Androl*. 2006; 8:105-106.
3. Santucci RA, Deng D, Carney J. Removal of metal penile foreign body with a widely available emergency-medical-services air driven grinder. *J Urol*. 2004; 63:1183-1184.
4. Ivanovski O, Stankov O, Kuzmanoski M, Saidi S, Banev S, Filipovski V *et al*. Penile strangulation: Two case reports and review of the literature. *J Sex Med*. 2007; 4:1775-80.
5. Choudhary SK, Taraphdar T, Thomas AJ. Penile Strangulation with Metallic Objects in Adults: 2 Case Reports and Literature Review. *Emerg Med (Los Angel)*. 2014; 4:214. 10.4172/2165-7548.
6. Dubin J, Davis JE. Penile emergencies. *Emerg Med Clin North Am*, 2011; 29:485-99.
7. Baruah SJ, Bagchi PK, Barua SK, Deka PM. An innovative surgical technique for treating penile incarceration injury caused by heavy metallic ring. *Indian J Urol*. 2009; 25:267-268.
8. Raza K, Khadim MF, Naqvi GA, Ahmed I. Wedding ring in the wrong place: an unusual presentation of penile incarceration in a child with a wedding ring. *BMJ Case Rep*, 2009.
9. Okumura A, Tsuritani S, Muraishi Y, Sakamoto M, Kazama T *et al*. Strangulation of the penis by a metallic ring. *Hinyokika Kyo*. 1993; 39:1179-1181.
10. Nelius T1, Filleur S. Self-inflicted penile strangulation. *Aktuelle Urol*. 2010; 41:64-66.
11. Huang JK, Holt D, Philip T. Penile constriction by foreign bodies: The use of a dental drill. *Br J Urol*. 1997; 79:801.
12. Bhat AL, Kumar A, Mathur SC, Gangwal KC. Penile strangulation. *Br J Urol*. 1991; 68:618-21.
13. Silberstein J, Grabowski J, Lakin C, Goldstein I. Penile constriction devices: case report, review of the literature, and recommendations for extrication. *The Journal of Sexual Medicine*. 2008; 5:1747-57.
14. Xu T, Gu M, Wang H. Emergency management of penile strangulation: a case report and review of the Chinese literature. *Emergency Medicine Journal*. 2009; 26:73-4.