



E-ISSN: 2616-3470
P-ISSN: 2616-3462
© Surgery Science
www.surgeryscience.com
2020; 4(1): 17-21
Received: 13-11-2019
Accepted: 15-12-2019

Dr Sandesh Deolekar
Professor, Department of General
Surgery, DY Patil School of
Medicine, Nerul, Navi Mumbai,
Maharashtra, India

Dr Bibekananda Mahapatra
Associate Professor, Department of
General Surgery, DY Patil School
of Medicine, Nerul, Navi Mumbai,
Maharashtra, India

Dr Rahul Borude
Resident, Department of General
Surgery, DY Patil School of
Medicine, Nerul, Navi Mumbai,
Maharashtra, India

Corresponding Author:
Dr Bibekananda Mahapatra
Associate Professor, Department of
General Surgery, DY Patil School
of Medicine, Nerul, Navi Mumbai,
Maharashtra, India

The role of diagnostic laparoscopy in chronic abdominal pain

Dr. Sandesh Deolekar, Dr. Bibekananda Mahapatra and Dr. Rahul Borude

DOI: <https://doi.org/10.33545/surgery.2020.v4.i1.a.304>

Abstract

Background: Chronic abdominal pain (CAP) can be a diagnostic challenge inspite of being subjected to myriad of tests. The aim of this study was to assess the efficacy of laparoscopy in diagnosing patients having CAP of unknown origin and providing them best possible treatment.

Methods: We studied 50 patients having CAP for ≥ 3 mons, with unremarkable clinical examination & basic investigations and unyielding imaging studies to assess the overall efficacy of diagnostic laparoscopy in finding a cause of CAP and response to pain after 3 months of procedure.

Results: Highest incidence (32%) of CAP was seen in age group of 31-40 years. Pain relief was achieved in 92% cases post-laparoscopy. Most common observation on laparoscopy was abnormal appendix (30%), followed by abdominal tuberculosis (24%). 10% cases required conversion to open laparotomy. Laparoscopic diagnosis correlated with histopathological findings in 95.5% cases.

Conclusion: Diagnostic laparoscopy is a better, relatively cost-effective, and efficient method of establishing the diagnosis in patients with CAP.

Keywords: Diagnostic laparoscopy, chronic abdominal pain, cost-effective

Introduction

Chronic abdominal pain is defined as “intermittent or constant abdominal pain of at least 3 months duration”^[1]. It is one of the common presentations in general surgical practice. CAP can be a diagnostic challenge and inspite of being subjected to myriad of tests, almost 20-40% of patients remain undiagnosed at the end of it^[2]. Chronic abdominal conditions are associated with poor quality of life and significant levels of depressive symptoms^[2, 3]. The most common organic conditions associated with CAP include intestinal adhesions^[4], especially in patients with a past history of abdominal operations, abdominal tuberculosis^[5], appendicular pathology, biliary causes, mesenteric lymphadenopathy (which could also be due to infectious causes of bowel such as colitis, gastroenteritis or enteric fever apart from tuberculosis), and hernia; while the functional conditions include irritable bowel disease, functional dyspepsia, and various motility disorders. Abdominal wall pain is also common and frequently mistaken for visceral pain^[6].

Diagnostic laparoscopy (DL) is a minimally invasive surgery for diagnosis of intra-abdominal diseases. The present-day laparoscope allows unhindered visualization of every aspect of the abdominal cavity. It allows for performing every possible procedure, limited only by the skill, training and coordination of the laparoscopy surgical team^[7, 8].

In selected patients with chronic abdominal disorders, whose diagnosis remains uncertain despite exploring the requisite laboratory and imaging investigations like ultrasonography and CT scan, laparoscopy or minimally invasive exploration can prove to be an important tool^[9]. Laparoscopy offers a distinct advantage over ultrasound or CT scan as it is capable of detecting lesions <5 mm in size especially peritoneal metastasis, which cannot be detected by these investigations. Laparoscopy-guided biopsy provides a larger histopathological specimen as compared to percutaneous biopsy. It is more accurate than the radiologically-guided biopsy and can provide a diagnosis in 85%–95% of patients^[10]. It minimizes surgical trauma in chronically ill patients with chronic abdominal disorders, resulting in a better outcome and making shorter hospital stay possible. Diagnostic laparoscopy is now accepted as the preferred primary approach to many disease processes.

The present study concentrates on the fact that undiagnosed abdominal pathology is an important cause of morbidity and change in the patient's quality of life and longevity, which can be improved or restored to normalcy by diagnostic laparoscopy and effective postoperative care. This study was thus intended to determine the role of diagnostic laparoscopy in the diagnosis and management of non-specific pain in abdomen where other clinical symptoms and investigations are not conclusive.

Materials & Methods

This study was conducted in the Department of Surgery in a tertiary care hospital in Navi Mumbai over a period of 24 months in 50 patients of chronic abdominal pain with uncertain diagnosis after five weeks of onset of symptoms.

Patient Selection Criteria

Inclusion criteria

1. Patients who had history of abdominal pain for 3 months or more, of uncertain aetiology and conditions which were unexplained by other investigation and clinical symptoms.
2. Age group of 15-50 years
3. Both sexes were included.

Exclusion criteria

Age less than 15 years, pregnant women, oncological patients, coagulation defects, critical illness, patients medically unfit for surgery, severe/decompensated cardiopulmonary failure, acute myocardial infarction, bacterial peritonitis, abdominal wall infection, severe coagulopathy, large ventral hernia, diaphragmatic hernia, patients unfit for general anaesthesia.

Methodology

Detailed history was recorded from patients and thorough clinical examination was performed. The findings were recorded in the proforma. The recorded data included demographics, duration of pain, location of pain, patient's per abdominal examination findings and diagnostic studies performed. Routine haematological investigations viz. complete blood count, renal function tests and serum electrolytes were performed in all the patients along with urine routine and microscopy. Commonly performed imaging studies included plain abdominal radiography and ultrasound studies. Barium studies were done wherever indicated.

All the patients underwent diagnostic laparoscopy. Intra-operative findings and operative interventions undertaken were also recorded. Depending on the pathology, various surgical methods were employed. Outcome measured included the overall efficacy of diagnostic laparoscopy in finding a cause of chronic abdominal pain, diagnosis made, histopathological correlation, postoperative complications and response to pain after 3 months of procedure.

Statistical Analysis

The quantitative data was represented as their mean \pm SD while categorical data was expressed in numbers and percentage. All analysis was carried out by using SPSS software version 21.

Results

This study was conducted in 50 patients who had chronic abdominal pain. The most commonly affected age group in the study was 31- 40 years. Female predominance was seen, with 66% females to 34% males. All the cases had normal abdominal X-ray and ultrasonography reports.

Table 1: Age Incidence in Chronic Abdomen

Age Group (In years)	No. of Cases	Percentage (%)
≤ 20	4	8%
11-20	4	8%
21-30	12	24%
31-40	16	32%
41-50	11	22%
51-60	3	6%
Total	50	100%

From the above observations, it is clear that the maximum number of patients were of 31-40 years (16 of 50 patients, i.e. 32%). Least number of patients belonged to age group of more than 50 years (3 of 50 patients, i.e. 6%).

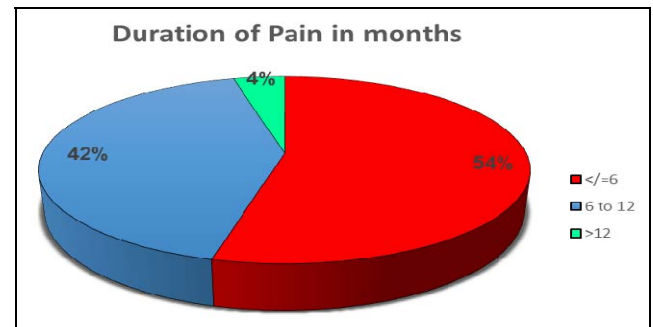


Fig 1: Duration of pain (in months)

Most of the cases (54%) had pain of less than 6 months duration while only 4% cases had been suffering from CAP for over a year.

Table 2: Distribution of cases as per site of pain

Site of Pain	N	%
All over abdomen	11	22.0
Epigastric pain	1	2.0
Left iliac Fossa	7	14.0
Left Hypochondrium	4	8.0
Hypogastrium	3	6.0
Peri-umbilical	2	4.0
Right iliac Fossa	61	12.0
Right Lumbar	4	28.0
Umbilicus	1	2.0
Right Hypochondrium	1	2.0
Total	50	100

Most common site of abdominal pain was right side of abdomen (40%) followed by diffuse pain all over the abdomen (22%).

Table 3: Distribution of cases as per laparoscopic findings

Laparoscopic findings	N	%
Abnormal appendix	15	30.0
Abdominal tuberculosis	12	24.0
Adhesions	5	10.0
Pelvic inflammatory disease	3	6.0
Mesenteric lymphadenopathy	2	4.0
Ovarian cyst	2	4.0
Cholecystitis	2	4.0
Femoral hernia	2	4.0
Diverticulosis (mekels)	1	2.0
Normal study	6	12.0
Total	50	100

Most common observation made on laparoscopy was abnormal appendix (30%) followed by abdominal tuberculosis (24%). Other pathologies observed were adhesions (10%), pelvic inflammatory disease (6%), mesenteric lymphadenopathy (4%), ovarian cyst (4%), cholecystitis (4%), inguinal hernia (4%), and Meckel's diverticulosis (2%). No findings were observed in 12% cases.

Table 4: Incidence of Various Pathologies in Chronic Abdomen

Pathology	No. of Cases	Percentages (%)
Appendicitis	15	30%
Abdominal Koch's	12	24%
Adhesive intestinal obstruction	5	10%
Pelvic inflammatory disease (PID)	3	6%
Ovarian cyst	2	4%
Meckel's diverticulum	1	2%
Mesenteric lymphadenopathy	2	4%
Cholecystitis	2	4%
Inguinal hernia	2	4%
Total	44	88%

Laparoscopy observed abnormal findings in 88% of the cases. In this study, the most common cause of chronic abdomen was appendicitis (30%), followed by abdominal tuberculosis (24%) and adhesive intestinal obstruction due to adhesions (10%). No obvious pathology was observed in 6 patients.

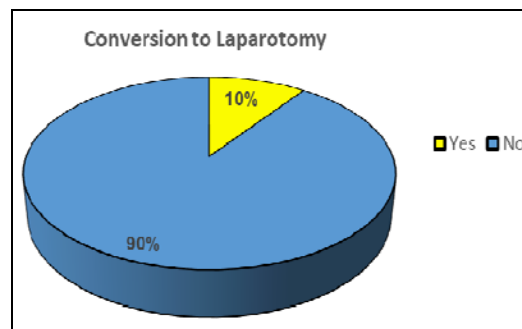


Fig 2: Conversion to open laparotomy

Conversion to open laparotomy was required in 10% cases for the following procedures: appendectomy, adhenolysis, cholecystectomy, resection anastomosis and open mesh repair.

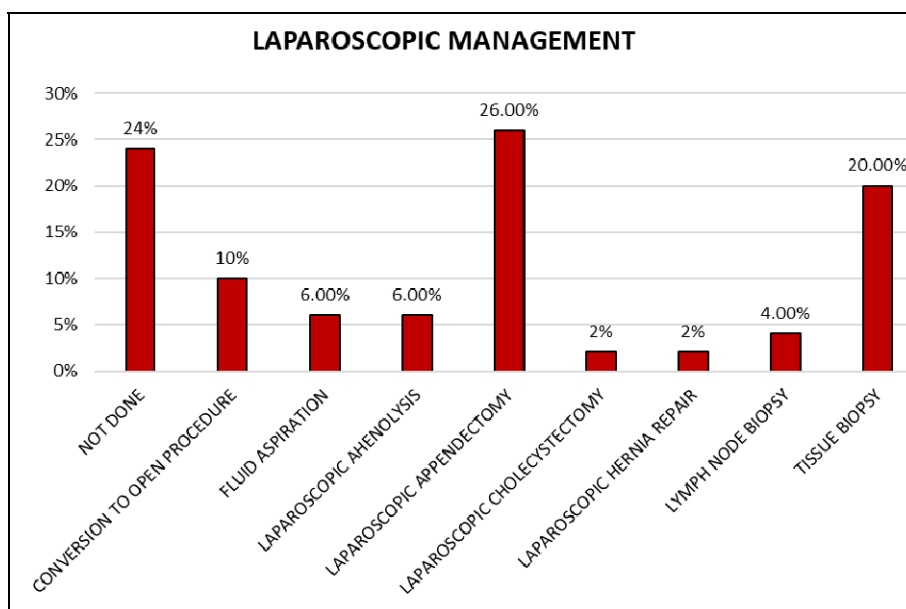


Fig 3: Distribution of cases as per Laparoscopic management

Laparoscopic management for respective pathologies was done in 42% patients and biopsy was taken in 24% cases. No procedure was required in 24% cases while 10% were converted to laparotomy.

Superficial surgical site infection was observed in 2 (4%) cases. No other complication was observed in any case.

Duration of hospital stay was 1- 3 days in 78% cases and 4-7 days in 18% cases, while the 2 (4%) cases which required conversion to open procedure required more than 7 days' hospital stay.

Post laparoscopy, pain was relieved in 92% cases, while there was persistence of CAP in 8% cases.

Discussion

Chronic abdominal conditions have been a challenge for the surgeon. Prior to the era of diagnostic laparoscopy, these patients used to undergo a battery of expensive investigations, while remaining dissatisfied. The search for pathology in these

patients usually entailed a series of laboratory and invasive tests. Diagnostic laparoscopy provides an intermediate option, avoiding full exploratory laparotomy and minimizing the surgical trauma in chronically ill patients.

The purpose of this study was to evaluate the role of laparoscopy as a major diagnostic tool in patients presenting with a chronic abdominal condition with uncertain diagnosis. It has been clearly observed that laparoscopy has a diagnostic rate of 95.5% in these patients. In our study, patients included were 15-50 years in age. We found that maximum patients of chronic abdomen belonged to age group of 31- 40 years, i.e. 16 out of 50 cases (32%). Mean age of the study cases was 32.45 years and female predominance was seen, with 66% females to 34% males. Prasad S *et al.*, in their study, observed the mean age of study population with CAP to be 30.18 years, with incidence being higher in males as compared to females (56 vs 44%) [11].

In the present study, the most common site of abdominal pain

was right side of abdomen (40%) followed by diffuse pain all over the abdomen (22%), which is similar to the finding in the study by Kumar *et al.* (37%), followed by diffuse pain (35%)^[12]. Most common location of pain in the study by Sayed *et al.* was right lower quadrant (34.5%) followed by diffuse pain (25.5%)^[13].

In our study, laparoscopy observed abnormal findings in 88% of the cases. Most common observation made on laparoscopy was abnormal appendix (30%) followed by abdominal tuberculosis (24%). Other pathologies observed were adhesions (10%), PID (6%), mesenteric lymphadenopathy (4%), ovarian cyst (4%), cholecystitis (4%), inguinal hernia (4%), and Meckel's diverticulosis (2%). No findings were observed in 12% cases. In the study by Sayed *et al.*, it was possible to achieve a definitive diagnosis in 89.1% patients and the most common diagnosis was adhesions due to previous abdominal surgery (43.6%), second most common cause of the chronic abdominal pain was abdominal tuberculosis diagnosed in 21.8% patients^[13].

In the study by Jadhav KV *et al.*, laparoscopy observed abnormal findings in 85% of the cases, the most common finding being abdominal tuberculosis (38.33%) followed by appendicitis (26.7%) and adhesions (10%)^[12]. In the study by Prasad S *et al.* most common finding was appendicitis (30%) followed by abdominal tuberculosis (22%)^[11]. In the study by Husain M *et al.*, diagnosis was established in 86.5% cases with most common pathology being chronic appendicitis (19%) followed by adhesions (17.3%) and peritoneal tuberculosis (15.3%)^[14].

We were able to manage 90% cases via laparoscopic procedures for their respective pathologies, while 10% cases required conversion to open laparotomy. In the study by Sayed *et al.* therapeutic interventions were carried out in 63.5% patients, while conversion to open laparotomy was required in 10.9% cases^[13]. Therapeutic interventions were carried out in 70% and 53% cases in the studies by Prasad S *et al.* and Kumar *et al.* respectively^[11, 12]. Therapeutic laparoscopy or laparoscopy-assisted surgery was performed in 74% cases by Naniwadkar *et al.*^[15] Conversion rate of laparoscopy to laparotomy in chronic abdomen was required in 8%, i.e. 4 cases.

In our study, pain relief was achieved in 92% cases, post-laparoscopy, while persistence of CAP was seen in 8% cases. Sayed K *et al.*, in their study observed positive outcome (relief/reduction of pain after diagnostic laparoscopy) in 92.2% of patients^[13]. Prasad S *et al.* in their study observed that 92% of patients had pain relief^[11]. Hannu P *et al.*, in their study, reported that in 90% patients, laparoscopy /assisted surgery was beneficial for their intractable pain^[16]. A total of 89.3% cases reported relief from pain at follow up in the study by Miller K *et al.*^[17]

A good correlation was observed between laparoscopic diagnosis and histopathological findings. Diagnostic accuracy of laparoscopy in the present study was 95.5%. Diagnostic accuracy of laparoscopy observed in the study by Sayed *et al.* and Jadhav KV *et al.* was 89.1% and 85% respectively^[13, 12]. Diagnostic accuracy observed in various other studies was as follows: Miller K *et al.* (89.8%), Raymond *et al.* (85.7%)^[17, 18].

In the present study, superficial surgical site infection was observed in 2 cases (4%). No other intra-operative or post-operative complication was observed in any case. Various studies have also reported minimal or no complications in the procedure of diagnostic or therapeutic laparoscopy. Prasad S *et*

al. in their study observed infection in only 2 cases (2%)^[11] In the study by Naniwadkar *et al.* reported complications in 5 cases (10%) of chronic abdomen during laparoscopy, of which 3 were post-operative and 2 were intra-operative - both being instrumental trauma over liver^[15]. Miller K *et al.* and Jadhav KV *et al.*, in their studies, observed no postoperative complication post laparoscopy^[17, 12].

Conclusion

In conclusion, we state that laparoscopy has an effective diagnostic role in evaluating patients with chronic abdominal pain in whom conventional methods of investigations have failed to elicit a certain cause. The therapeutic value of laparoscopy is also accepted, appreciated and it cannot be underestimated. If performed early in the course of the disease, it helps in reducing the hospital stay, treatment cost and morbidity to the patient.

References

1. Camilleri M. Management of patients with chronic abdominal pain in clinical practice. *Neurogastroenterol Motil.* 2006; 18:499-506.
2. Townsend CO, Sletten CD. Physical and emotional functioning of adult patients with chronic abdominal pain: comparison with patients with chronic back pain. *J Pain* 2005; 6:75-83.
3. Ferrell BR. The impact of pain on quality of life. A decade of research. *Nurs Clin North Am.* 1995; 30:609-24.
4. Van Goor H. Consequences and complications of peritoneal adhesions. *Colorectal Dis.* 2007; 9:25-34.
5. Arya PK, Gaur KJ. Laparoscopy: A tool in the diagnosis of lower abdominal pain. *Indian J Surg.* 2004; 66:216-20.
6. Lindsetmo RO, Stulberg J. Chronic abdominal wall pain – A diagnostic challenge for the surgeon. *Am J Surg.* 2009; 198:129-34.
7. Malik AM, Talpur KA, Soomro AG, Qureshi JN. Yield of diagnostic laparoscopy in abdominal tuberculosis: is it worth attempting? *Surg Laparoscopy Endosc Percutan Tech.* 2011; 21:191-3.
8. Rai S, Thomas WM. Diagnosis of abdominal tuberculosis: the importance of laparoscopy. *J R Soc Med.* 2003; 96:5868.
9. Peters AA, Van den Tillaart SA. The difficult patient in gastroenterology: chronic pelvic pain, adhesions, and sub occlusive episodes. *Best Pract Res Clin Gastroenterol.* 2007; 21:445-63.
10. Jori GP, Peschle CL. Combined peritoneoscopy and liver biopsy in the diagnosis of hepatic neoplasm. *Gastroenterology.* 1972; 63:1016-19.
11. Prasad S, Jain S, Prakash A. Evaluation of efficacy of laparoscopy in patients with chronic abdominal pain. *International Surgery Journal.* 2017; 4(6):1856-60.
12. Jadhav KV *et al.* Efficacy of Diagnostic Laparoscopy in Chronic Abdominal Pain an Indian Perspective, *JMSCR.* 2017; 5(11):112-114
13. Sayed ZK, Verma RA, Madhukar KP. Role of Diagnostic Laparoscopy in Chronic Abdominal Pain *Int J Sci Stud* 2015; 3(4):31-35.
14. Husain M, Sachan PK, Khan S, Lama L, Khan RN. Role of Laparoscopy in Chronic and recurrent Abdominal Pain” *Tropical gastroenterology.* 2014; 34(3):170-3.
15. Naniwadkar RG, Kabra MV, Reddy MS. Role of Diagnostic Laparoscopy in Chronic Abdominal Pain *Int J Sci Stud* 2016; 5(17):859-63.

16. Hannu Paajanen, Kristiina Pulkunen, Heidi Waris. Role of Diagnostic Laparoscopy in Chronic Abdominal Pain *J Clin Gastroentrol* 2005; 39(1):110-114.
17. Miller KE, Moritz. The Role of Laparoscopy in Chronic and recurrent Abdominal Pain *A M J Surg.* 1996; 172(4):353-7
18. Raymond OP, Middendorf EA. Utility of Laparoscopy in chronic abdominal pain. *Surgery.* 2003; 134:549-52.