



E-ISSN: 2616-3470
P-ISSN: 2616-3462
© Surgery Science
www.surgeryscience.com
2020; 4(1): 88-90
Received: 21-11-2019
Accepted: 24-12-2019

Dr. Jagdish B Hedawoo
Associate Professor, Department of
General Surgery, Government
Medical College, Nagpur,
Maharashtra, India

Dr. Mohd Danish Mushtaque A
Surgery Resident, Department of
General Surgery, Government
Medical College, Nagpur,
Maharashtra, India

Dr. Sanjay S Changole
Associate Professor, Associate
Professor, Department of General
Surgery, Government Medical
College, Nagpur, Maharashtra,
India

Corresponding Author:
Dr. Mohd Danish Mushtaque A
Surgery Resident, Associate
Professor, Department of General
Surgery, Government Medical
College, Nagpur, Maharashtra,
India

Sensitivity of FAST for hemoperitoneum in blunt trauma abdomen

Dr. Jagdish B Hedawoo, Dr. Mohd Danish Mushtaque A and Dr. Sanjay S Changole

DOI: <https://doi.org/10.33545/surgery.2020.v4.i1b.317>

Abstract

Introduction: The great value of FAST lies in its high sensitivity for detecting intra peritoneal fluid which accumulates in dependent areas around the liver, spleen and pouch of Douglas (pelvic).

Material and Methods: Prospective observational study was carried out for the duration of 2.5 years. 300 patients of blunt trauma abdomen admitted in trauma casualty were included in this study. In FAST assessment 255 patients were diagnosed positive for hemoperitoneum; in 50 patient's emergency exploratory laparotomy were done.

Conclusion: FAST has sensitivity of 85.26% for detecting free intra-peritoneal fluid in BAT cases.

Keywords: FAST: Focused assessment sonography for trauma, RTA: Road traffic accident, eFAST: extended FAST, BAT: Blunt abdominal trauma, RR: Radiology resident

Introduction

Blunt Abdominal trauma is one of the most common causes among injuries caused mainly due to road traffic accidents. Blunt injury of abdomen is also a result of fall from height, assault with blunt objects, industrial mishaps, sport injuries, bomb blast and fall from riding bicycle. Blunt abdominal trauma is usually not obvious hence often missed unless repeatedly looked for. In spite of the best techniques and advances in diagnostic and supportive care, the morbidity and mortality remains at large. The reason for this could be due to the interval between trauma and hospitalization, inadequate and lack of appropriate surgical treatment, Due to the delay in diagnosis and inadequate treatment of the abdominal injuries, most of the cases are fatal, It is the second largest single cause of death accounting for 16%, only second to parasitic and infectious diseases at 23%. WHO also estimates that, by the year 2020, trauma will be the first or second leading cause of "years of productive life lost" for the entire world population in both developed and developing world [1] FAST is a goal directed study answering a simple question as to whether there is intra peritoneal fluid or not. It is a safe quick diagnostic tool that can be learnt easily. It is of great value for those patients who are haemo-dynamically unstable and who cannot be shifted to CT scan room.

Material and Methods

Patients of road traffic accident with blunt trauma abdomen admitted in emergency Trauma care Center casualty of government medical college, Nagpur, 300 patient of road traffic accident in time span of June 2017 to November 2019 were included for this study as prospective observational study but the patient with blunt trauma abdomen with head injury were excluded, after admission the history were obtained from the patient or relative, thorough clinical examination was done in every case, clinical findings and relevant investigations performed over the patient, after emergency lifesaving care provided to patient All patient scanned by a FAST investigation by junior resident of 3rd year in the department of radiology. The fast investigation was performed using 4 windows (figure1): 1) Subxiphoid, 2) Right-upper quadrant (Morrison 'space), 3) Left upper quadrant, 4) Supra-pubic,

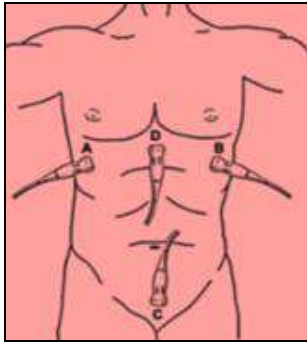


Fig 1: Four view for the original FAST

The addition of the detection of a pneumothorax was included in the eFAST protocol in 2004. The eFAST protocol is a useful tool where we use an ultrasound examination in a trauma setting to detect free fluid, in this case, bleeding. In detection of free intra peritoneal and intra thoracic fluid, this protocol has a high specificity and sensitivity both over 90%. In the detection of pleural effusion or hemothorax ultrasound can detect even the smallest amounts of fluid (20 ml) whereas you need 200ml to detect those pathologies with a chest X-Ray.

Observation

The FAST investigation was classified as positive (clearly showing fluid on at least one window), or negative (scan in at least three views, no fluid). The primary aim of the FAST

investigation was to detect intra-peritoneal blood, Patients were classified into FAST positive and FAST negative, vitally unstable, deteriorating patients were operated and the findings of FAST correlated with operative findings, data were tabulated and sensitivity of investigations analyzed, all collected data is preserved in specific format. Then the collected data analyzed and observation drawn.

Table 1: Findings of BAT on FAST

Findings of BAT on FAST	No. of patients	Percentage
Positive	255	85.26
Negative	45	14.7
Total	300	

FAST done in all 300 patient of road traffic accident with blunt trauma abdomen coming to trauma casualty 85.2% (255 patients) were diagnosed positive with hemoperitoneum and 14.7% (45 patients) could not diagnose with any intra-abdominal collection. In this study FAST in blunt abdominal trauma patient shows maximum time fluid detected in pelvic irrespective of site of organ injury due to its most dependent position (22.6%), but collection in more than one windows of FAST is more common (43.6%) than single window, in 16.3% patient FAST could not shows any collection, out of this 50 patient were taken for emergency exploration depending on FAST finding, 5(10%) patients were underwent negative laparotomy, no mortality were observe,

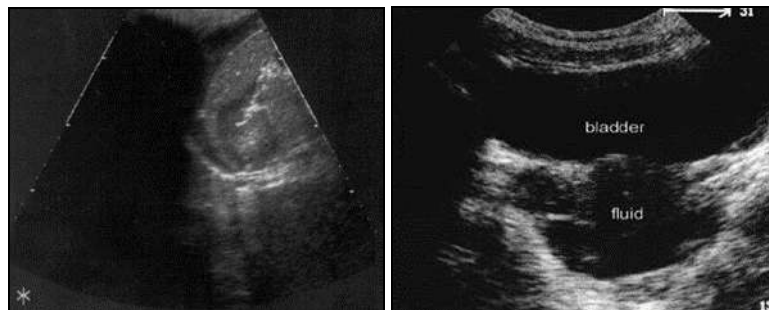


Fig 1: FAST showing collection in Morrison's pouch and behind bladder

Discussion

In present study, FAST (Focused Abdominal Sonography for Trauma) was done in all 300 cases of road traffic accident with blunt trauma abdomen admitted in trauma care center casualty of government medical college Nagpur, out of which intra-abdominal fluid was found in 255/300 patient and sensitivity was 85.26%, no fluid was detected in abdomen 14.74% (45/300)patient [2-7]. Out of this 50 patient were taken for emergency exploration depending on FAST finding, 5(10%) patient were underwent negative laparotomy, no mortality were observe, FAST finding also varies depending on the time after BTA patient presented to the hospital, as on early presenting to the hospital after BTA there is minimal collection of free fluid in abdomen which is usually not detected by Sonography, the volume required for detection in the FAST (median minimal volume of fluid) is 100 ml [8], in female patients of reproductive age, up to 50 ml fluid in pouch of Douglas are considered as physiological, and amount exceeding more than 50 ml should be regarded as pathological in the setting of trauma, free fluid should not be found in recto- vesicular space in male [9], repeat scan after 12-24 increase sensitivity of FAST, sensitivity of FAST increased by 65 to 70% as compared to scan done immediately after trauma (with hours) as time required for

accumulation of blood in peritoneum/dependent spaces [10] required Clinical observation time following BTA is controversial, it's required for minimum of 8 hours to 24 hours [11].

Finding of FAST and its sensitivity is also operator dependent. In present study all FAST was performed by junior radiology resident third year (RR) had sensitivity of 85.26%, when scan done by emergency medicine or surgery resident sensitivity is still lower than observed in this study [12-13].

Out of 300 patient of RTA with blunt trauma abdomen admitted in trauma care casualty in government medical college Nagpur, 50 patient were taken for emergency laparotomy as these patient were vitally unstable and deteriorating, out of 50 patient 45 patient were found to be having same finding observe in FAST ultra- sonography, 5(10%) patient shows negative laparotomy on basis of FAST ultra-Sonography along with clinical finding.

Conclusion

FAST is rapid, noninvasive, easily available, affordable and bedside investigation modality useful in blunt abdominal trauma cases. FAST does not interrupt the resuscitation process in seriously injured patients. Though FAST is operable dependent; FAST is helpful in initial evaluation of Blunt abdominal trauma

cases. Early decision making for immediate laparotomy in Blunt abdominal trauma cases could be taken on the basis of FAST findings.

2015; 17(12):e20-302), 2016; 18(3):e43-586.

References

1. Mock CN, Jurkovich GI, Nii-Anton-Kotei D, Arreola-Risa C, Maier RV. Trauma mortality patterns in three nations at different economic levels: implications for global trauma system development. *The Journal of Trauma*. 1998; 44(5):804-814. [PubMed]:
2. Poletti PA, Kinkel K, Vermeulen B, Irmay F, Unger PF, Terrier F. As Blunt abdominal trauma: should US be used to detect both free fluid and organ injuries published in *Radiology*. EPUB. 2003; 227(1):95-103.
3. By Lee BC, Ormsby EL, McGahan JP, Melendres GM, Richards JR. as The utility of sonography for the triage of blunt abdominal trauma patients to exploratory laparotomy published in *AJR Am J Roentgenol*. 2007; 188(2):415-21.
4. Arhami Dolatabadi A, Amini A, Hatamabadi H, Mohammadi P, Faghihi-Kashani S, Derakhshanfar H *et al.* by Comparison of the accuracy and reproducibility of focused abdominal sonography for trauma performed by emergency medicine and radiology residents. Published in *Ultrasound Med Biol*. 2014; 40(7):1476-82. Doi: 10.1016/j.ultrasmedbio. 2014.01.017. EPUB 2014 Mar 7
5. Holmes JF, Harris D, Battistella FD. As Performance of abdominal ultrasonography in blunt trauma patients with out-of-hospital or emergency department. Published in *Hypotann Emerg Med*. 2004; 43(3):354-61.
6. Kumar S, Bansal VK, Muduly DK, Sharma P, Misra MC, Chumber S *et al.* As Accuracy of Focused Assessment with Sonography for Trauma (FAST) in Blunt Trauma Abdomen-A Prospective Study. Published in *Indian J Surg*. 2015; 77(2):393-7.
7. By Chi Leung Tsui, Hin Tat Fung, Kin Lai Chung, Chak Wah Kam as Focused abdominal sonography for trauma in the emergency department for blunt abdominal trauma Published online. 2008; 1(3):183-18. Doi: 10.1007/s12245-008-0050-2 in *Int. J Emerg Med*.
8. In study by Von Kuenssberg Jehle D, Stiller G, Wagner D. Sensitivity in detecting free intraperitoneal fluid with the pelvic views of the FAST exam. published in *Am J Emerg Med*. 2003; 21(6):476-478,
9. In study by Study by John R, Richards, John P. McGahan as Focused Assessment with Sonography in Trauma (FAST) in: What Radiologists Can Learn Published Online: Mar 14, 2017.
10. Afshin Mohammadi, Mohammad Ghasemi-rad as Evaluation of gastrointestinal injury in blunt abdominal trauma FAST is not reliable: the role of repeated ultrasonography Published online 2012 Jan 20. Doi: 10.1186/1749-7922-7-2 in *World J Emerg Surg*, 2012.
11. Samer Malak Boutros, Mohamed Amin Nassef, Ahmed Fathy Abdel-Ghany. Blunt abdominal trauma: The role of focused abdominal sonography in assessment of organ injury and reducing the need for CT published in *Alexandria Journal of Medicine*, March. 2016; 52(1):35-41.
12. Majid Zamani, Babak Masoumi, Mehrdad Esmailian, Amin Habibi, Mehdi Khazaei, Mohammad Mohamm. As A Comparative Analysis of Diagnostic Accuracy of Focused Assessment with Sonography for Trauma Performed by Emergency Medicine and Radiology Residents This article has been retracted. Retraction in: *Iran Red Crescent Med J* See also: PMC Retraction Policy (*Iran Red Crescent Med J*