



International Journal of Surgery Science

E-ISSN: 2616-3470
P-ISSN: 2616-3462
© Surgery Science
www.surgeryscience.com
2020; 4(1): 440-444
Received: 13-11-2019
Accepted: 17-12-2019

Dr. Lingam Alishala
Assistant Professor,
Department of General Surgery,
RVM Medical College & Research
Centre, Laxmakkapally, Mulugu,
Telangana, India

Dr A Bhaskar
Assistant Professor,
Department of General Surgery,
Surabhi Institute of Medical
Sciences, Siddipet, Telangana,
India

An observational study on complications and management of pseudo cysts of pancreas-In a tertiary care hospital

Dr. Lingam Alishala and Dr A Bhaskar

DOI: <https://doi.org/10.33545/surgery.2020.v4.i1h.382>

Abstract

Pancreatic pseudo cysts can occur as a complication of acute or chronic pancreatitis. Understanding of pseudo cysts has changed with times due to advancement in radiology and introduction of new treatment modalities. This study was done to access clinical features and various managements for pseudocyst in a tertiary care hospital.

Methods: It is a prospective study of 20 adult patients admitted in tertiary care centre Surabhi Institute of Medical Sciences, Siddipet, Telangana, India from November 2018 to June 2019.

Results: Pseudo cysts are more common in males. The commonest etiology associated was chronic pancreatitis with prevalence of 50%. Most of the cases of pseudo cysts of the pancreas due to acute pancreatitis. Ultrasound was the basic radiological investigation done in all patients followed by CECT abdomen. The commonest presentation is upper abdominal pain with upper abdominal mass. All cases we have confirmed that the cyst wall is deficient of epithelium by HPE. Internal drainage was done in most of the patients. Post drainage complications included infection which was managed by antibiotics and endoscopic drainage in case of recollection. Pain was most important post-operative complication. Infection was the common complication and mortality is nill. Endoscopic drainage is being preferred as it is less invasive, has a high long term success rate, and has shorter duration of hospital stay and more patient comfort.

Conclusions: Pseudo cyst of pancreas is most commonly seen in males probably because of chronic pancreatitis. Clinical presentation can be varied, with pain abdomen being the most common complaint followed by, nausea vomiting. Initial management consists of supportive care and if the symptoms persist and complications develop surgical drainage was the most common management modality. Newer modalities of treatments like cystogastrostomy have an added advantage of lesser pain, shorter duration of hospital stay and recurrence. External drainage was done in 6 cases. The present study concluded that conservational approach and ultra sound guided external drainage are better for pseudo cysts with acute pancreatitis and traumatic etiology.

Keywords: Pseudo cysts, cystogastrostomy, pancreatitis, external drainage, mortality, acute pancreatitis

Introduction

Pancreatic pseudo cysts are the most common cystic lesions of the pancreas. They are distinguished from other types of pancreatic cysts by their lack of an epithelial lining, pseudo cysts are localised collections of pancreatic juice occurring as a result of pancreatic inflammation or trauma.

Pancreatic Pseudo cysts were once thought to be unusual complications of pancreatitis. With the development of improved imaging techniques, such as ultrasound and CT they are being recognized in over 10% of cases of pancreatitis. They may arise as a complications of pancreatitis or a as result of trauma to the pancreas.

Although surgical drainage remains the principal method of treating pseudo cysts; its pre-eminence has recently been challenged. The introduction of innovative procedures by both interventional radiologists and therapeutic endoscopists offer the attractive ability to drain pancreatic fluid collections non-operatively.

These new and imaginative therapies compete with the traditional operative treatment of pancreatic pseudo cysts. But despite these technical advances, several recent reports by surgeons have challenged the previously accepted surgical dogma that established pancreatic pseudo cysts require operative treatment. Current management strategies are therefore controversial.

Corresponding Author:
Dr A Bhaskar
Assistant Professor,
Department of General Surgery,
Surabhi Institute of Medical
Sciences, Siddipet, Telangana,
India

The most complications that arise are infection, haemorrhage, obstruction and rupture. Individual patients may synchronously manifest more than one of these complications.

Pancreatic pseudo cysts can occur as a complication of acute or chronic pancreatitis [1]. Diagnosis is most often accomplished by USG abdomen and CECT abdomen [2].

Most of them resolve spontaneously with supportive care. However, outcome is dependent on size and duration, with larger cysts prone for complications. Understanding of pseudo cysts has changed with times due to advancement in radiology and introduction of new treatment modalities [3].

The two main indications for some type of invasive drainage procedure are persistent patient symptoms or the presence of complications. Endoscopic (transpapillary or transmural) drainage, percutaneous catheter drainage, surgery are drainage modalities available [4].

Although there are no prospective controlled studies that have compared directly these approaches. But in general, endoscopic drainage is becoming the preferred approach because it is less invasive than surgery, avoids the need for external drain, and has a high long-term success rate.

Hence a multidisciplinary team comprising of therapeutic endoscopist, interventional radiologist and pancreatic surgeon should be involved in all cases [5]. In this study we would be throwing light on the, various treatment modalities and also study the overall morbidity & mortality of pancreatic pseudo cyst in a tertiary care hospital.

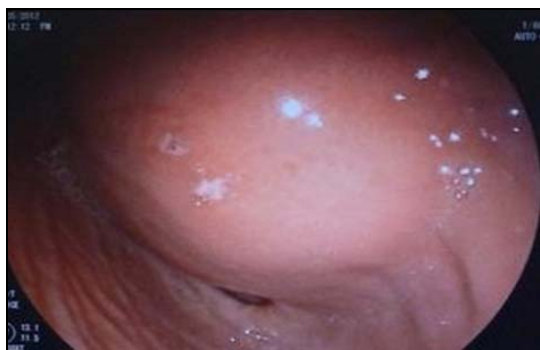

Fig 1: Pseudocyst of pancreas (Photo taken from Babu GR et al., 2017)

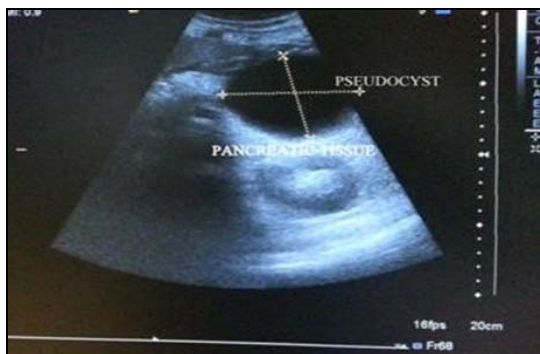


Fig 2: Ultrasonographic image of pseudocyst.

Materials and Methods

Study site

The study was conducted in the Department of Surgery, tertiary care Hospital, from November 2018 to June 2019. Patients with clinical history, laboratory findings and/or USG findings suggestive of pancreatitis were prospectively evaluated by supine position in a siemens somatom emotion 6 Slice CT

machine in suspended inspiration using a kVp of 130 and mAs of 100.

The study population included all patients who were followed for chronic pancreatitis complicated by pseudo cysts between November 2018 to June 2019 in the Department of Surgery, at the tertiary care hospital Siddipet.

After admission, data for study was collected by history, clinical findings, relevant diagnostic investigations performed over patient.

Inclusion criteria

Patients diagnosed with pseudo cyst of pancreas, using ultrasound abdomen/contrast enhanced computerized tomography scan abdomen.

Patient giving valid informed consent

Exclusion criteria

Patients less than 17 years of age, diagnosed with pseudo cyst of pancreas.

Patients diagnosed as cystic neoplasm of pancreas.

All patients with acute pseudo cyst were managed conservatively by symptomatic treatment and followed up to see regression or maturation of cyst. All mature cysts were treated by the most appropriate drainage procedure.

Percutaneous drainage was done under radiological guidance. Endoscopic drainage and surgical drainage (cystogastrostomy and cystojejunostomy) were done in selected cases. After discharge patients were followed up for a period of 6 months to 1½ years. Details were then charted in the study proforma and the data was analyzed with respect to various aims and objectives of the study.

Definitions

The diagnosis of pseudo cysts was based on CT findings. A pseudo cyst was defined as a collection of liquid more than 10 mm in diameter, which was clearly distinct from the pancreatic parenchyma and the adjacent organs, and exhibited low density before intravenous injection of a contrast medium, which was not enhanced after injection. Multiple pseudo cysts were defined as at least two such lesions.

The diagnosis of chronic pancreatitis was based on the presence of at least one of the following criteria: pancreatic calcifications on abdominal plain X-ray, CT scan, ultrasound, or endoscopic ultrasound; anomalies of the pancreatic ducts at pancreatic retrograde endoscopy, which were at least moderate according to the international Cambridge classification; histological diagnosis of chronic pancreatitis with a biopsy or surgical specimen.

Data collection

CT examinations were performed on supine position in a siemens somatom emotion Slice CT machine in suspended inspiration using a kVp of 130 and mAs of 100. The patients were scanned using our institution's two-phase acquisition pancreatic protocol. The patients were instructed to drink 500mL of water for negative opacification of the gastrointestinal tract immediately before imaging. The initial pancreatic phase (Late Arterial Dominant Phase) of the examination was performed over the upper abdomen from T11 to L3 vertebral body levels with a scanning delay of 40 seconds after the start of IV administration of 1.5 mL/kg of contrast material at an injection rate of 2 mL/sec.

The following clinical and biochemical data were recorded: symptoms related to pseudocysts (pain, fever, and vomiting, abdominal mass); time elapsed from the diagnosis of chronic

pancreatitis; recent acute pancreatitis which could account for the development of pseudo cysts. Pancreatic enzymes were also analyzed (serum amylase).

Chest x ray

This may show elevation of diaphragm or pleural effusion.

Abdominal X-Ray examination

Plain film of the abdomen reveals a mass lesion, calcification etc.

Upper GI barium series- will be abnormal with evidence of a mass lesion or displacement of the stomach and other viscera in 50-75% of patients. There may be delayed emptying and narrowing of the duodenal sweep due to pressure of the cyst.

Ultra radiological findings

Ultrasonography is extremely helpful and accurate in making the diagnosis, in evaluating cysts wall thickness and in following the cysts during expectant management. It has been found to be 90% accurate and 98% specific when the pancreas could be visualized.

ERCP

ERCP demonstrates abnormalities of the pancreatic duct in up to 90% of the patients with pseudo cysts. Nearly 2/3 of pseudo cysts communicate with pancreatic duct. Obstructions of the pancreatic duct, compression of the cysts, or changes consistent with chronic pancreatitis are frequently noted. ERCP is very helpful in managing chronic pseudo cysts arising in the setting of chronic pancreatitis. ERCP is an invasive procedure that can be potentially aggravate pancreatitis or introduce infection(10-15%) into the pseudo cysts in spite of the use of prophylactic antibiotic, Thus ERCP should be performed within 48 hrs of the proposed study.

Angiography

Celiac and superior mesenteric angiography is generally not useful for the diagnosis of pseudocysts nor should it be necessary in the pre-operative evaluation of pseudo cysts. In patients who have had bleeding complications from pseudo cysts, however or in those who have portal hypertension, it may provide valuable information that can alter the surgical approach. The finding of spleen vein thrombosis with left-sided portal hypertension is an

indication for splenectomy in patients undergoing operation for drainage of pseudo cysts. Angiography also helps in clarifying the presence of pseudoaneurysm formation in the cysts wall which is present in nearly 11% of the patients. Stretching of intra pancreatic arteries almost always means pseudo cysts. Angiography is also useful therapeutically in the control of bleeding from pseudocyst.

Results

Table 1: Incidence of etiology of pseudo cysts

Common cause	No of cases
Chronic pancreatitis	10
Acute pancreatitis	05
Trauma	04
Idiopathic	01

In the present study, most of the patients suffered with chronic pancreatitis 10 (50%) it's a commonest cause for the formation of pseudo cysts. Haemorrhage, rupture and pressure on adjacent viscera were the main complications of pseudo cysts of the pancreas.

Table 2: Radiological findings on Upper GI series

1. Anterior displacement of stomach
2. Pressure effect on greater curvature of stomach
3. Widening of "C" loop
4. Depression of duodenojejunal junction

Table 3: Complications of Pseudocysts

Infection	Abscess
Hemorrhage	Into the cyst GI hemorrhage
Pressure on adjacent viscera	Biliary tree
	Stomach and duodenum
	Inferior vena cava
	Transverse colon
Rupture	Peritoneal cavity
	GIT
	Thorax
Involvement of Spleen	Splenic necrosis
	Hemorrhage into cysts
	Splenic vein thrombosis
	Rupture spleen

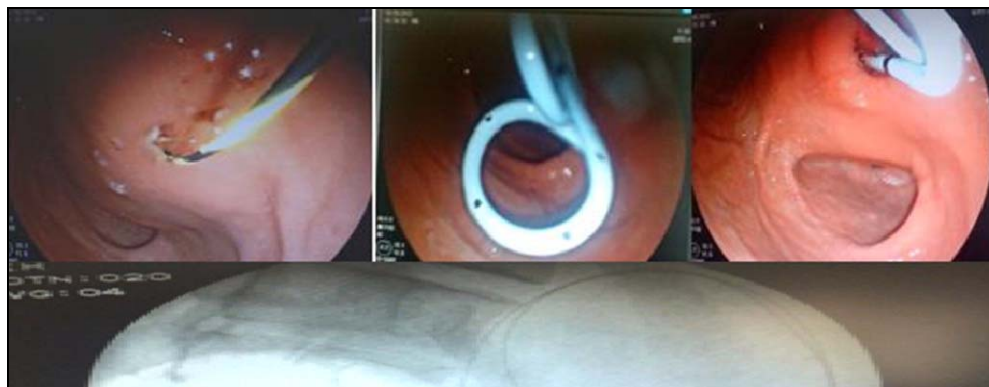

Fig 3: Endoscopic drainage of pseudocyst and fluoroscopic picture showing the guide wire curled inside cyst cavity.

Table 4: Treatment modalities Incidence

Treatment modalities		No of patients
Conservative		2
External Drainage	US guided	3
	Marsupialization	1
	Tube drains	2
Internal	Cysto gastrostomy	11
	Pancreatico Jejunostomy	1

Management

The present findings revealed that, commonest procedure for management is cystogastrostomy 11 (55%) for the excision of pseudo cysts and is followed by the External drainage 6 (30%). 2 (10%) managed by the conservative approaches. Out 20 patients only one patient was managed by pancreatic jejunostomy

Discussion

In present study 85% patients presented with abdominal pain, followed by mass abdomen in 60% of patients. 40% of patients had nausea and vomiting. Thus it is clear that pain abdomen and nausea/vomiting are a commonest symptom which brings the patient to hospital.

Most common complication in present study was gastric outlet obstruction seen in 10% of patients followed by ascites and infection in 7.5% and 5% of patients respectively. Thus pseudo cysts can present with a varied range of complications mainly based on its size location and duration [6]. Based on present radiological imaging Studies have concluded that the final management option depends on the availability of resources and local expertise.

Management of Pancreatic Pseudo cysts

Viewed from a surgical standpoint, these new operative techniques increase the therapeutic armamentarium available for acute pseudo cysts but certainly do not render operation obsolete.

Choice of operation

Controversy surrounds the question of which viscous should be used for pseudocysts drainage. Cystojejunostomy is the most versatile method of pseudo cysts drainage and is particularly appropriate when the pseudo cysts at diagnosis is seen at the base of transverse mesocolon, is not adherent to the posterior gastric wall., or is extremely large.

Most pancreatic pseudo cysts are drained internally by means of cystojejunostomy or cystogastrostomy. A result study compared 59 patients with cystojejunostomy with 39 patients with cystogastrostomy. The pseudo cysts treated by cystojejunostomy tended to be smaller (6.7cm) than those treated by cystogastrostomy (11.2cm); however, the mean blood loss for cystojejunostomy was significantly greater (703ml) than for cystogastrostomy (397ml). The pseudo cysts recurrence rates were similar (7% and 10% after cystojejunostomy and cystogastrostomy, respectively) and overall morbidity and mortality rates were comparable [7].

The authors concluded that cystogastrostomy should be considered whenever feasible automatically because it can be performed more quickly and with less blood loss. Another study, however warned that cystojejunostomy is preferable to cystogastrostomy for giant pseudo cysts (>15cm) because of smaller rate of morbidity [8].

The final option for internal drainage is cystoduodenostomy. This procedure has more limited use because it is applicable

only to pseudo cysts in the head and uncinata process of the pancreas that lie within 1 cm of the duodenal cystoduodenostomy is performed in a fashion similar to transgastric cystogastrostomy, that is by opening the lateral duodenal wall creating a direct communication between the pancreatic pseudo cyst and the duodenum through a medial duodenectomy [9, 10].

30% of patients in present study underwent internal drainage as compared to 22.5% of patients who were managed endoscopically [11]. All the patients were followed up for a period of 6 months to 1½ years post discharge. Those who were managed conservatively had complete resolution of the cyst at the end of study period. Endoscopically managed patients were followed up with USG abdomen every month and double pig tails were removed in 5 patients.

Upper gastrointestinal hemorrhage is the most frequent complication of internal cyst drainage. It occurs in about 12% cases and is associated with a high mortality rate. Pseudoaneurysm was the source of bleeding in 13 or 120 patients (11%) undergoing cystogastrostomy in Frey's series of pancreatic pseudo cysts. This experience led him to advocate preoperative angiography of the superior mesenteric and celiac arteries in all patients with pseudo cysts [12].

Resection is an alternative to internal drainage for chronic pseudo cysts of moderate proportions, especially those that have largely replaced a portion of the pancreas. Frey performed 26 distal resections and 5 proximal resections in a series of 131 patients. The indication for resection included painful chronic pancreatitis, multiple cysts, gastrointestinal hemorrhage from pseudoaneurysm, CBD obstruction, inability to drain uncinata cysts and duodenal obstruction.

A number of different operations can be used to resect pancreatic pseudo cysts. Those in the body and tail are generally treated by distal pancreatectomy with splenectomy. Although conservative (spleen-preserving) pancreatectomy in chronic pancreatitis is sometimes performed, it is not recommended in patients with pseudo cyst because of the splenic vessels are generally encased in inflammatory scar tissue and may be compressed or even thrombosed. A desire to minimize the extent of resection in this benign disease has led to the application of pylorus-preserving (and even duodenum-preserving) proximal pancreatectomy [13]. For complicated chronic pancreatitis confined to the head of the gland. If there is dilation of the duct in the residual distal pancreas, a longitudinal pancreatic jejunostomy can be used during reconstruction. A cyst in the head of the pancreas can compress the superior mesenteric or portal vein, with a risk of vascular injury during its removal [14]. Thus visceral angiography is highly desirable before undertaking cyst resection in chronic pancreatitis.

Conclusion

The present study concluded that chronic pancreatitis is the common cause of formation of pseudo cysts. Cystogastrostomy is the most important procedure for excision of pancreatic pseudocysts. Very good postoperative results seen with

cystogastrostomy. Conservative approach and ultrasound guided external drainage are better for pseudo cysts with acute pancreatitis and traumatic etiology. The endoscopic and minimally invasive therapeutic procedures for the drainage of pancreatic pseudo cysts are superior to open surgical techniques with respect to their success, morbidity, and mortality rates, but they cannot always be performed. In making treatment decisions, it is important to recall that 50% of pancreatic pseudocysts do not require any intervention and can be successfully managed by a wait-and-watch approach. Thus, the choice of technique depends very heavily on the experience of the treatment centre. The surgical, percutaneous, and endoscopic pseudo cyst drainage procedures have not been directly compared in high-quality prospective randomized studies and the preferred approach vary based on patient preferences and local expertise.

Acknowledgement

Authors would like to thank all the participants of this study and the people who were helping hand in completing this study.

Reference

1. Cannon JW, Callery MP, and Vollmer CM JR. "Diagnosis and management of pancreatic pseudo cysts: what is the evidence?" *Journal of the American College of Surgeons*. 2009; 209(3):385-393.
2. Bradley EL III. "A clinically based classification system for acute pancreatitis: summary of the International Symposium on Acute Pancreatitis, Atlanta, Ga, September 11 through 13, 1992," *Archives of Surgery*. 1993; 128(5):586-590.
3. Imrie CW, Buist LJ, Shearer MG. "Importance of cause in the outcome of pancreatic pseudocysts," *American Journal of Surgery*. 1988; 156(3):159-162.
4. Maringhini A, Uomo G, Patti R *et al.*, "Pseudo cysts in acute non-alcoholic pancreatitis: incidence and natural history", *Digestive Diseases and Sciences*. 1999; 44(8):1669-1673.
5. Barthet M, Bugallo M, Moreira LS, Bastid C, Sastre B, Sahel J. "Management of cysts and pseudo cysts complicating chronic pancreatitis. A retrospective study of 143 patients," *Gastroenterologie Clinique et Biologique*. 1993; 17(4):270-276.
6. Ammann RW, Akovbiantz A, Largiader F, Schueler G. "Course and outcome of chronic pancreatitis. Longitudinal study of a mixed medical-surgical series of 245 patients," *Gastroenterology*. 1984; 86(5):820-828.
7. Sandy JT, Taylor RH, Christensen RM. "Pancreatic pseudo cyst. Changing concepts in management," *American Journal of Surgery*. 1981; 141(5):574-576.
8. Wade JW. "Twenty-five year experience with pancreatic. Pseudo cysts. Are we making progress?" *American Journal of Surgery*. 1985; 149(6):705-708.
9. Egidio AD, Schein M. "Pancreatic pseudo cysts: a proposed classification and its management implications," *British Journal of Surgery*. 1991; 78(8):981-984.
10. Habashi S, Draganov PV. Pancreatic pseudocyst. *World J Gastroenterol*. 2009; 15:38-47.
11. Cannon JW, Callery MP, Vollmer CM. Diagnosis and management of pancreas pseudocysts: what is the evidence? *J Am Coll Surg*. 2009; 209:385-93.
12. Morgan DE, Baron TH, Smith JK, Robbin ML, Kenney PJ. Pancreatic fluid collection s prior to intervention: evaluation with MR imaging compared with CT and US. *Radiology*. 1997; 203:773-8.
13. Callery MP, Meyers WC. Surgical treatment of pseudo cysts after acute pancreatitis In Beger HG, Warshaw A, Carr-Locke DL, Russel RCG, Büchler M, Neoptolemos JP, Saar M (eds): *The pancreas*. Boston, Black well Scientific, 1998, 614-26.
14. Nealon WH, Walser E. Surgical management of complications associated with percutaneous and/or endoscopic management of pseudo cyst of the pancreas. *Ann Surg*. 2005; 241:948-60.