



## International Journal of Surgery Science

E-ISSN: 2616-3470

P-ISSN: 2616-3462

© Surgery Science

[www.surgeryscience.com](http://www.surgeryscience.com)

2020; 4(1): 458-461

Received: 24-11-2019

Accepted: 26-12-2019

**G Ashok Swaminathan**

Department of Plastic Surgery,  
Rajah Muthiah Medical College &  
Hospital, Annamalai University,  
Annamalainagar, Tamil Nadu,  
India

**CS Subramanian**

Department of General Surgery,  
Rajah Muthiah Medical College &  
Hospital, Annamalai University,  
Annamalainagar, Tamil Nadu,  
India

**Subbulakshmi Sundaram**

Department of Anesthesia, Rajah  
Muthiah Medical College &  
Hospital, Annamalai University,  
Annamalainagar, Tamil Nadu,  
India

**Corresponding Author:**

**G Ashok Swaminathan**

Department of Plastic Surgery,  
Rajah Muthiah Medical College &  
Hospital, Annamalai University,  
Annamalainagar, Tamil Nadu,  
India

### Novel effective treatment for diabetic foot ulcers [DFU] by vacuum assisted wound closure therapy

**G Ashok Swaminathan, CS Subramanian and Subbulakshmi Sundaram**

**DOI:** <https://doi.org/10.33545/surgery.2020.v4.i1h.400>

#### Abstract

**Introduction:** Foot ulcers are serious complication of Diabetes Mellitus and are known to be resistant to conventional treatments. They may end in severe complications like amputations if not treated wisely at the earliest. Foot ulcers affect 10-25% of Diabetic patients. Management of a Diabetic Foot Ulcer (DFU) is often a challenging problem. Healing of these ulcers often takes a long time and may need one or more methods of treatment. In particular Vacuum assisted wound closure (VAC) therapy has gained popularity for treatment of chronic and complex wounds in patients with Diabetes.

**Aims and Objectives:** To evaluate the efficacy of vacuum assisted wound closure (VAC) therapy for the treatment of diabetic foot ulcers.

**Materials and Methods:** This is a prospective observational study done in Department of Plastic Surgery in Rajah Muthiah Medical College, Annamalainagar, Chidambaram from January 2016 – December 2018 with a total of 30 patients with diabetic foot ulcers. All these patients after admission were started on medical treatment for control of diabetes and antibiotics for infection. They were subjected to wound debridement followed by VAC dressing. The VAC dressing was continued till the ulcer bed developed healthy granulation tissue and ready for definitive procedure like grafting or flap cover. Initial wound surface area and the resultant wound surface area after VAC therapy, duration of hospital stay and procedure done for DFU's were recorded and statistical analysis was done using paired 'T' test to compare wound surface area before and after VAC therapy.

**Result:** This study showed that mean initial wound surface area of 30 patients before VAC therapy was 103.07 cms and after VAC therapy there was significant reduction in wound size to 94.53 cms over a mean duration of 31.9 days. There was statistically reduction in wound size of 9.53 cms. This significantly increased the wound bed granulation tissue and good percentage of graft and flap take up. The daily requirement of antibiotic and analgesic was also reduced. Duration of hospital stay was also reduced due to faster wound healing. There was overall reduction in pain and further complications like amputations were avoided thereby increasing the patients compliance.

**Conclusion:** VAC therapy is newer and a safe method of treatment for Diabetic Foot Ulcers. There is faster wound healing, good graft and flap take with minimal or no complications.

**Keywords:** Dressing, debridement, amputation, wound, skin graft

#### Introduction

Treatment of Diabetic Foot Ulcer (DFU) is often a challenging problem. World's Diabetic burden in 2017 is 425 million <sup>[1]</sup> and estimated to be 629 million in the year 2045. Diabetic burden in 2017 in India is 72.9 million and 134.3 million people are estimated in 2045 in India. 42.2 million people with undiagnosed diabetes. Combined with reduced blood flow, neuropathy and infections in the foot increases the chance of foot ulcers and eventually limb amputation. The rates of amputation in people with diabetes are typically 10-20 times higher than those without diabetes <sup>[2]</sup>. The overall risk of dying among people with diabetes is at least double that of their peers without diabetes. 12 per cent of global health care expenditure is spent on diabetes in 2017. 79 per cent of people with diabetes live in low and middle income countries. In India median per annum direct and indirect cost associated with diabetes care was estimated at Rs. 25,391 and Rs. 4,970, respectively in the year 2010 <sup>[1]</sup>.

Diabetes is a management challenge because of long latency, chronicity, multi organ involvement and need for long term care. DFU is a dangerous complication of diabetes and is the single crucial risk factor for lower limb amputation <sup>[3]</sup>. The fundamental cause of DFU's remain unknown, the probable cause includes peripheral neuropathy, vasculopathy and infection.

Other risk factors for DFU's include male sex, smoking, poor glycemic control, previous risk of ulcer or amputations [4]. Newer and recent modality of treatment of DFU's are ultrasound therapy, laser therapy, photo biomodulation, electrical stimulation, growth factor applications, hyper baric oxygen therapy (HBOT), Platelet Rich Plasma (PRP) application and vacuum assisted wound closure therapy (VAC) [5, 6]. The common complication of diabetes includes foot problems, which is the most common cause of non-traumatic limb amputations [19]. Non-healing diabetic foot ulcers resulting in amputations present significant cost to the health care system and reduce patient quality of life. The aim of treatment of DFU is to obtain wound closure as expeditiously as possible and to prevent complications of diabetes. The efficacy of VAC therapy was described by Argenta L.C. [7] and Morkwas M.J. [8] stating that both comparative and non comparative clinical studies, case studies, revealed that VAC therapy was superior in efficacy as compared to conventional wound dressing in the treatment of DFU. Until the end of 2005 only two randomized controlled trials (RCT) that evaluated clinical effectiveness of VAC therapy in the treatment of diabetic foot ulcers were found in the literature. McCallon included only 10 patients but found faster healing and great wound surface area reduction. Armstrong published a large multi-centric RCT in 2005. Many Indian studies also state that VAC therapy was effective for diabetic foot ulcers as described by Amit Kumar C Jain [2], Nikulesh Vaidhya [9], Nain PS [18]. Though many studies are there from India and also from abroad our study includes patients with diabetic foot ulcers were (1) Larger surface area compare to other studies, (2) Duration of hospital stay was more. The purpose of the study was to determine the efficacy of VAC therapy in the treatment of DFU.

### Material and Methods

This is a prospective observational study done in Department of Plastic Surgery in Rajah Muthiah Medical College, Annamalaiagar, Chidambaram from January 2016 – December 2018 with a total of 30 patients with diabetic foot ulcers. Sample size determination was not done prior to the study but all patients who fulfilled the criteria were included in the study.

### Inclusion and Exclusion criteria

All patients with diabetic foot ulcers of size more than 5 cm, not healing even after 4 weeks of treatment and Wagner Grade 1 and 2 category were included. Other abnormalities like ischemia, gangrene, Osteomyelitis, Coagulation disorders and diabetic complications like diabetic ketoacidosis were excluded.

After ethical approval from the Institutional Human Ethical Committee (IHEC No. 0159/2016) and written informed consent from the patient the study was initiated. Diabetic patients with foot ulcers admitted in Rajah Muthiah Medical College were included in the study. Patients with DFU's were admitted in the Department of Plastic Surgery and required adequate investigations were taken. Affected lower limb arterial and venous Doppler was done to rule out vascular insufficiency and Deep Vein Thrombosis (DVT). Sharp surgical debridement was done under anesthesia in main operation theatre. First VAC dressing was applied in OT after debridement. The VAC dressing consist of 4 components 1. Central suction unit available on all wards (bed side) or suction apparatus with pressure ranging from -80 to -150 mm Hg, 2. Ryle's tube or suction catheter with multiple side holes, 3. Piece of foam cut according to shape and size of the foot ulcer and 4. Transparent adhesive tape for air and water tight closure.

The Ryle's tube or catheter was connected to suction apparatus and initial pressure 80-90 mm of Hg, was applied for 30 minutes on and off round the clock. Then pressure gradually increased. Dressing changed after five days after application VAC therapy. Subsequent VAC dressings if required were applied based on the wound bed in the ward (bed side) under supervision. In between each VAC dressing this patients were subjected to normal conventional saline dressing twice a day. The duration of hospital stay was recorded.

### Statistical Analysis

Data collected were entered into Microsoft Excel Spreadsheet and analyzed using Paired 'T' test and descriptive statistical analysis was done with mean and standard deviation (SD). The P value <0.05 was considered as statistical significant.

### Results

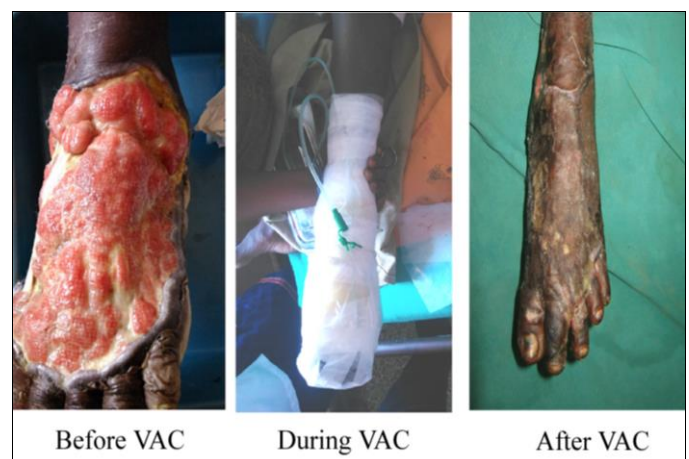
This study was done in 30 DFU patients between the age group of 38 and 70 years. With 20 patients (66.66%) in the age group between 40 and 60 years (Table. 1 and 2).

**Table 1:** Age and sex details

Age (years)	Male	Female
< 40	4	0
41-50	7	5
51-60	6	2
61-70	5	1

**Table 2:** Base line wound variables

Wound Surface Area (cm)				
	Initial	After VAC therapy	Paired 'T' test	'P' value
Mean	103.07	94.53	23.84	< 0.001
SD	17.29	17.13		
Hospital Stay (Days)				
	Minimum	Maximum	Mean	SD
	23	45	31.93	4.58



**Fig 3:** Clinical profile picture before and after VAC therapy

### Discussion

Diabetic foot ulcer is a challenging problem for management. It involves multimodality methods to cure the ulcer which includes (a) Strict control of diabetes, (b) Control and treatment of infections, (c) Assessment and revascularization if indicated, (d) regular dressing and repeated debridement, (e) Surgical reconstruction, (f) Sufficient off loading the foot, (g) Prevention of recurrence, (h) Prevention of complications and amputations. VAC therapy in Diabetic Foot Ulcer is associated with removal

of excess interstitial fluid, an increase in vascularity, decrease in bacterial load and stimulation of granulation tissue formation through the response of wound tissue to the mechanical forces. This micromechanical forces stretches the cells and promote cell division that stimulates granulation tissue formation [10, 11]. The effect of VAC therapy in promoting wound healing and increase

in wound granulation tissue had been demonstrated in several acute, chronic and pressure ulcers in numerous studies [12-14]. Patients compliance was also better in all this patients. Pain was also well tolerated in VAC group patients due to limited dressing change.

Table 3.

S. No.	Author	Study design	Sample size	Size of the ulcer (cms)	Parameters evaluated	Results & Conclusion
1	Amstrong and Lavery (2005) [16]	RCT multicentric	162	22.3±23.4	Granulation tissue	VAC group had increased healing (56% vs 39% p=0.040). The rate of healing was also further in VAC group (p=0.005)
2	Blume (2008) [10]	RCT multicentric	342	13.5±18.2	a. Ulcer closure, b. Surface area reduction	VAC group achieved higher wound closure rate (53.27 vs 28.9%) with fewer secondary complications (p=0.035)
3	Nather. A (2010) [14]	Prospective single centre	11	23.1-35.8	a. Granulation tissue b. Bacterial clearance	100% granulation and bacterial clearance at the end of therapy. Healing was achieved in all wounds
4	McCallon (2000) [15]	RCT Single centre	10	Not clear	a. Wound closure time b. Wound surface area	Wound healing faster in VAC group (22.8±17.4 days vs 42.8 ± 32.5 days for control group)
5	Luca Dalla Paola (2010) [17]	RCT (Study-II) Single centre	130	Not mentioned	1. Granulation tissue 2. Infection clearance	VAC group had faster granulation (65 days vs 98 days) p=0.005. More rapid infection clearance 10 days vs 19 days p=0.05 and better graft take rate
6	Mark T. Eginton (2003) [13]	RCT cross over after 2 weeks single centre	6	Length 77±1.6 cm with 3.5±0.6	Wound depth and wound volume	VAC resulted in a greater wound size compared to moist dressing
7	Vaidhya (2015) [9]	RCT single centre	60	Size > 10 cms	1. Mean no. of dressing 2. Mean days of dressing 3. Cost of dressing	Cost of VAC and conventional dressing was Rs.3,750 and 7000 respectively cost of conventional dressing will increasing significantly by hospital stay
8	Nain (2011) [18]	RCT single centre	30	50-200 cms	1. Wound discharge 2. Wound size 3. Bacterial load	Faster rate of disappearance of discharge was seen in VAC group only 13.33% in 7 <sup>th</sup> and 8 <sup>th</sup> week as compared to 33.33% and 26.67%. 40% of the cultures in VAC group had no growth as 20% in control group

In the present study initial average wound surface area was 103.07 and which significantly was reduced to 94.53 cms over a period of 31 days as shown in Table 2. This showed satisfactory wound healing after VAC therapy with mean reduction of size 9.53 cms this results parallels the finding of other Indian and International authors as shown in Table 3. Management of wound bed and good healthy granulation tissue in the bed prevent wound complications thereby preventing amputations. Rate of wound closures and growth of granulation were also comparable to that of available literature. VAC dressing in our study showed comparable wound reduction with an average wound size reduction of around 9.53 cms over the duration of 30 days.

### Conclusion

VAC therapy is newer and a safe method of treatment for Diabetic Foot Ulcers. There is faster wound healing, good graft and flap take and lesser duration of hospital stay with minimal or no complications. So it is efficacious in the treatment for diabetic foot ulcers.

### References

1. IDF Diabetes Atlas. Eighth Edition. Brussels, Belgium. International Diabetes Federation, 2017. <http://www.diabetesatlas.org>.
2. Amit Kumar Jain C, Ajit Kumar Varma, Mangalanandan, Harish Kumar. Major Amputations in Diabetes – An Experience from a Diabetic Limb Salvage Centre in India. The Journal of Diabetic Foot Complications. 2012; 4(3):63-66.
3. Brem H, Sheehan P, Rosenberg HJ, Schneider JS, Boulton AJ. Evidence-based protocol for diabetic foot ulcers. Plast Reconstr Surg. 2006; 117(7):193S-209S.
4. Eldor R, Raz I, Ben Yehuda A, Boulton AJ. New and experimental approaches to treatment of diabetic foot ulcers: a comprehensive review of emerging treatment strategies. Diabet Med. 2004; 21(11):1161-73.
5. Dyson M. Adjuvant therapies, ultrasound, laser therapy, electrical stimulation, hyperbaric oxygen and VAC-therapy. In: Morrison MJ, Moffatt CJ, Franks PJ (eds) Leg ulcers: a problem-based learning approach. Mosby, Elsevier, Philadelphia, 2007, 429-51.

6. Rinaldi F, Alberetto M, Pontiroli A. The diabetic foot. General consideration and proposal of a new therapeutic and preventive approach. *Diabetes Res Clin Pract.* 1993; 21(1):43-49.
7. Argenta LC, Morykwas MJ. Vacuum-assisted closure: a new method for wound control and treatment: clinical experience. *Ann Plast Surg.* 1997; 38(6):563-76.
8. Morykwas MJ, Argenta LC, Shelton-Brown EI, McGuirt W. Vacuum-assisted closure: a new method for wound control and treatment: animal studies and basic foundation. *Ann Plast Surg.* 1997; 38(6):553-62.
9. Nikunj Vaidhya, Arpit Panchal, Anchalia MM. A new cost-effective method of NPWT in diabetic foot wound. *Indian J Surg.* 2015; 77(2):S525-S529.
10. Blume PA, Walters J, Payne W, Ayala J, Lantis J. Comparison of negative pressure wound therapy using V.A.C.uum-assisted closure with advanced moist wound therapy in the treatment of diabetic foot ulcers: a multicentre randomized controlled trial. *Diabetes Care.* 2008; 31:631-36.
11. Borgquist O, Ingemansson R, Malmsjo M. Wound edge microvascular blood flow during negative-pressure wound therapy: examining the effects of pressure from -10 to -175 mm Hg. *Plast Reconstr Surg.* 2010; 125(2):502-09.
12. The science behind VAC therapy. [http://www.kci-medical.in/IN-ENG/science behindvactherapy](http://www.kci-medical.in/IN-ENG/science%20behindvactherapy). Accessed 1, 2012.
13. Eginton MT, Brown KR, Seabrook GR, Towne JB, Cambria RA. A prospective randomized evaluation of negative-pressure wound dressing for diabetic foot wounds. *Ann Vasc Surg.* 2003; 17:645-49.
14. Nather A, Chionh SB, Han AY, Chan PP, Nambiar A. Effectiveness of V.A.C. uum-assisted closure (V.A.C.) therapy in the healing of chronic diabetic foot ulcers. *Ann Acad Med Singapore.* 2010; 39:353-58.
15. McCallon SK, Knight CA, Valiulus JP, Cunningham MW, McCulloch JM, Farinas LP. V.A.C.uum-assisted closure versus saline-moistened gauze in the healing of postoperative diabetic foot wound's. *Ostomy Wound Manage.* 2000; 46:28-32.
16. Armstrong DG, Lavery LA. Diabetic foot study consortium. Negative pressure wound therapy after partial diabetic foot amputation: a multicentre, randomized controlled trial. *Lancet.* 2005; 366:1704-10.
17. Luca Dalla Paola, Anna Carone, Silvia Ricci, Andrea Russo, Tania Ceccacci, Sasa Ninkovic. Use of vacuum assisted closure therapy in the treatment of diabetic foot wounds. *The J. Diabetic Foot Compl.* 2010; 2(2):33-44.
18. Nain PS, Uppal SK, Garg R, Bajaj K, Garg S, Role of negative pressure wound therapy in healing of diabetic foot ulcers. *J. Surg. Tech. Case Rep.* 2011; 3(1):17-22.
19. Ashok Swaminathan Govindarajan, Subramanian CS. Do's and don't's for prevention of Diabetic Foot Ulcer (DFU). *Int. J Curr. Med. Pharm. Res.* 2016; 2(12)1115-1118.