



International Journal of Surgery Science

E-ISSN: 2616-3470

P-ISSN: 2616-3462

© Surgery Science

www.surgeryscience.com

2020; 4(2): 109-113

Received: 23-02-2020

Accepted: 24-03-2020

Dr. Pradip Sandipan Kasabe

Department of General Surgery, Dr
V. M. Govt. Medical College and
General Hospital, Solapur,
Maharashtra, India

Dr. Mohit Rajan Relekar

Department of General Surgery, Dr
V. M. Govt. Medical College and
General Hospital, Solapur,
Maharashtra, India

Comparison of Alvarado score and ultrasonography in diagnosis of acute appendicitis

Dr. Pradip Sandipan Kasabe and Dr. Mohit Rajan Relekar

DOI: <https://doi.org/10.33545/surgery.2020.v4.i2b.405>

Abstract

Background: Appendicitis is a common cause of acute abdomen in all age groups and a simple appendicitis can progress to perforation which is associated with much higher morbidity and mortality. Acute appendicitis is the most common surgical condition and appendectomy is the most common operation done on emergency basis. This study aims at studying diagnostic accuracy of ultrasonography and Alvarado score for acute appendicitis and decreasing the negative appendectomy rate in cost effective manner.

Methods: In all 200 patients suspected to have acute appendicitis were examined and evaluated with modified Alvarado scoring and ultrasonography. Accuracy of alvarado scoring and ultrasonography in diagnosing acute appendicitis was calculated after correlating with the histopathological finding.

Results: The sensitivity and specificity of clinical diagnosis i.e modified alvarado scoring and ultrasonography were 89.17, 44.44 and 94.26, 88.88 respectively.

Conclusion: The diagnostic accuracy of clinical diagnosis was 84.57 and that of ultrasonography was 88%. Thus ultrasonography may be suggested as a useful diagnostic method for acute appendicitis. However the difference in their diagnostic values is not statistically significant.

Keywords: Appendicitis, ultrasound, alvarado score, diagnostic accuracy

Introduction

Acute appendicitis and the subsequent appendectomy are the most familiar surgical phenomenon for the general population and is considered a common surgical procedure^[1]. Lifetime risk of developing appendicitis is of 7 %. Highest frequency is seen in second and third decade of life with risk gradually decreasing until age of 50, when it stabilizes^[2]. Numerous advances in the diagnosis and treatment of appendicitis have emerged in the past 125 years. Nonetheless, acute appendicitis continues to challenge surgeons to this day. Acute appendicitis presenting in a typical fashion may be diagnosed with relatively ease, these typical presentations are exceptions and not the rule. Typical symptoms and laboratory investigation may not be seen in 20-33 % patient with this disease^[2, 3]. Various aetiologies have been proposed for acute appendicitis^[4] but most common accepted hypothesis is obstructive cause due to faecolith in adults and lymphoid hyperplasia in children^[5]. Acute appendicitis presenting in a typical fashion may be diagnosed with relatively ease, these typical presentations are exceptions and not the rule. Typical symptoms and laboratory investigation may not be seen in 20-33 % patient with this disease^[6, 7]. The accurate pre-operative diagnosis of acute appendicitis remains an enigmatic challenge. Nowadays commonly used diagnostic aids for appendicitis are CECT abdomen, laparoscopy, diagnostic scores and ultrasonography^[8].

Patients are more likely to perforate if they do not present to the hospital promptly^[9] but even when they do, late diagnosis by medical professionals may also lead to delayed surgery and therefore potential rupture. Thus, every effort must be made to have a patient diagnosed correctly and undergo treatment in an expeditious manner.

Various score have been devised for diagnosis of acute appendicitis but out of them the Alvarado score is a reliable, cheap and reproducible tool for the diagnosis of acute appendicitis in the emergency room^[10]. Ultrasonography helps to diagnose acute appendicitis and is advantageous over other radiological investigation like Computer Tomography scan and Magnetic resonance Imaging as it is easily available, is cost effective, portable, has no side effects and is non invasive.

Corresponding Author:

Dr. Mohit Rajan Relekar

Department of General Surgery, Dr
V. M. Govt. Medical College and
General Hospital, Solapur,
Maharashtra, India

Materials and methods

Out of the total patients admitted with clinical suspicion of acute appendicitis or appendicular perforation under surgery department between October 2017 to October 2019 in our institute, 200 patients are randomly selected and included in this study. Detailed clinical history of patients was taken and every patient was examined in detail. Blood samples were collected from the patient and sent for complete blood count with

haemoglobin, biochemical investigations, Human immunodeficiency virus, hepatitis Bs Ag, blood grouping and cross match. Alvarado scoring was used and score was calculated for individual patient. Alvarado score is a 10 point scoring system for the diagnoses of acute appendicitis based on clinical features and investigations. In his original paper he recommended an operation for all the patients with score of 7 or more and observations for patients with 5 or 6 ^[11].

Modified Alvarado Score

	Manifestations	Value
Symptoms	Migration of pain	1
	Anorexia	1
	Nausea and/or vomiting	1
Signs	Right lower quadrant tenderness	2
	Rebound	1
	Elevated temperature	1
Laboratory values	Leukocytosis	2
	Left shift in leukocyte count	1
		Total points 10

Appendicitis in ultrasonography is considered positive if anteroposterior diameter of equal to or greater than 7 mm, non compressible appendix, interruption of continuity of mucosa, free fluid, periappendicular mass, increased echogenicity of mesentery, presence of faecolith. Patients were operated in conventional manner or laproscopically. Patients who underwent surgery were only included in this study.

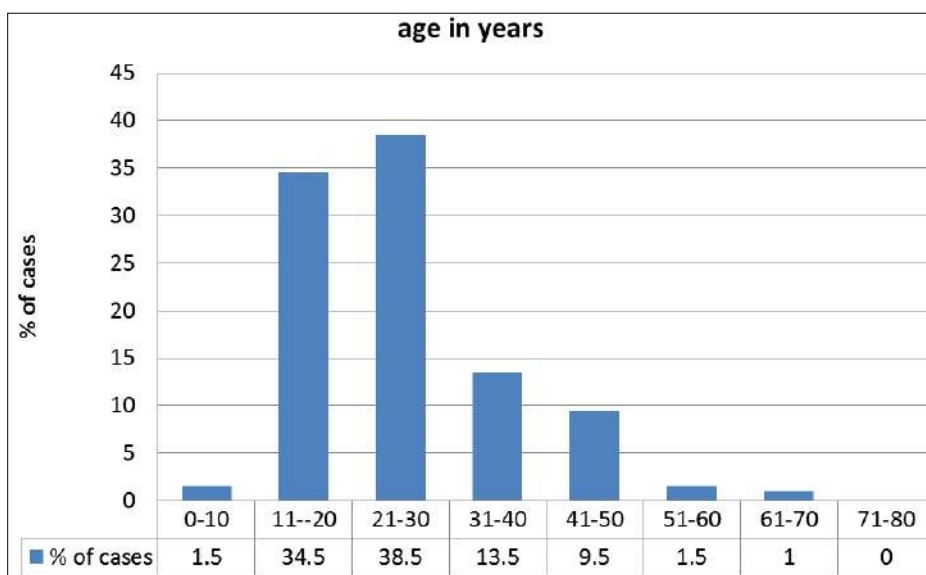
Histopathological report of all operated cases were noted in the study. Final diagnosis of acute appendicitis was confirmed only after histopathological report. Accuracy, sensitivity and specificity of ultrasound and clinical diagnosis was calculated.

Statistical Method

Significance of accuracy is tested by Z test for difference between two proportions.

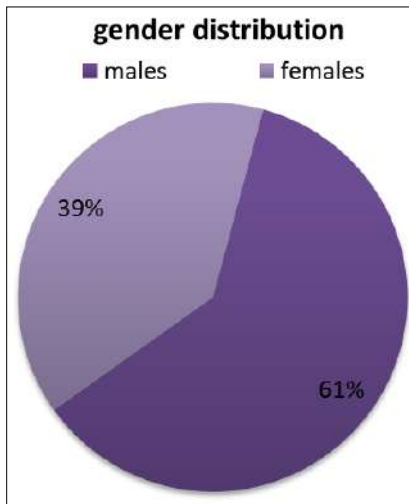
Results

The maximum incidence of appendicitis was found in the group 21- 30 years (38.5%). The youngest patient was 9 years old and the oldest was of 61 years old. When the incidence of cases between 11-30 years is seen together then it comprises of 73% of patients.



Graph 1: Age wise distribution of cases

In the present study the number of male patients and female patients was 122 and 78 respectively. The male: female ratio was found to be 1.5:1.



Graph 2: Gender distribution of cases

Table 1: Clinical presentation of patients with clinical diagnosis of acute appendicitis

Symptoms	Total number of cases	Percentage
Pain in right iliac fossa	200	100
Shifting of pain	136	68
Fever	163	82.5
Nausea and Vomiting	149	74.5
Anorexia	156	78
Tenderness	197	98.5
Rebound Tenderness	149	74.5

In the present study, pain in right iliac fossa is basic criteria to include the patient in this study. The second most common symptom after pain in right iliac fossa was fever which was seen in 82.5 % of cases.

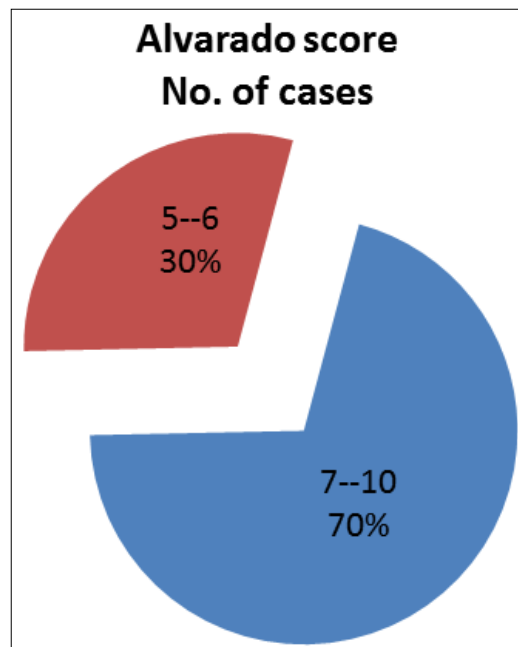
The most consistent sign was tenderness in right iliac fossa, it was seen in 197 cases out of 200 i.e. 98.5 % of patients who are suspected of having acute appendicitis.

Table 2: Observed Ultrasonography findings in all cases

Usg Findings	No. of Cases	Percentage
Acute Appendicitis with Target Lesion 7 Mm or More	140	70
Acute Appendicitis with Target Lesion Less Than 7mm	19	9.5
Appendicular Perforation	22	11
Non Inflamed Appendix	19	9.5

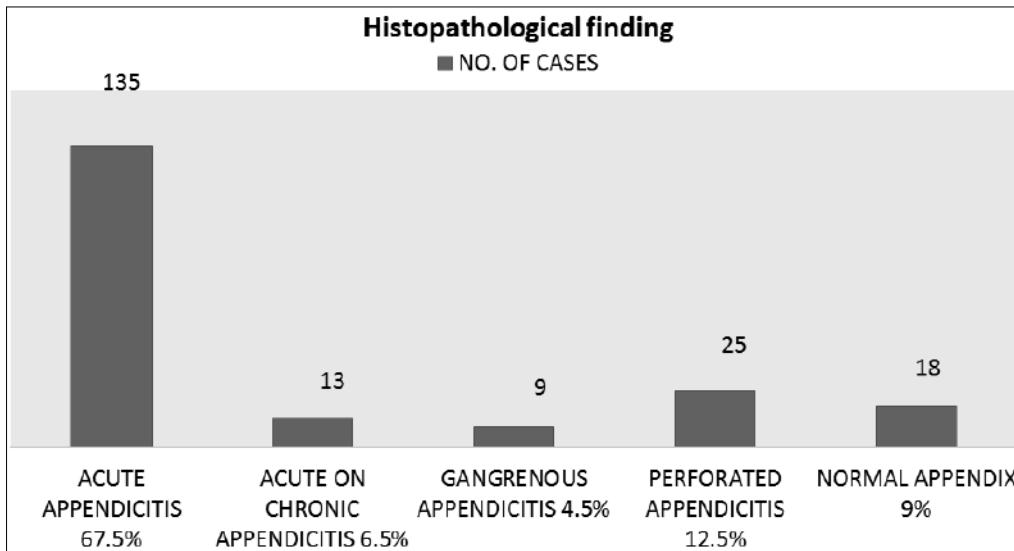
Out of the total 200 cases with clinical suspicion of acute appendicitis, 140 patients had ultrasonography suggestive of acute appendicitis with target lesion more than 7 mm while 19 patients had ultrasonography showing acute appendicitis with target lesion less than 7 mm i.e. 5 or 6 mm. None of the cases

showed acute appendicitis with target lesion less than 5 mm. In 10 % of the cases, appendicular perforation was diagnosed on ultrasonography. 19 out of the total 200 cases showed no appendicular inflammation on ultrasonography.



Graph 3: Alvarado score distribution among all the cases

In this study, Alvarado score was equal to or above 7 in 140 patients and it was 5-6 in 60 patients. There was no patient who had Alvarado score between 1- 4.



Graph 4: Histopathological report

Out of the 200 cases which were operated, 18 cases were reported as normal appendix which makes the rate of negative appendicectomies of our study to be 9 %. Perforated appendicitis was reported in 12.5 % of the cases i.e. 25 out of total 200 cases.

Discussion

Despite its high prevalence, the diagnosis of acute appendicitis can be challenging and requires a high index of suspicion on the part of the examining surgeon to facilitate prompt treatment of this condition, thereby avoiding the substantial morbidity (and even mortality) associated with perforation. Total incidence of appendicitis in the age group of 11-30 years of age is found to be 73% in our study. In Busuttill series of 136 patients had 72% patients in second and third decade of life [12]. In the present study male predominance was found amounting to 61% of the total cases making the male to female ratio for incidence of acute appendicitis to be 1.5:1. It is comparable to the study conducted by John Berry and Malt which showed similar results [13]. In study conducted by Zarandi *et al.* they observed 67% males and 33% females and the ratio was 2:1 [14]. Ira Teicher *et al.* demonstrated male to female ratio as 2:1 [15]. Mark C. Horatta, found that there was no gender predominance among males and females [16]. A male preponderance exists, with a male to female ratio of 1.4:1 according to study done by Addiss DG *et al.* [17].

In our study, out of the total 200 cases operated, 19 had normal appendix on histopathological examination which makes the negative appendectomy rate of 9.5 % which is comparable to other studies. In a study conducted by Yara F. Alhamdani (n=441) [18] negative appendectomy rate was reported to be 9.5% while in a study by Tanrikulu *et al.* [19] the rate was found to be 8.2%. E.P. Johansson (n=305) reported a negative appendectomy rate of 9% [20].

Table 3: Correlation of ultrasonography findings with HPE

In present study	Appendix on histopathology	
	Confirmed appendicitis	Normal appendix
Positive	148	3
Negative	9	16

In our study, the sensitivity and specificity of ultrasonography in detecting acute appendicitis is found to be 94.2% and 84.2%

respectively. The sensitivity for USG was 98.33% and specificity was 90% in a study conducted by N. Gujar *et al.* [21]. In a study done by Al-Ajerami Y [22] (n=180) sensitivity and specificity were found to be 84.8% and 83.3% respectively. Sensitivity and specificity of 87% and 74% was reported in a study by Pickuth *et al.* (n=120) [23].

Table 4: Correlation of Alvarado score diagnosis with HPE

Acute appendicitis	Histopathological report	
	Positive	Negative
Alvarado scoring system		
Positive	140	10
Negative	17	8

In our study the sensitivity and specificity of Alvarado score for acute appendicitis was 89.17 % and 44.4 % respectively. The sensitivity and specificity of modified Alvarado score was 98.44% and 94.4% for Alvarado score in a study done by N. Gujar *et al.* [21]. The overall sensitivity, specificity of Alvarado score in a study conducted by Jalil A *et al.* [24]. Sensitivity and specificity of the Alvarado scoring system were found to be 93.5% and 80.6% respectively by Memon ZA *et al.* [25].

Conclusion

Thus, Sensitivity and specificity of Alvarado score for acute appendicitis was 89.17 % and 44.4 % respectively. The sensitivity and specificity of ultrasonography was 94.2% and 84.2% respectively. Diagnostic accuracy of alvarado score and ultrasound for diagnosing acute appendicitis was found to be 89.67% and 93.18% respectively.

Thus ultrasonography has higher accuracy in diagnosing acute appendicitis. However, statistically there is no significant difference observed in the diagnostic accuracy of ultrasonography and clinical diagnosis. (z=1.25, p>0.05)

In conclusion, ultrasonography may be suggested as a useful diagnostic method for acute appendicitis given the availability, cost and low exposure to ionizing radiation. Non-visualization of the appendix should lead to clinical reassessment.

References

- Ming PC, Yan TY, Tat LH. Risk factors of postoperative infections in adults with complicated appendicitis. *Surgical Laparoscopy Endoscopy & Percutaneous Techniques*. 2009; 19(3):244-8.

2. Addiss DG, Shaffer N, Fowler BSTR. the epidemiology of appendicitis and appendectomy in the united states. *Am J epidemiol.* 1990; 132:910-25.
3. Williams NS, Bulstrode CJKOP. *Bailey and Love's short practice of surgery*, 2008, 1205p.
4. Williams NS, Bulstrode CJKOP. *Bailey and Love's short practice of surgery*, 2008, 1205p.
5. Micheal J, Quillan Y, David M, Justin MSB. Association between the appendix and the fecolith in adults. *Can j surg.* 2015; 58(1):10-4.
6. Kirkil C, Karabulut K, Aygen E, Ilhan YS, Yur M *et al.* Appendicitis scores may be useful inreducing the costs of treatment for right lower quadrant pain. *Ulus Trauma Acil Cerrahi Derg.* 2013; 19(1):13-9.
7. Velanovich V SR. Balancing the normal appendectomy rate with the perforated appendicitis rate: implications for quality assurance. *Am Surg.* 1992; 58(4):264-9.
8. Hemant Nautiyal, Shabi Ahmad, Keshwani NK, Awasthi DN. Combined use of modified Alvarado score and USG in decreasing negative appendisectomy rate. *Indian Journal of Surgery.* 2010; 72(1):46-52.
9. Erasmus JPF. The incidence of appendicitis in the Bantu. *S Afr J Surg.* 1939; 13:601-7.
10. Pouget-Bauddy Y, Mucci S, Eyassartier E, Uesdon-Portes AG, Lada P, Casa C *et al.* the use of Alvarado score in the management of right lower quadrant abdominal pain in the adults. *J Visc Surg.* 2010; 147:40-4.
11. Alvarado A. A practical score for the early diagnosis of acute appendicitis. *Ann Emerg Med.* 1986; 15:557-64.
12. Busuttill RW, Davison RK, Fine Marjorie TR. Effect of prophylactic antibiotics in acute non-perforated appendicitis. *Ann Surg.* 1985; 194:502-8.
13. Berry and Malt: Appendicitis near its centenary, *Ann. Surg.* 1984; 200(5):567-574.
14. Zarandi NP, Parsijani PJ, Bolandparvaz S, Paydar S. Accuracy of Surgeon's Intraoperation Diagnosis of Acute Appendicitis, Compared with the Histopathology Results. *Bull Emerg Trauma.* 2014; 22(11):15-2115.
15. Ira Teicher, Landa B, Cohen Martin, Canbik LS W. Scoring system to aid in diagnosis of appendicitis. *Ann Surg.* 1983; 198:753-9.
16. Horattas C *et al.* Reappraisal of appendicitis in elderly, *Am. J Surg.* 1990; 160:291-293.
17. Addiss DG, Shaffer N, Fowler BS, Tauxe RV. The epidemiology of appendicitis and appendectomy in the United States. *Am J Epidemiol.* 1990; 132:10-25.
18. Yara Alhamdani F *et al.* Negative Appendectomy Rate and Risk Factors That Influence Improper Diagnosis at King Abdulaziz University Hospital. *Mater Sociomed.* 2018; 30(3):215-220.
19. Tanrikulu CŞ, Karamercan MA, Tanrikulu Y, Öztürk M, Yüzbaşıoğlu Y, Coşkun F. The predictive value of Alvarado score, inflammatory parameters and ultrasound imaging in the diagnosis of acute appendicitis. *Turkish J Surg.* 2016; 32(2):115-21.
20. Johansson EP, Rydh A, Åhlström Riklund K. Ultrasound, Computed Tomography, and Laboratory Findings in the Diagnosis of Appendicitis, *Acta Radiologica.* 2007; 48(3):267-273, DOI: 10.1080/02841850601182162
21. Gujar NN, Mudhol Sajid, Choudhari Ravi, Sachin DM. Determination of Sensitivity and Specificity of Modified Alvarado Score and Ultrasonography in Patients with Acute Appendicitis. *Journal of Krishna Institute of Medical Sciences University.* 2015; 4:89-99.
22. Al- Ajerami Y. Sensitivity and specificity of ultrasound in the diagnosis of acute appendicitis. *East Mediterr Health J.* 2012; 18(1):66-9.
23. Pickuth D, Heywang-Köbrunner SH, Spielmann RP. Suspected acute appendicitis: is ultrasonography or computed tomography the preferred imaging technique? *Eur J Surg.* 2000; 166(4):315-9.
24. Jalil A, Shah SA, Saaiq M, Zubair M, Riaz U, Habib Y. Alvarado scoring system in prediction of acute appendicitis. *J Coll Physicians Surg Pak.* 2011; 21(12):753-5. doi: 12.2011/JCPSP.753755
25. Memon ZA, Irfan S, Fatima K, Iqbal MS, Sami W. Acute appendicitis: diagnostic accuracy of Alvarado scoring system. *Asian J Surg.* 2013; 36(4):144-9. doi: 10.1016/j.asjsur.2013.04.004. Epub 2013 May 28.