



# International Journal of Surgery Science

E-ISSN: 2616-3470

P-ISSN: 2616-3462

© Surgery Science

[www.surgeryscience.com](http://www.surgeryscience.com)

2020; 4(3): 08-11

Received: 04-05-2020

Accepted: 06-06-2020

**Dr. SM Fulare**

Dept. of General Surgery, NKP  
Salve Institute of Medical Sciences,  
Nagpur, Maharashtra, India

**Dr. SD Deshmukh**

Dept. of General Surgery, NKP  
Salve Institute of Medical Sciences,  
Nagpur, Maharashtra, India

**Dr. Jyoti Gupta**

Dept. of General Surgery, NKP  
Salve Institute of Medical Sciences,  
Nagpur, Maharashtra, India

**Dr. S Chowksey**

Dept. of General Surgery, NKP  
Salve Institute of Medical Sciences,  
Nagpur, Maharashtra, India

**Corresponding Author:**

**Dr. SD Deshmukh**

Dept. of General Surgery, NKP  
Salve Institute of Medical Sciences,  
Nagpur, Maharashtra, India

## Giant lipoma of head and neck region: A case series

**Dr. SM Fulare, Dr. SD Deshmukh, Dr. Jyoti Gupta and Dr. S Chowksey**

**DOI:** <https://doi.org/10.33545/surgery.2020.v4.i3a.460>

### Abstract

Lipomas, also known as “universal tumours” are benign soft tissue tumour of mesenchymal origin occurring in approximately 1% of the population, 13% of all the lipomas are reported to be in the head and neck region. Knowing the universal nature of the tumour, in most cases there is no diagnostic dilemma and an accurate clinical diagnosis can be made. However, large swelling, especially of the head and neck region arise the suspicion of malignancy. The primary diagnostic challenge is to differentiate a lipoma from other malignant lesions, specially a well-circumscribed liposarcoma. Diagnostic imaging like X-ray, Ultrasound, CT Scan and MRI are helpful in evaluating these swellings and confirming the diagnosis and deciding the course of further management. In this case series we have reported three cases of giant lipoma of head and neck region.

**Keywords:** Giant lipoma, head and neck, diagnostic imaging, surgical management

### Introduction

Lipomas are benign soft tissue tumour of mesenchymal origin occurring in approximately 1% of the population. They are often small, solitary, slow growing tumours and are typically asymptomatic. Presentation of a lipoma can be anywhere in the body where adipose tissue is present. Majority of the lipomas are seen in the extremities, upper back and trunk region, 13% of them have been reported to form on head and neck region. Most lipomas are around two centimeters in diameter and weigh around hundred grams. A “giant lipoma” has a size that is greater than 10 cm in at least one dimension or weighs over 1000 grams. In this case series we have reported three cases of soft tissue swellings of head and neck region which were finally diagnosed as lipomas.

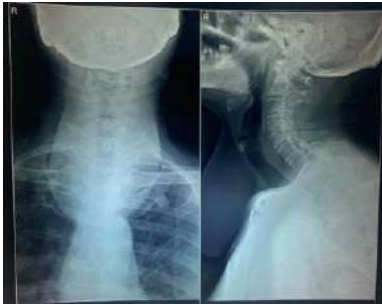### Case series

#### Case 1

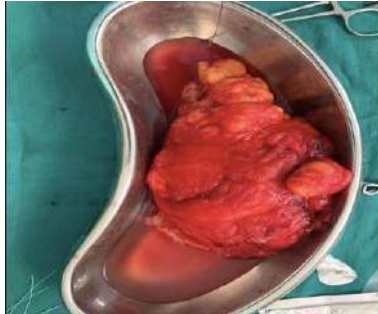
A healthy male of 70 years age presented to surgery OPD with swelling in anterior aspect of neck since 10 years. The swelling was slow growing, painless, with no overlying skin changes. The patient did not seek medical attention for the same before as the swelling was asymptomatic. The patient did not complain of weight changes, fatigue, heat or cold intolerance, palpitations or tremors, excessive sweating, generalized weakness or exertional dyspnea. Also, the patient denied any history of fever, voice changes or difficulty in swallowing. There was no family history of thyroid disorders. Rest of the history was unremarkable to our case.

On general examination, the patient was afebrile, hemodynamically stable, with a BMI of 21.6. Physical examination revealed a solitary, globular swelling of 10 X 6 cm in anterior aspect of neck. The swelling was soft to firm in consistency, freely mobile, did not move with protrusion of tongue or deglutination. There were no changes or fixity of the overlying skin or any signs of inflammation. Cervical or supra-clavicular lymph nodes were not palpable.

Hematological investigations including blood thyroid profile were within normal limits X-Ray neck lateral view was suggestive of soft tissue swelling on anterior aspect of neck. Ultrasonography of neck revealed a well-defined, heterogeneous, predominantly hyper-echoic lesion of 10.4 X 4.3 X 3.2 cm noted in the sub-cutaneous plane extending superiorly from supra-thyroid region up to inferior aspect of sternal notch. No evidence of vascularity was noted within the mass and above features were likely to be suggestive of soft tissue swelling. FNAC was suggestive of lipoma. The soft tissue swelling was excised and histopathological report revealed features consistent with lipoma. Post-operative recovery of the patient was uneventful.



**Image 1:** pre-operative X-ray neck.



**Image 2:** surgically excised specimen

**Case 2**

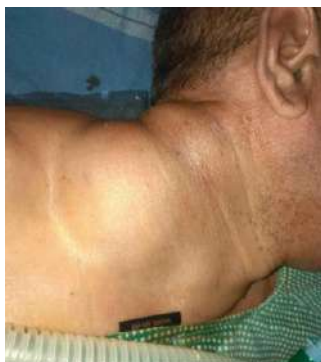45 years old male patient presented with chief complaints of swelling over right lateral aspect of neck since 7 years. The swelling was not associated with pain, any discharge or difficulty in neck movement. The patient did not complain of fever, chills, evening rise of temperature, chronic cough, weight loss or difficulty in swallowing. Rest of the history was unremarkable.

On general examination the patient was well built with a BMI of 26.7 and all vital signs were within normal limit.

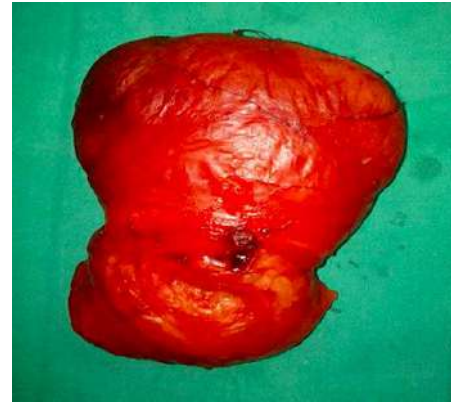Physical examination revealed a solitary, well defined globular swelling of 12 X 5 cm with palpable margins. The swelling was soft in consistency, not attached to underlying structures or overlying skin, with no evidence of any discharge or any signs of inflammation. On auscultation, no bruit was heard. Cervical or supra-clavicular lymph nodes were not palpable. FNAC was suggestive of lipoma.

Ultrasonography revealed a well-defined, echogenic lesion of in the sub-cutaneous plane superior to clavicle. No evidence of vascularity was noted within the mass and features were suggestive of soft tissue swelling, most likely to be lipoma.

The mass was excised surgically and there was no involvement of sterno-cleidomastoid muscle or carotid sheath vessels. Histopathological examination was suggestive of lipoma. Post-operative recovery of the patient was uneventful.



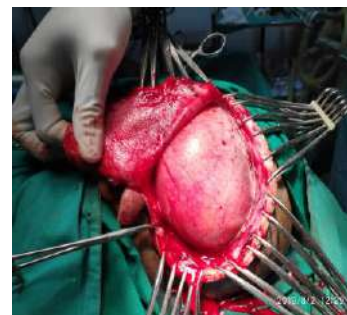**Image 3:** swelling over right lateral aspect of neck



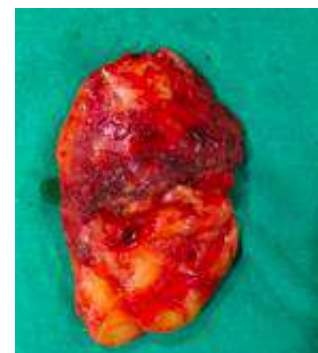**Image 4:** surgically excised specimen

**Case 3**

A 52-year old male patient presented with a swelling over his left temporal region since 2 years which was gradually increasing in size. It was not associated with pain and there was no limitation in mouth opening. CT scan of head was done to rule out any intracranial extension. Computed tomography report suggested a well-defined lesion in the left temporal region, attenuation was suggestive of fat. The lesion had well-defined margins with no muscular invasion, no intralesional septations and no intracranial extensions. FNAC of the swelling was done which showed adipose tissue, suggestive of lipoma. The swelling was surgically excised under general anaesthesia. A hemi-coronal approach was made followed by dissection of the subcutaneous layer and identification of the lesion's capsule. During the dissection, it was found that the swelling was underneath the temporalis fascia and above the temporalis muscle and was not adherent to any structure. The swelling was sent for histopathological examination and diagnosis of lipoma was confirmed. Post-operative recovery of the patient was uneventful and there was no recurrence in the follow up period of one year.



**Image 5:** intra- operative image of excision of swelling



**Image 6:** surgically excised specimen

## Discussion

Lipomas are most common benign neoplasm of mesenchymal origin. They are also known as “universal tumour” as they may arise in any region of the body where adipose tissue is present. Lipomas are composed of mature fat cells and occur predominantly on extremities (34%), shoulder (21%), abdomen (19%), and upper back (18%). Only 13% of lipomas are seen in head and neck region, with posterior aspect of neck being the most common site. Patient with lipoma generally present as painless, well-circumscribed mass with slow and gradual progression in size. Clinical symptoms mainly depend on the size, location, rate of growth of swelling and pressure symptoms on the surrounding structures. Patients generally present to the OPD for aesthetic concerns and risk of malignancy. The mean duration between time of discovery of swelling and treatment is 2 years, although this duration decreases significantly in case of head and neck lipomas. A study conducted to assess the same by Furlong on 125 cases of head and neck lipoma, the mean duration between lipoma discovery and excision was 1.2 years.

The aetiology behind lipomas are not clearly annotated yet, although heredity, obesity, diabetes, trauma, radiation, endocrine disorder, insulin injection and corticosteroid therapy are often implicated as possible etiological factor. Furthermore, as described in literature, lipomas can be associated with syndromes such as adiposis dolorosa, multiple lipomatosis, Gardner’s syndrome and Madelung’s disease, Bannayan-zonana syndrome. The conversion rate of a benign lipoma into malignant tumour is very rare. The presence of an intramuscular lipoma, lipoma in internal organs have been described as a risk factor for malignancy.

Keeping the universal nature of the tumour in mind, in most cases there is no diagnostic dilemma and an accurate clinical diagnosis can be made. However, large, rapidly growing swelling, especially of the head and neck region arise the suspicion of malignancy. The primary diagnostic challenge is to differentiate a lipoma from other malignant lesions, specially a well-circumscribed liposarcoma which is precisely the reason for reporting above cases. Around 2-8% of liposarcomas are present in head and neck region. The differentiating features between lipoma and malignant swellings are size, location, well-defined margins, bony invasion, neuro-vascular bundle involvement and signal intensity on imaging studies.

The differential diagnoses of a painless mass in head and neck region include lymphadenopathy, sebaceous cysts, dermoid cysts, neurogenic tumours, tumours of salivary gland, thyroglossal cyst, ectopic thyroid nodule, benign or malignant enlargement of thyroid gland, carotid aneurysm, branchial cleft cysts, vascular leiomyomas, hibernoma, spindle cell lipoma, liposarcoma and trichilemmal cysts.

Diagnostic imaging like X-ray, Ultrasound, CT Scan and MRI are helpful in evaluating these swellings and confirming the diagnosis. Also, these imaging modalities help to differentiate lipomas from other malignant tumours. In ultrasound, the lesion will be hyper-echoic with well differentiated margins. In CT and MR imaging, the signal intensity of lipomas will be similar to that of sub-cutaneous fat and they appear as homogenous, hypo-attenuated lesions. These imaging modalities also help in knowing the exact location of the swelling and its relation to surrounding structures. Pathological diagnosis like FNAC is also helpful in diagnosis although confirmation of diagnosis is achieved after histopathological evaluation of excised mass. Macroscopically, lipomas are usually soft, well-circumscribed masses featuring a yellow cut surface. They mostly have a thin capsule. Lipomas are composed of lobules of uniform, mature

adipose tissue. Differentiating a lipoma from a well-differentiated liposarcoma can be challenging. The absence of vacuoles in the irregularly shaped nuclei and increased size of the cells may be helpful for diagnosis of a well differentiated liposarcoma.

The fundamental question arises regarding the surgical management of such swellings: Is it necessary to excise all lipomas of head and neck region? In all the three cases reported above, surgical excision was done for aesthetic and functional reasons. During excision, surgeon should be careful to remove the tumour in its entirety with capsule to prevent recurrence. After excision local recurrence percentage is less than 5%. The infiltrated lipomas have higher recurrence percentage than small solitary lipomas. Other complications after excision of a lipoma are hematoma formation, seroma, ecchymosis, surgical site infection, excessive scarring and injury to surrounding structures.

## Conclusion

A wide range of soft tissue tumors may arise in the head and neck region. Most of these tumors are benign. Few malignant and locally aggressive soft tissue tumors do occur which can cause substantial morbidity and mortality. Detailed history, clinical examination and imaging can help differentiate lipomas from other soft tissue tumours and thus help in chalking out the most appropriate treatment option.

## Reference

1. Kransdorf MJ. Benign soft-tissue tumors in a large referral population: Distribution of specific diagnoses by age, sex, and location, *American Journal of Roentgenology*. 1995; 164(2):395-402,
2. El-Monem MHA, Gaafar AH, Magdy EA. Lipomas of the head and neck: Presentation variability and diagnostic work-up, *Journal of Laryngology and Otology*, 2006; 120(1):47-55
3. Copcu E, Sivrioglu N. Posterior cervical giant lipomas, *Plastic and Reconstructive Surgery*, 2005; 115(7):2156-2157.
4. Ali QE, Siddiqui OA, Amir SH, Azhar AZ, Ali K, Airtraq optical laryngoscope for tracheal intubation in a patient with giant lipoma at the nape: a case report, *Rev. Bras. Anesthesiol*. 2012; 62:736-740.
5. Jones AP, Lewis CJ, Dilley P, Hide G, Ragbir M. Lipoma or liposarcoma? A cautionary case report, *Journal of Plastic, Reconstructive and Aesthetic Surgery*. 2012; 65(1):e11–e14,
6. Moumoulidis I, Durvasula P, Jani P. Well-circumscribed intramuscular lipoma of the sternocleidomastoid muscle. *Auris Nasus Larynx*. 2004; 31:283-85.
7. Özcan C, Görür K, Talas D, Aydin ö. Intramuscular benign lipoma of the sternocleidomastoid muscle: a rare cause of neck mass. *Eur Arch Otorhinolaryngol*. 2005; 262:148-50.
8. Enzinger FM, Weiss SW. Benign lipomatous tumors. In: Enzinger FM, Weiss SW, editors. *Soft tissue tumors*. 3rd edn. St Louis: Mosby, 1995, 381-430.
9. Barnes L. Tumors and tumorlike lesions of the head and neck. In: Barnes L, editor. *Surgical Pathology of the Head and Neck*. New York: Dekker, 1985.
10. Medina CR, Schneider S, Mitra A, Spears J, Mitra A. Giant submental lipoma: Case report and review of the literature. *Can J Plast Surg*. 2007; 15:219-22.
11. Ryu JW, Lee MC, Myong NH *et al*. Lipoma of the parotid gland. *J Korean Med Sci*. 1996; 11:522-25.

12. Starkman SJ, Olsen SM, Lewis JE, Olsen KD, Sabri A. Lipomatous lesions of the parotid gland: analysis of 70 cases. *Laryngoscope*. 2013; 123:651-56.
13. Ahuja AT, King AD, Kew J, King W, Metreweli C. Head and neck lipomas: sonographic appearance. *AJNR Am J Neuroradiol*. 1998; 19:505-08.
14. Chikui T, Yonetsu K, Yoshiura K *et al*. Imaging findings of lipomas in the orofacial region with CT, US, and MRI. *Oral Surg Oral Med Oral Pathol Oral Radiol Endod*. 1997; 84:88-95.
15. El Monem MH, Gaafar AH, Magdy EA. Lipomas of the head and neck: presentation variability and diagnostic workup. *J Laryngol Otol*. 2006; 120:47-55.