



E-ISSN: 2616-3470

P-ISSN: 2616-3462

© Surgery Science

[www.surgeryscience.com](http://www.surgeryscience.com)

2021; 5(1): 18-21

Received: 06-11-2020

Accepted: 14-12-2020

**Dr. Akash Dua**

Assistant Professor, Department of Surgery, SGT Medical College Hospital and Research Institute, Budhera, Gurugram, Haryana, India

**Dr. PN Aggarwal**

Professor and HOD, Department of Surgery, SGT Medical College Hospital and Research Institute, Budhera, Gurugram, Haryana, India

## Role of laparoscopy in the management of chronic abdominal pain: A clinical study in north Indian teaching hospital

**Dr. Akash Dua and Dr. PN Aggarwal**

**DOI:** <https://doi.org/10.33545/surgery.2021.v5.i1a.581>

### Abstract

**Background:** Chronic abdominal pain can be diagnostic challenge. These difficult patients are frequently seen by many different physicians and are subjected to myriad of tests without identifying the etiology of pain. Surgical consultation often occurs late after other modalities have failed to provide resolution of their symptoms.

**Subjects and Methods:** This prospective study was conducted in the Department of Surgery, SGT Medical College Hospital & Research Institute, Budhera, Gurugram, Haryana, India. 48 Patients with chronic abdominal pain participate in this study. This study included patients presenting with history of nonspecific abdominal pain for 3 weeks or more who were admitted in surgical wards.

**Results:** The most common site of pain was the periumbilical region (52.08%) followed by the right lower abdominal quadrant (31.25%). Twenty two patients were using either non-steroidal drugs or pain killers to relieve the pain, and five patients were using proton pump inhibitors. Fifteen patients (31.25%) had undergone at least one previous surgical abdominal procedure. All patient characteristics are summarised in table 3. The average length of the operative time was 54.09 minutes with the range from 32 to 116 minutes. There were no cases converted to open procedures. Out the 48 patients with chronic abdominal pain, a definitive diagnosis was established in 46 patients (95.16%), while no identifiable cause could be reached in two patients (4.4%). The most common laparoscopic findings were adhesions (79.16%). Other findings included appendiceal pathology (10.41%), hernia (2.08%), gall bladder pathology (2.08%), and mesenteric lymphadenopathy (2.08%). Table 2 summarises the laparoscopic diagnoses assigned to all patients. Laparoscopic management included adhesiolysis [38], appendectomy [5], hernia repair [1], cholecystectomy [1], and lymph node biopsy [1]. Two patients had no interventions performed. Postoperative hospital stay ranged from two to twelve days with a mean of 3.8 days.

**Conclusion:** Although Chronic abdominal pain of unknown origin represents a significant problem in surgical patients. Due to improvement in instrumentation and greater experience in the laparoscopy, the procedure no longer limited to visualization. This study showed that laparoscopy is an effective approach in the management of patients with chronic abdominal pain in whom conventional methods of investigations have failed to elicit a certain cause.

**Keywords:** Laparoscopy, chronic abdominal pain, adhesions, diagnostic laparoscopy

### Introduction

The success of laparoscopy in making definite and reliable diagnosis of abdominal disorders over the past two decades, has firmly established it in the armamentarium of a general surgeon to perform this procedure safely. Despite this fact, general surgeons are still reluctant to use this method of diagnosis as often as they can. Diagnostic and therapeutic laparoscopy has its most important and ultimate application in the developing world. Less than 20% of the population in the developing world has access to imaging devices like ultrasound, CT scan, magnetic resonance imaging (MRI) or Doppler. By a happy paradox, vast areas of the developing world have access to a laparoscope, thanks largely to its use in widespread government-sponsored family planning campaigns in almost every developing country throughout the world. Chronic abdominal pain is a common disorder both in general practice and in hospitals. Chronic abdominal pain is defined as intermittent or constant abdominal pain of at least 3 months' duration. 20%-40% of the patients presenting with chronic abdominal pain have no specific etiology at the end of their diagnostic workup [1]. Although patients with this type of pain may have undergone numerous diagnostic workups, including surgery, their pain remains a challenge

**Corresponding Author:**

**Dr. PN Aggarwal**

Professor and HOD, Department of Surgery, SGT Medical College Hospital and Research Institute, Budhera, Gurugram, Haryana, India

to all known diagnostic and treatment methods.

Diagnostic laparoscopy allows a surgeon to directly view the types of abnormal abdominal contents that could be the cause of pain and which would not be otherwise diagnosed and it can exclude other causes of pain.

On the other hand, unnecessary laparotomy is painful, increases hospital stay, increases hospital cost and is associated with morbidity of 5% to 22% [2]. Diagnostic laparoscopy is a valuable technique for determining the cause of acute or chronic abdominal pain. Laparoscopy has a significant diagnostic and therapeutic role in patients with chronic abdominal pain besides an advantage of providing a final histologic diagnosis through target biopsies [3]. Aim of the present study was to know the role of diagnostic laparoscopy in the diagnosis and management of chronic abdominal pain.

### Subject and Methods

This prospective study was conducted in the Department of Surgery SGT Medical College Hospital & Research Institute, Budhera, Gurugram, Haryana, India. A total of 48 Patients with chronic abdominal pain participate in this study during the period August 2017 to July 2018. This study included patients presenting with history of nonspecific abdominal pain for 3 weeks or more who were admitted in surgical wards. After approval of our Ethics Committee of Department of Surgery SGT Medical College Hospital & Research Institute, Budhera, Gurugram, Haryana, India. All the patients underwent laparoscopic surgery for evaluation and management of their chronic abdominal pain. We defined chronic abdominal pain as a continuous or intermittent abdominal pain with daily intake of analgesics, and a duration of at least three months [4, 5]. Detailed history was recorded from patients and thorough clinical examination was performed. The findings were recorded in the proforma. The recorded data included demographics, duration of pain, location of pain, patient's abdominal examination and diagnostic studies performed. Routine hematological investigations *viz.* complete blood count, renal function tests and serum electrolytes were performed in all the patients along with urine routine and microscopy. Commonly performed imaging studies included plain abdominal radiography and ultrasounds studies. Barium studies were done where ever indicated. All the patients underwent diagnostic laparoscopy. Intraoperative findings and operative interventions undertaken were also recorded. According to the pathology various surgical methods were employed.

### Inclusion criteria

Patients with history of abdominal pain for three months or

more, if physical examination and diagnostic tests are inconclusive, Patients with history of previous abdominal surgeries, Chronic abdominal /pelvic pain and Infertility.

### Exclusion criteria

Age under 10 years, Patients with cancer, pregnant women, Patients with coagulation defects, Patients with critical illness and medically unfit for surgery. Gathered data were processed using the SPSS version 16 (SPSS Inc., Chicago, IL, USA). A Student t test was used to test the significance of difference for quantitative variables, while Chi Square and Fisher's exact tests were used to test the significance of difference for qualitative variables. A probability value ( $P$ -value) $<0.05$  was considered statistically significant.

### Results and Discussion

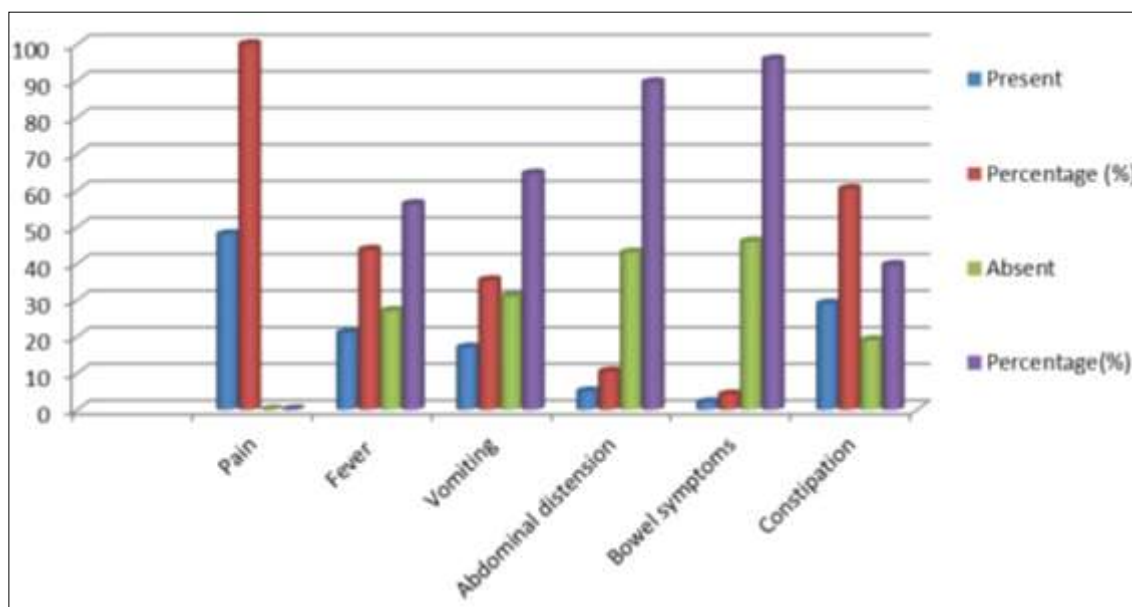
However the total number of cases of chronic abdominal pain in this study were 48 in which the diagnosis remained uncertain despite requisite investigations. Out of 48 patients, 30 (62.5%) were male and 18 (37.5%) were female. The most common site of pain was the periumbilical region (52.08%) followed by the right lower abdominal quadrant (31.25%). Twenty five patients were using either non-steroidal drugs or pain killers to relieve the pain, and five patients were using proton pump inhibitors. Fifteen patients (31.25%) had undergone at least one previous surgical abdominal procedure. All patient characteristics are summarised in [Table 3]. The average length of the operative time was 54.09 minutes with the range from 32 to 116 minutes. There were no cases converted to open procedures. Out the 48 patients with chronic abdominal pain, a definitive diagnosis was established in 46 patients (95.83%), while no identifiable cause could be reached in two patients (4.16%). The most common laparoscopic findings were adhesions (79.16%). Other findings included appendiceal pathology (10.41%), hernia (2.08%), gall bladder pathology (2.08%), and mesenteric lymphadenopathy (2.08%). [Table 2] summarises the laparoscopic diagnoses assigned to all patients.

**Table 1:** Comparison of age and sex among patients with chronic abdominal pain

Age in years	Male (30)	Female (18)
<15	02	01
15-25	12	05
25-35	06	08
35-45	05	03
45-55	03	01
55-65	02	0
>65	0	0

**Table 2:** Illustration of various symptoms of chronic abdomen pain

Symptom	Present	Percentage (%)	Absent	Percentage (%)
Pain	48	100	0	0
Fever	21	43.75	27	56.25
Vomiting	17	35.41	31	64.58
Abdominal distension	5	10.41	43	89.58
Bowel symptoms	2	4.16	46	95.83
Constipation	29	60.41	19	39.58



**Fig 1:** Major symptoms in chronic abdominal pain

**Table 3:** Characteristics of the studied patients

Site of pain	No. of patient (%)
Right lower quadrant	15 (31.25)
Right upper quadrant	05 (10.41)
Left lower quadrant	02 (4.16)
Left upper quadrant	01 (2.08)
Periumbilical	25 (52.08)
History of previous abdominal surgery	07 (15.5)

**Table 4:** Laparoscopic findings, intraoperative data and postoperative characteristics

Findings	Values
Duration of operation (Minutes)	54.09 ± 16.2
Mean ± SD (Range)	32 – 116
Laparoscopic findings	
Adhesions	38 (79.16%)
Hernia	1 (2.08%)
Abnormal appendix	5 (10.41%)
Abnormal gall bladder	1 (2.08%)
Enlarged lymph node	1 (2.08%)
Normal	2 (4.16%)
Postoperative Complications	
None	41 (85.41%)
Bleeding	3 (6.25%)
Infection	7 (14.58%)
Postoperative Hospital Stay (Days Range)	2-12

**Table 5:** Postoperative pain relief

Duration	Positive outcome (Approx.)	Negative outcome (Approx.)
After 2 months	95.5%	4.5%

Chronic abdominal conditions have been a challenge. Prior to the era of diagnostic laparoscopy, these patients used to undergo a battery of expensive investigations, while remaining dissatisfied. The search for pathology in these patients usually entailed a series of laboratory and invasive tests. As it is indicated in figure 1 and table 2 that various symptoms occur while abdominal pain, fever, vomiting, constipation, bowel distension etc. Similarly table 4 Laparoscopic management included adhesiolysis [38], appendectomy [5], hernia repair [1],

cholecystectomy [1], and lymph node biopsy [1]. Two patients had no interventions performed. Postoperative hospital stay ranged from two to twelve days with a mean of 3.8 days.

In most cases no postoperative complications had been reported except in eight cases (three cases showed bleeding and five cases showed infection). The bleeding could be dealt with through electrocautery and postoperative transfusion of packed cells with no necessity for laparotomy, while the wound infection responded well to oral antibiotic and daily dressing. [Table 5] shows that, all patients were re-evaluated for pain. After two months, positive outcome (less pain or disappearance of pain) was achieved in 46 patients (95.83%) while negative outcome (unchanged or worse pain) was noted in 2 patients (4.16%). Chronic idiopathic pain syndromes are among the most Challenging and demanding conditions to treat across the whole age spectrum. Potentially it can be unrewarding for both the patients and the medical team [6]. Studies conducted with large community samples or hospital populations imply chronic abdominal pain is a pervasive problem. Abdominal pain was the third most common pain complaint of individuals enrolled in a large health maintenance organisation [7]. All patients included in the study had chronic abdominal pain, and they were subjected to laparoscopic evaluation after exclusion of all organic causes of the pain by radiographic and laboratory tests. The study confirmed that in this difficult patient group, laparoscopy could safely identify abnormal findings and can improve the outcome in a majority of cases. A majority of patients had undergone previous abdominal surgery, and not surprisingly, in a majority, adhesions were found. However, a significant number were found to have a variety of other conditions to which their pain could be attributed, while a less number were found to have no clear pathology, during laparoscopy. The overall outcome in this series was positive; most of the patients found significant relief from their chronic pain, postoperatively. The use of laparoscopy in patients with ill-defined chronic abdominal pain remains controversial [28]. While we and others have found that most patients with chronic abdominal pain had intra-abdominal adhesions and they responded well to laparoscopic adhesiolysis [9-11, 15], Ikard has questioned whether laparoscopic adhesiolysis was beneficial and has suggested that it may not be safe [12]. He stated that adhesions do not cause pain unless they are obstructing and in

such cases; the laparoscopic approach cannot provide adequate exposure to the abdomen and may be dangerous. Whether laparoscopic adhesiolysis is preferable to laparotomy or not is a matter of debate. Some authors believe that adhesions can be elusive to even the most sophisticated imaging studies<sup>[8]</sup>, while others state that the laparoscopic approach for adhesiolysis is safe<sup>[13, 15]</sup>, feasible, and offers the advantages of decreased length of stay, faster return to full activity, and decreased morbidity. This debate is also evident in the experimental studies, where Luciano *et al*<sup>[14]</sup>, have found laparoscopic adhesiolysis effective and associated it with a lesser extent. El-Labban *et al* say laparoscopy can be proved to be an important tool in the minimally invasive exploration of selected patients with chronic abdominal disorders, whose diagnosis remains uncertain, despite exploring the requisite laboratory and imaging investigations like ultrasonography, CT scan, and the like. Chronic abdominal conditions are associated with poor quality of life<sup>[16]</sup> Magni G *et al* stated the significant levels of depressive symptoms<sup>[17]</sup>. Ester DW *et al* much is known about the prevalence, social burden, and suffering associated with chronic abdominal conditions<sup>[18]</sup>.

### Conclusion

Laparoscopy is able to achieve the final diagnosis and provide tissue diagnosis without any significant complication and less operative time. It can be safely concluded that diagnostic laparoscopy is a safe, quick, and effective adjunct to diagnostic modalities, for establishing a conclusive diagnosis. Chronic abdominal pain of unknown origin represents a significant problem in surgical patients. Due to improvement in instrumentation and greater experience in the laparoscopy, the procedure no longer limited to visualization. This study showed that laparoscopy is an effective approach in the management of patients with chronic abdominal pain in whom conventional methods of investigations have failed to elicit a certain cause. The therapeutic value of laparoscopy is also accepted and appreciated. Nevertheless, patient selection and appropriate operative technique are essential for rewarding outcome.

**Source of support:** None

**Conflict of interest:** None declared.

### References

1. Camilleri M. Management of patients with chronic abdominal pain in clinical practice. *Neurogastroenterol Motil* 2006;18:499-506.
2. Hackenberg TP, Mentula A, Leppaniemi Sallinen V. Laparoscopic versus open surgery for acute adhesive small-bowel obstruction: A propensity score-matched analysis. *Scandinavian J Surg* 2017;106(1):28-33.
3. Udwadia TE. Diagnostic laparoscopy. *Surg Endoscopy* 2004;18:6-10.
4. Swank DJ, Van Erp WF, Repelaer Van Driel OJ, Hop WC, Bonjer HJ, Jeekel H. A Prospective analysis of predictive factors on the results of laparoscopic adhesiolysis in patients with chronic abdominal pain. *Surg Laparosc Endosc Percutan Tech* 2003;13:88-94.
5. Lavonius M, Gullichsen R, Laine S, Ovaska J. Laparoscopy for chronic abdominal pain. *Surg Laparosc Endosc* 1999;9:42-4.
6. American Academy of Pediatrics Subcommittee on Chronic Abdominal Pain. Chronic abdominal pain in children. *Pediatrics* 2005;115:812-5.

7. Von Korff M, Dworkin SF, LeResche L, Kruger A. An epidemiologic comparison of pain complaints. *Pain* 1988;32:173-83.
8. Klingensmith ME, Soybel DI, Brooks DC. Laparoscopy for chronic Abdominal pain. *Surg Endosc* 1996;10:1085-7.
9. Paajanen H, Julkunen K, Waris H. Laparoscopy in chronic abdominal pain. A prospective nonrandomized long-term follow-up study. *J Clin Gastroenterol* 2005;39:110-4.
10. Salky BA, Edey MB. The role of laparoscopy in the diagnosis and treatment of abdominal pain syndromes. *Surg Endosc* 1998;12:911-4.
11. Lavonius M, Gullichsen R, Laine S, Ovaska J. Laparoscopy for chronic abdominal pain. *Surg Laparosc Endosc* 1999;9:42-4.
12. Ikard RW. There is no current indication for laparoscopic adhesiolysis to treat abdominal pain. *South Med J* 1992;85:939-40.
13. Nagle A, Ujiki M, Denham W, Murayama K. Laparoscopic adhesiolysis for small bowel obstruction. *Am J Surg* 2004;187:464-70.
14. Luciano AA, Maier DB, Koch EI, Nulsen JC, Whitman GF. A comparative study of postoperative adhesions following laser surgery by laparoscopy versus laparotomy in the rabbit model. *Obstet Gynecol* 1989;74:220-4.
15. Prushik SG, Stucchi AF, Matteotti R, Aarons CB, Reed KL, Gower AC, *et al*. Open adhesiolysis is more effective in reducing adhesion reformation than laparoscopic adhesiolysis in an experimental model. *Br J Surg*.
16. El-Labban GM, Hokkam EN. The efficacy of laparoscopy in the diagnosis and management of chronic abdominal pain. *J Minim Access Surg* 2010;6:95-9.
17. Ferrell BR. The impact of pain on quality of life. A decade of research. *Nurs Clin North Am* 1995;30:609-24.
18. Magni G, Rossi MR, Rigatti-Luchini S, Merskey H. Chronic abdominal pain and depression. Epidemiologic findings in the United States. Hispanic health and nutrition examination survey. *Pain* 1992;49:77-85.
19. Easter DW, Cuschieri A, Nathanson LK, Lavelle-Jones M. The utility of diagnostic laparoscopy for abdominal disorders. Audit of 120 patients. *Arch Surg* 1992;127:379-83.