



E-ISSN: 2616-3470  
P-ISSN: 2616-3462  
© Surgery Science  
[www.surgeryscience.com](http://www.surgeryscience.com)  
2021; 5(1): 158-160  
Received: 21-11-2020  
Accepted: 23-12-2020

**Dr. Sushrut Fulare**  
Department of Surgery, NKP  
Salve Institute of Medical Sciences  
and Research Center, Nagpur,  
Maharashtra, India

**Dr. Satish Deshmukh**  
Department of Surgery, NKP  
Salve Institute of Medical Sciences  
and Research Center, Nagpur,  
Maharashtra, India

**Dr. Pratik Chavan**  
Department of Surgery, NKP  
Salve Institute of Medical Sciences  
and Research Center, Nagpur,  
Maharashtra, India

**Dr. Jyoti Gupta**  
Department of Surgery, NKP  
Salve Institute of Medical Sciences  
and Research Center, Nagpur,  
Maharashtra, India

**Corresponding Author:**  
**Dr. Satish Deshmukh**  
Department of Surgery, NKP  
Salve Institute of Medical Sciences  
and Research Center, Nagpur,  
Maharashtra, India

## International Journal of Surgery Science

### Mucinous cystadenoma of appendix: A rare presentation

**Dr. Sushrut Fulare, Dr. Satish Deshmukh, Dr. Pratik Chavan and Dr. Jyoti Gupta**

**DOI:** <https://doi.org/10.33545/surgery.2021.v5.i1c.607>

#### Abstract

Mucinous cystadenoma of the appendix is a rare disease associated with cystic dilatation, to which a more general term, mucocele is applied. Clinically, appendiceal mucocele (AM) is an incidental finding or it may mimic appendicitis. In AM, distension of the appendix is caused by mucus, the source of which can be benign or malignant. For the benign disease, appendectomy alone is sufficient but for malignant conditions adjunct treatments are needed. Proper pre-operative evaluation is imperative to distinguish between benign and malignant causes in order to guide the management and reduce complications. For the definitive diagnosis, histology and immunohistochemistry are required. We report an finding of an appendiceal mucocele.

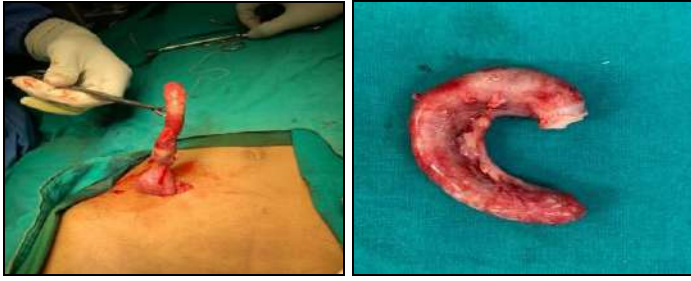
**Keywords:** Mucinous cystadenoma clinically, appendiceal mucocele

#### Introduction

Mucocele of the appendix is dilatation of appendix due to obstructive pathology caused by intra luminal mucoid material accumulation. (First described) Clinically, appendiceal mucocele (AM) is an incidental finding or it may mimic acute appendicitis (AA). (Incidence) Preoperative investigations help distinguish between AA and AM to decide the best surgical approach to prevent peritoneal spillage regardless of the etiology.

#### Case report

40 years old female presented to the out-patient-department of surgery for evaluation of pain in right lower abdomen since 3 days. The pain was sudden in onset, non-radiating and colicky in nature. The pain was associated with multiple episodes of vomiting, decreased appetite and generalized weakness. The patient did not give any history of fever or altered bowel and bladder habits. Rest of the history, including menstrual history was unremarkable to our case. On examination, the patient was afebrile, hemodynamically stable with a BMI of 22.7. On per-abdominal examination mild tenderness was noted in right iliac fossa. Laboratory investigations showed leukocytosis with neutrophilia. Abdominal ultrasonography revealed an inflamed and edematous appendix, suggestive of acute appendicitis. A contrast-enhanced CT examination of the abdomen showed grossly distended appendix with hypodense fluid within it and appendicolith noted at its base suggestive of mucocele of appendix. Based on the clinical examination and radiological reports, the decision of open appendectomy was taken. A cystic mass of appendix with inflamed walls was found. As no visible lymph nodes were found and there was no pathological changes in the base of appendix, only appendectomy was performed. There were no intra-operative complications and the specimen was sent for histopathological examination. Histopathological features were suggestive of mucinous cystadenoma of appendix. Post-operative recovery was uneventful. In a follow up period of one year, the patient did not have any fresh complaints.



## Discussion

Rokitansky was the first to describe mucocele of appendix in 1942. He described it as cystic dilatation of the appendix caused by obstruction in the lumen, resulting in accumulation of mucus. This obstruction of appendicular lumen is secondary to inflammatory or neoplastic pathology. Mucocele of appendix is more common in elderly patients in the fifth or sixth decade and have higher prevalence among women. The incidence of mucocele of appendix is 0.2 % to 0.4% in the entire appendectomy specimen. According to the histological characteristic of lumen obstruction, mucocele of appendix can be classified into:

- i) **Simple mucocele (1%):** Degenerative epithelial changes with no evidence of hyperplasia or mucosal atypia.
- ii) **Hyperplastic mucocele (25%):** Hyperplastic growth of appendicular or caecal mucosa.
- iii) **Mucinous cystadenoma (63%):** Dysplastic changes in the epithelium similar to colon adenomatous polyps.
- iv) **Mucinous cystadenocarcinoma (11%):** High grade cellular dysplastic changes and stromal invasion.

In the latter two variants described, the mucous material contains epithelial adenomatous cells with low to high grade of dysplasia. In these cases, rupture or perforation of the appendix may lead to dissemination of mucous material with dysplastic cells in the abdominal cavity resulting in mucinous ascites or Pseudomyxoma peritonei.

The clinical picture of this disease is non-specific, often asymptomatic (around 25% of the cases). In more than half of the cases, the disease is discovered during radiological examination or after histopathological examination of the excised specimen of appendix, as in our case.

Pre-operative diagnosis of this condition is difficult but of prime importance as it leads to informed selection of surgical management- to avoid complications like peritoneal dissemination and repeated surgery. Ultrasonography is regarded as the first line of investigation method as it can help differentiate between mucocele of appendix and acute appendicitis or other conditions related to the presenting symptoms. USG has a sensitivity of 83% and specificity of 92%. CT scan has higher accuracy and can identify any calcification, cystic dilatation and thickness of wall of appendix and lumen diameter. In our case, USG did not provide an accurate diagnosis, but considering the age of the patient and presenting complaints, CT scan was done yielding the diagnosis of mucocele of appendix.

Although mucocele of appendix in itself is not a life-threatening condition but it may lead to complications like perforation of appendix causing peritoneal dissemination of the content and often causing pseudomyxoma peritonei, a life threatening condition with poor surgical outcomes. Therefore, selection of an adequate surgical method after diagnosis is important. Some surgeons think that open surgery should be favored against laparoscopy. If the surgery was launched using a laparoscopic

method and it appears that there is an appendiceal mucocele, it must be converted into open surgery.

## This has 2 objectives

- 1) To perform surgery carefully so the cyst is not ruptured and the filling is not scattered into the peritoneal cavity.
- 2) With an open surgery compared to the laparoscopic method.

It is possible to have a fuller inspection, palpation and direct inspection of the spots in the abdomen where mucinous tumors are most common. Some surgeons consider that the operation can be performed using a laparoscopic method by adhering to safety rules, especially when removing the mucocele from the abdomen and an endobag must be used.

An algorithm for the selection of the type of surgery has been furnished by Dhage-Ivatury and Sugarbaker.

## It envisages several factors

- 1) Whether or not a mucocele is perforated
- 2) Whether the base of the appendix (margins of resection) is involved in the process
- 3) Whether there are positive lymph nodes of mesoappendix and ileocolic.

As a result patients may require different operations: appendectomy to the right colectomy, including cytoreductive surgery, heated intraoperative intraperitoneal chemotherapy, early postoperative intraperitoneal chemotherapy. In our patient the mucocele was not perforated, there was no pathologic process in the base of the appendix (negative margins of resection), and the regional lymph nodes were negative. Therefore, only appendectomy was performed, which is an adequate surgery in such a case. Also, according to the algorithm, no long-term follow-up is advised for our patient.

## Conclusion

In conclusion, appendiceal mucocele is a rare disease and has a clinical picture that resembles acute appendicitis, and often presents with vague, non-specific symptoms. A correct diagnosis before surgery is very important for the selection of surgical technique to avoid severe intraoperative and postoperative complications. USG, particularly CT, should be used extensively for this purpose.

## References

1. Vriens BH, Klaase JM. Giant mucinous cystadenoma of the appendix. *Am J Surg* 2007;194(3):392-393.
2. Karakaya K, Barut F, Emre AU, Ucan HB, Cakmak GK, Irkorucu O *et al.* Appendiceal mucocele: case reports and review of current literature. *World J Gastroenterol* 2008;14(14):2280-2283.
3. Ashrafi M, Joshi V, Zammit M, Telford K. Intussusception of the appendix secondary to mucinous cystadenoma: a rare cause of abdominal pain. *Int. J Surg. Case Rep.* 2011;2(2):26-27.
4. Francica G, Lapicciarella G, Giardibello C, Scarano F, Angelone G, De Marino F *et al.* Giant mucocele of the appendix: clinical and imaging finding in 3 cases. *J Ultrasound Med* 2006;25(5):643-648.
5. Birnbaum BA, Wilson SR. Appendicitis at the millennium. *Radiology* 2000;215(2):337-348.
6. Sasaki K, Ishida H, Komatsuda T, Suzuki T, Konno K, Ohtaka M *et al.* Appendiceal mucocele: sonographic findings. *Abdom Imaging* 2003;28(1):15-18.

7. Benett GL, Tanpitukponqse TP, Macari M, Cho KC, Babb JS. CT diagnosis of mucocele of the appendix in patients with acute appendicitis. *AJR Am J Roentgenol* 2009;192(3):103-110.
8. Zanati SA, Martin JA, Baker JP, Streutker CJ, Marcon NE. Colonoscopic diagnosis of mucocele of the appendix. *Gastrointest Endosc* 2005;62(3):452-456.
9. Kim-Fuchs C, Kuruvilla YC, Angst E, Weimann R, Gloor B, Candinas D. Appendiceal mucocele in an elderly patient: how much surgery? Case report.
10. Misdraji J, Yantiss RK, Grame-Cook FM, Balis UJ, Young RH. Appendiceal mucinous neoplasms. A clinicopathologic analysis of 107 cases. *Am J Surg. Pathol* 2003;27(8):1089-1103.
11. Khan MR, Ahmed R, Saleem T. Intricacies in the surgical management of appendiceal mucinous cystadenoma: a case report and review of literature. *J Med Case Reports* 2010;5(4):129.
12. Chiu CC, Wei PL, Huang MT, Wang W, Chen TC, Lee WJ. Laparoscopic resection of appendiceal mucinous cystadenoma. *J Laparoendosc. Adv. Surg. Tech A*. 2005;15(3):325-328.
13. Liberale G, Lemaitre P, Noterman D, Moerman C, De Neubourg E, Sirtaine N *et al.* How should we treat mucinous appendiceal neoplasm? By laparoscopy or laparotomy? A case report. *Acta Chir. Belg* 2010;110(2):203-207.
14. Rokitsansky CF. *A Manual of Pathological Anatomy*. Philadelphia: Blanchard & Lea 1855, 2.