



International Journal of Surgery Science

E-ISSN: 2616-3470
P-ISSN: 2616-3462
© Surgery Science
www.surgeryscience.com
2019; 3(1): 92-94
Received: 20-11-2018
Accepted: 25-12-2018

Dr. Ravi Gupta
Senior Resident,
Department of Surgical
Gastroenterology Dr. RMLIMS
Lucknow, Uttar Pradesh, India

Dr. Shakeel Masood
Additional Professor,
Department of Surgical
Gastroenterology Dr. RMLIMS
Lucknow, Uttar Pradesh, India

Dr. Utkarsh Srivastava
Senior Resident,
Department of Surgical
Gastroenterology Dr. RMLIMS
Lucknow, Uttar Pradesh, India

Case report: Left sided gall bladder associated with chylolymphatic cyst of mesentery of small intestine

Dr. Ravi Gupta, Dr. Shakeel Masood and Dr. Utkarsh Srivastava

DOI: <https://doi.org/10.33545/surgery.2019.v3.i1b.20>

Abstract

Mesenteric cyst and left sided gall bladder both are rare entity. Incidence of mesenteric cyst is 1 per 1,00,000 to 2,50,000, a rare abdominal tumor, among which chylolymphatic mesenteric cyst is further rare. In left sided gall bladder, gall bladder is attached on left lateral sector of liver, left to falciform ligament and interlobar fissure. Left sided gall bladder can be a single anomaly or associated with other anomalies like duplicated gall bladder, hypoplastic bile duct, situs inversus, anomalous pancreatico-biliary ductal junction, absence of quadrate lobe, accessory liver. In our case it was associated with mesenteric cyst which is the first case to be reported to best of our knowledge.

Keywords: Left sided gall bladder, chylolymphatic mesenteric cyst, small intestine

Introduction

Mesenteric cyst and left sided gall bladder, individually both represents a rare entity [1, 2]. In left sided gall bladder, gall bladder is attached on left lateral sector of liver, left to falciform ligament and interlobar fissure [1]. As a rare disease, clinical presentation of mesenteric cyst is not characteristic [2]. Most of them even not have diagnostic features on imaging. Final diagnosis is made by surgical exploration. As both diseases are rare among themselves, so this is the first case to be reported with both finding in same patient.

Case report

A boy of age 16 years presented to us with history of recurrent pain in periumbilical region for 2 years. Pain was colicky, for 1 to 2 hours every 10 to 15 days interval, associated with bilious vomiting with no visible peristalsis. There was history of heaviness in upper abdomen and early satiety. X-rays abdomen showed no air fluid levels. Contrast enhanced CT scan was done which was suggestive of cystic lesion displacing the bowel loops (fig 1), but its origin was doubtful. Patient planned for surgery. Intraoperatively 3 feet distal to duodenojejunal junction, mesenteric cyst was confirmed. Cyst was resected with adjacent bowel loops with side to side hand sewn anastomosis of bowel (fig 4.1 & 4.2). After this procedure we noticed that gall bladder was present on left side of falciform ligament attached to left lateral sector of liver (fig 3), so we were unable to take both the anomaly photo in one frame with proper liver retraction. But luckily one picture showing both anomaly in same frame which was taken for cyst only (fig 2). Post op period was uneventful, patient orally allowed from POD 4 and discharge on day 7. Histopathology report was suggestive of chylolymphatic mesenteric cyst.

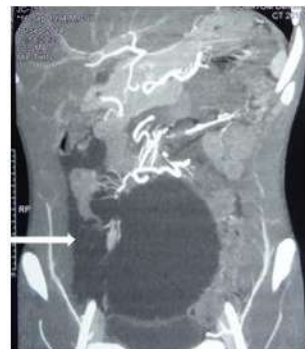

Fig 1: Image showing cystic lesion displacing the bowel loops. (Arrow marked).

Correspondence
Dr. Ravi Gupta
Senior Resident,
Department of Surgical
Gastroenterology Dr. RMLIMS
Lucknow, Uttar Pradesh, India

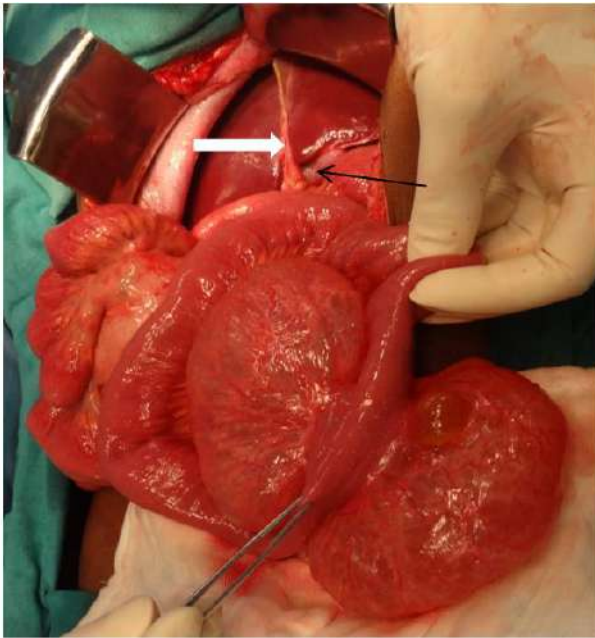


Fig 2: Intraop finding showing mesenteric cyst with left sided gall bladder. Falciform ligament (white arrow), left sided gall bladder (black arrow).

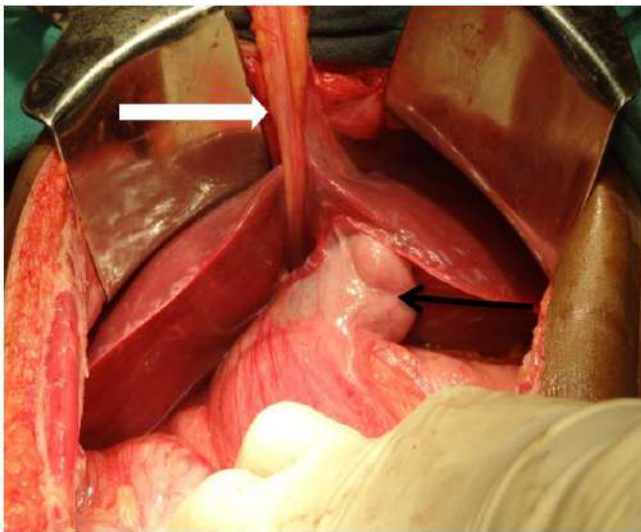


Fig 3: Intraop finding showing falciform ligament (white arrow), left sided gall bladder (black arrow).

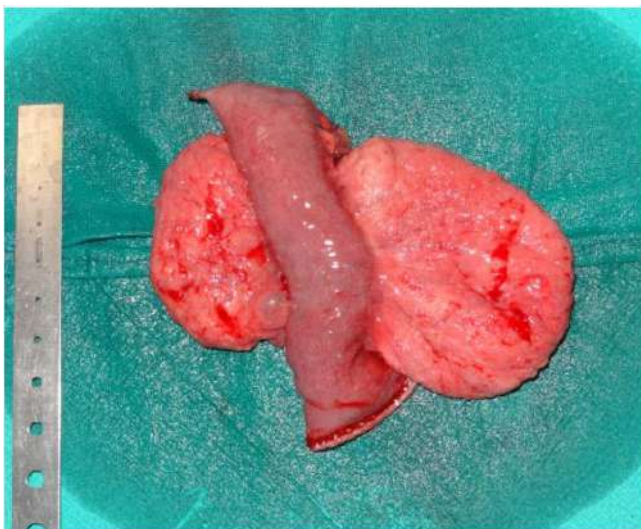


Fig 4: Resected small bowel specimen with mesenteric cyst,

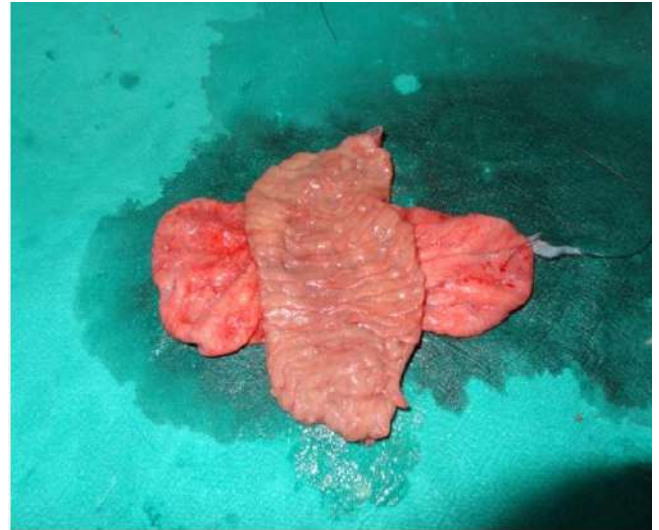


Fig 5: Open specimen to rule out enteric communication of cyst.

Discussion

Mesenteric cyst and left sided gall bladder both are rare entity. Incidence of mesenteric cyst is 1 per 1,00,000 to 2,50,000, a rare abdominal tumor, among which chylolymphatic mesenteric cyst is further rare [3]. Pathogenesis of these cyst is due to sequestration of lymphatic duct or due to ectopic lymphatic channel which lead to imbalance between inflow and outflow of lymph and chyle from mesentery, resulting which lymph or chyle get accumulated and cyst gets enlarged and symptomatic [4]. Clinical presentation can be asymptomatic or with abdominal lump, pain, and obstruction [5]. Our patient presented with recurrent abdominal pain with bilious vomiting. Characteristic feature in ultrasound or CT scan is fluid fluid level which is due to lighter chyle above and lymph below [6]. In our case no such feature where present on CT scan, so preoperatively definitive diagnosis of chylolymphatic mesenteric cyst cannot be made. Surgically these cyst are managed by enucleation or resection with adjacent bowel. When there is risk to blood supply to adjacent bowel segment than resection with bowel segment is preferred procedure [7]. Marsupialization and drainage has also been described but with high recurrence rate [7]. In our case resection of bowel segment with cyst was done. Our case was also having left sided gall bladder which itself is a rare finding. Left sided gall bladder can be a single anomaly or associated with other anomalies like duplicated gall bladder [8], hypoplastic bile duct [9], situs inversus [10], anomalous pancreatico-biliary ductal junction [11], absence of quadrate lobe [10], accessory liver [12]. In our case it was associated with mesenteric cyst.

Conclusion

To the best of our knowledge this is the first reported case having left sided gall bladder with chylolymphatic mesenteric cyst.

References

1. Idu M, Jakimovicz I, Iuppa A, Cuscheri A. Hepatobiliary anatomy in patients with transposition of the gallbladder. Implications for safe laparoscopic cholecystectomy. *Br J Surg.* 1997; 83:1442-3.
2. Moynihan BG. Mesenteric Cysts. *Ann Surg.* 1897; 26:1-30.
3. Liew SC, Glenn DC, Storey DW. Mesenteric cyst. *Aust N Z J Surg.* 1994; 64:741-4.
4. Engel S, Clagett OT, Harrison Eg Jr. Chylous cysts of the abdomen. *Surgery.* 1961; 50:593-9.

5. Rattan KN, Nair VJ, Pathak M, Kumar S. Pediatric chylolymphatic mesenteric cyst - a separate entity from cystic lymphangioma: a case series. *J Med Case Reports*. 2009; 3:111.
6. Fujita N, Noda Y, Kobayashi G, Kimura K, Watanabe H, Masu K *et al*. Chylous cyst of the mesentery: US and CT diagnosis. *Abdom Imaging*. 1995; 20:259-61.
7. Kurtz RJ, Heimann TM, Holt J, Beck AR. Mesenteric and retroperitoneal cysts. *Ann Surg*. 1986; 203:109-2.
8. Schachner A. Anomalies of the gall-bladder and bile-passages. *Ann Surg*. 1916; 64:419-33.
9. Hay SA, Soliman HE, Sherif HM, Abdelrahman AH, Kabesh AA, Hamza AF. Neonatal jaundice: the role of laparoscopy. *J Pediatr Surg*. 2000; 35:1706-9.
10. Southam JA. Left sided gallbladder. Calculus cholecystitis with situs inversus. *Ann Surg*. 1975; 182:135-7.
11. Ogawa T, Ohwada S, Ikeya T, Shiozaki H, Aiba S, Morishita Y. Left-sided gallbladder with anomalies of the intrahepatic portal vein and anomalous junction of the pancreaticobiliary ductal system: a case report. *Hepatogastroenterology*. 1995; 42:645-9.
12. Herrington JL. Gallbladder arising from the left hepatic lobe. *Am J Surg*. 1966; 106:112-13.
13. Icoma A, Towaka K, Hamada N *et al*. Left sided gallbladder with accessory liver accompanied by intrahepatic cholangiocarcinoma]. *Nippon Geka Gakkai Zasshi*. 1992; 93:434-6.