



E-ISSN: 2616-3470

P-ISSN: 2616-3462

© Surgery Science

www.surgeryscience.com

2021; 5(2): 84-87

Received: 13-02-2021

Accepted: 17-03-2021

Dr. GM Naikoo

Consultant General Surgery,
GMC, Srinagar, India

Dr. Muddasar Rather

Consultant Surgical,
Ge GMC, Srinagar, India

Dr. Ishfaq Ahmad Gilkar

Senior Resident,
GMC, Srinagar, India

Clipping Vs Suture ligation of cystic duct and artery in laparoscopic cholecystectomy: A tertiary care based observational study

Dr. GM Naikoo, Dr. Muddasar Rather and Dr. Ishfaq Ahmad Gilkar

DOI: <https://doi.org/10.33545/surgery.2021.v5.i2b.666>

Abstract

Introduction: Surgical removal of gall bladder is called cholecystectomy. The most commonly operation done in the case of symptomatic gall stone diseases and other gall bladder related pathologies. Cholecystectomy can be performed using two techniques either 'open cholecystectomy' and laparoscopic Cholecystectomy.

Methods and material: This was a tertiary hospital based observational study carried in the department of general surgery government medical college srinagar kashmir, over a period of three years from august 2017 to august 2020 including 100 patients who underwent elective laparoscopic cholecystectomy for symptomatic gall bladder stones. In this study we divided patients into two categories where group a which includes first 50 patients who underwent ligation of cystic artery and duct by titanium clipping and group b included those with separate suture ligation of cystic duct and artery.

Results: most of these patients were belonging to age group of 19-28 and 29-38 with mean age of 31.3. pre-operative usg was showing mostly stones. the body mass index was mostly between 18.5-24.5. mean operative time in clipping group 41.2 and in suture ligation group was 46.8 and in according to bmi, higher bmi took less operative time in suture ligation 38.1 min than clipping 41.7. One patient (clipping) was having post operative bile leak which was managed by ercp and one patient among 50 developed clip migration.

Conclusion- From this study we concluded that suture ligation of cystic duct and artery by either silk or vicryl 2/0 is safe, effective and low cost alternative to clips especially in developing countries.

Keywords: cholecystectomy, laparoscopic, bile leak

Introduction

Surgical removal of gall bladder is called cholecystectomy. The most commonly operation done in the case of symptomatic gall stone diseases and other gall bladder related pathologies [1]. Cholecystectomy can be performed using two techniques either 'open cholecystectomy' and 'laparoscopic

Cholecystectomy' [2]. In laparoscopic cholecystectomy cystic duct and artery are usually secured by titanium clips and there are other methods for securing cystic duct and artery like intracorporeal ligation by absorbable material or harmonic scalpel [3]. Suture ligation of cd appeared to be more cost effective. On the other hand, the application of clips shown to have some drawbacks such as dislodgement and bile leak. There are reported cases after long term follow up shown clip migration which resulted in biliary stone formation or bile duct stenosis [4]. Intra-corporeal ligation takes more time than applying a clip, and it needs well training, and in some series they found that ligation of cystic duct and artery separately does not increase operative time if the surgeon has experience for intra-corporeal knotting. Although clipping and the use of harmonic scalpel are an efficient and practical method for securing cystic duct and artery in laparoscopic cholecystectomy, they have a challenge in cases with wide cystic duct (more than 5 mm) [5]. The aim of this study is to compare the two different methods; tie versus clipping, for securing cystic duct and artery in laparoscopic cholecystectomy, in terms of efficacy and safety, and also the difference in the times of operations in both methods.

Methods and material

This was a tertiary hospital based observational study carried in the department of general

Corresponding Author:

Dr. Ishfaq Ahmad Gilkar

Senior Resident,
GMC, Srinagar, India

surgery government medical college srinagar kashmir, over a period of three years from august 2017 to august 2020 including 100 patients who underwent elective laparoscopic cholecystectomy for symptomatic gall bladder stones. In this study we divided patients into two categories where group a which includes first 50 patients who underwent ligation of cystic artery and duct by titanium clipping and group b included those with separate suture ligation of cystic duct and artery. The study included patients with symptomatic gall stones who underwent laparoscopic cholecystectomy; performed by a single team were using different methods. Consents were obtained from all participants included in the study for both methods. Demographic data, body mass index (bmi), previous cholecystitis, pancreatitis, endoscopic retrograde cholangiopancreatography (ercp) and previous abdominal surgery, all recorded before the operation. Postoperatively the patients followed up in the outpatient clinic at the end of the first and second postoperative weeks for any complication. The standard technique of laparoscopic cholecystectomy was carried out with four ports and using a 30-degree laparoscope. The times of the operations estimated from the first skin incision until the closing of the skin wounds. All patients were thoroughly clinically examined and subjected to all baseline investigations (complete hemogram, kidney function, liver functions tests etc) Radiological investigations like xray chest, usg abdomen and pelvis. The data after collection were entered into an excel sheet then after data clearness transferred to statistical package for social sciences (spss) program version 21 for analysis. P-value equal to or less than 0.05 was regarded as statistically significant.

Inclusion criteria

All cases of laparoscopic cholecystectomy for symptomatic gall stone disease.

Exclusion criteria

- Difficult cases of mirrizi syndrome.
- Dense adhesions, and frozen calot.
- Cases converted to open.
- Any general contraindication for laparoscopy like uncorrected
- Coagulopathy. -concomitant common bile duct stone

Aims and objective

- To study the outcome of cystic duct and artery ligation in laparoscopic cholecystectomy by two methods (clipping vs suture).

Results

Age distribution

Group a.

This group of 50 patients includes who were subjected to ligation via clipping, most of these patients were belonging to age group of 19-28 and 29-38 with mean age of 31.3

Table 1a: showing age distribution in group a

Age group	Number of patients
20-29	12
30-39	19
40-49	9
50-59	10

Table 1b: showing age distribution in group b

Age group	Number of patients
20-29	9
30-39	17
40-49	13
50-59	11

Sex distribution

Group a- in this group of 50 patients most of the patients were males with male female ratio of 1:1.3

Table 2a: showing sex distribution

Sex distributon	Number of patients
Males	28
Females	22

Group b

In this group the males were are the most frequent with male female ratio of 1:1.6

Table 2b: showing sex distribution

Sex distributon	Number of patients
Males	31
Females	19

Ultra Sonography findings

In our study those patients the pre-operative usg was showing mostly stones and other radiological pathologies as shown in table.

Table 3a: showing usg findings in group a

Usg findings	Number of patients
Single stone	26
Multiple stones	18
adenomyomatosis	4
others	2

Table 3b showing usg findings in group b

Usg findings	Number of patients
Single stone	27
Multiple stones	12
adenomyomatosis	8
others	3

Body mass index

In both the groups the bmi was mostly between 18.5-24.5 as shown in table.

Table 4: showing bmi in both groups

Body mass index	Number of patients (group a)	Number of patients (group b)
< 18.5	3	2
18.5-24.9	24	27
25-29.9	12	9
30-34.9	6	7
35-39.9	4	3
≥40	1	2

Time of operation (mean)

Operation time was calculated in both the groups from skin incision to skin closure. Mean operative time was calculated in both the groups and statistically insignificant results were encountered, as shown in table.

Table 5a: showing mean operative time

Method	No. of patients	Mean operative time (min)	P-value
Group a (clipping)	50	41.2	0.7
Group b (suture)	50	46.8	

Table 5b: showing mean operative time in relation with bmi

Method	Body mass index	Mean operative time (min)	P-value
Group a (clipping)	>30	38.1	0.09
Group b (suture)	>30	41.7	

Post-operative complication

Intracorporeal suturing of both cystic duct and artery requires more expertise than clipping but upon analysing the data the chances of bile leak in suturing as compared to clipping is less as shown in figure.

Table 6: Showing post-operative complication

Complication	Group a (clipping)	Group b (suturing)
Bile leak	1	0
Clip migration	1	0
Post-op fever	0	0

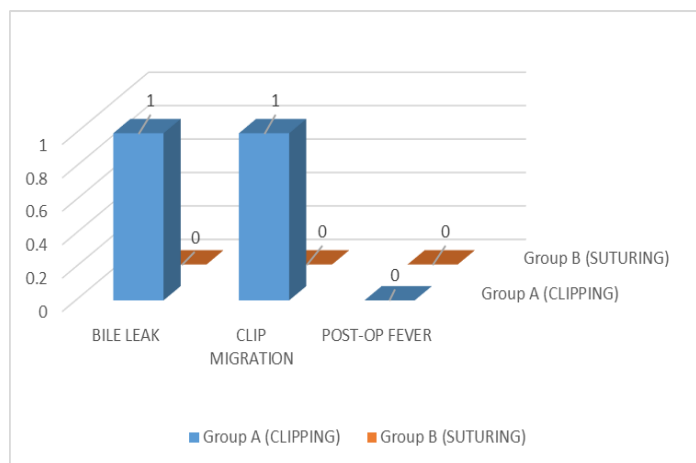


Fig 1: showing post-operative complication.

Discussion

Laparoscopic cholecystectomy is the gold standard technique for treatment of symptomatic gall stones. Simple metallic clips are used by most surgeons to secure the cystic duct and artery since Muhe reported the first laparoscopic cholecystectomy in 1985. Although this standard technique is easy and can be done by most of surgeons but it has some pitfalls. Postoperative cystic duct leak is a potentially serious complication causing bilioma or biliary peritonitis [6]. Clipping of the duct and artery is a safe and efficient method, but it has some challenges like cystic duct diameter, so intracorporeal ligation is solution and should be the gold standard in laparoscopic cholecystectomy especially after good training and also, as we came up with it, it is a safe and easily learned [7]. In this study the mean age of the patients were 31 with males predominance as compared to women, similar observations were made by shabbar hussain changazi *et al* [8] where he found in his study that out of the 95 participants of the study 89(93.7%) were females and 6(6.3%) were males. The most common age group was 36-45 years contributing to 34(35.8%) patients with 26-35(26%) being the second most common. In our study those patients the pre-operative usg was

showing mostly stones for which operation was done. In both the groups the bmi was mostly between 18.5-24.5 there was no significant difference between the times of the operations regarding bmi, and also between the times of the operations in both groups which is similar to study carried by ismaeil, da [9]. Operation time was calculated in both the groups from skin incision to skin closure. Mean operative time was calculated in both the groups and statistically insignificant results were encountered, in our study mean operative time in clipping group 41.2 and in suture ligation group was 46.8 and in according to bmi, higher bmi took less operative time in suture ligation 38.1 min than clipping 41.7 similar observations were made by ismaeil, da [9]. as found that there were no significant differences in the operation times between the two groups (p-value: 0.08), another study performed the technique for closure of the cystic duct in 1000 consecutive

Patients subjected to lc as intracorporeal knotting. Neither bile leakage nor any other procedure-related complication was seen. The mean time taken for cystic duct ligation was 3.5 minutes. The method of total intracorporeal cystic duct and artery ligation in lc is simple, technically easy, secure, and economical [10]. Another study revealed that intracorporeal knotting and endoloop closure were safe, successful and feasible methods for appendectomy. The authors observed that silk was a better alternative option to ligate the base of the appendix as compared to harmonic-like device. Hence, in rural locations, or in settings where instruments are not affordable to the surgeon, or in financially compromised patients, silk can be Used without any complication [11]. Regarding post-operative complications one patient (clipping) was having post operative bile leak which was managed by ercp and one patient among 50 developed clip migration. There was no post-operative complication in suture ligation group. Similar observations were made by cettal *et al* [12] reported that clip migration occurred in 18 of 71 patients over the course of one year. Clips migrated from initial site to either the peritoneal cavity or the common bile duct serving as a potential nidus for common bile duct stones. Farooq u [13] in his study observed bile leakage in two (0.82%) patients postoperatively. In one case, it was found that the clip had slipped from the cystic duct.

Conclusion

From this study we concluded that suture ligation of cystic duct and artery by either silk or vicryl 2/0 is safe, effective and low cost alternative to clips especially in developing countries and non-functioning of clip applicator. The laparoscopic surgeon should be well versed with both techniques.

References

1. Abraham S, Rivero HG, Erlikh IV, Griffith LF, Kondamudi VK. "Surgical and nonsurgical management of gallstones". American Family Physician 2014;89(10):795-802.
2. Mulholland MW, Lillemoe KD, Doherty GM, Upchurch GR, Alam HB, Pawlik TM. Greenfield's surgery: scientific principles & practice (Sixth ed.). Philadelphia. ISBN 978-1-4698-9001-2.
3. Saha PK, Roy RR, Rahman M, Khan EH, Reza SM, Rabbani MG, Alom KS. Clipless Laparoscopic Cholecystectomy: An initial experience of 50 cases in Bangladesh. J Sci Foun 2015;13(1):11-4.
4. Matsumoto H, Ikeda E, Mitsunaga S, Naitoh M, Furutani S, Nawa S. Choledochal stenosis and lithiasis caused by penetration and migration of surgical metal clips. J Hepato-Biliary-Panc Surg 2000;7(6):603-5.

5. Abou-Sheishaa MS, elhadidi A, Negm A, abdelhalim M, Beshir M, Elbahy A. Comparing the efficacy and safety of methods for securing the cystic duct in laparoscopic cholecystectomy metallic clip versus harmonic scalpel versus suture ligation: (Prospective study). Al-azhar assiut medical journal 2015;13(1):96-101.
6. S Adamsen, OH Hansen, PF Jensen *et al.* "Bile Duct Injury during Laparoscopic Cholecystectomy: A Prospective Nationwide Series," Journal of the American College of Surgeons 1997; 184:571-578.
7. Abou-Sheishaa MS, elhadidi A, Negm A, abdelhalim M, Beshir M, Elbahy A. Comparing the efficacy and safety of methods for securing the cystic duct in laparoscopic cholecystectomy metallic clip versus harmonic scalpel versus suture ligation: (Prospective study). Al-azhar assiut medical journal 2015;13(1):96-101.
8. Shabbar Hussain Changazi *et al* Comparison of Clip Application Vs Suture Ligation of Cystic Duct and Cystic Artery In Open Cholecystectomy: A Randomized Controlled Trial', International Journal of Current Medical And Pharmaceutical Research, 2018;4(8):3572-3574.
9. Ismaeil DA, Shkor FN, Salih AM, Ahmed MM, Said AH, Ali HO, Jalal HK. Tie versus clipping typed of cystic duct and artery ligation in laparoscopic cholecystectomy. Bali Medical Journal 2020;9(2):556-561.
10. Golash V. An experience with 1000 consecutive cystic duct ligation in laparoscopic cholecystectomy. Surg Laparosc Endosc Percutan Tech 2008;18:155-156.
11. Deepak Sharma, Brijesh Sharma, Mahesh Solanki. Laproscopic Cholecystectomy: Cystic Duct Occlusion with Titanium Clip or Ligature. International Journal of Science and Research 2016;11:1909-1912.
12. F Cetta, C Baldi, F Lombardo *et al.* "Migration of Metallic Clips Used during Laparoscopic Cholecystec-tomy and Formation of Gallstones around Them: Surgical Implications from a Prospective Study," Journal of Laparoendoscopic & Advanced Surgical Techniques 1997;7(1):37-46.
13. Farooq U, Rashid T, Naheed A, Barkat N, Iqbal M, Sultana Q. Complications of laparoscopic cholecystectomy: an experience of 247 cases. J Ayub Med Coll Abbottabad 2015;2:407-410.