

E-ISSN: 2616-3470

P-ISSN: 2616-3462

© Surgery Science

[www.surgeryscience.com](http://www.surgeryscience.com)

2021; 5(2): 346-349

Received: 28-02-2021

Accepted: 30-03-2021

**Dr. Suresh**

MS, Assistant Professor,  
Department of General Surgery,  
KIMS, Koppal Karnataka India

**Vinayak N Tukka**

MS, Associate Professor,  
Department of General Surgery,  
KIMS, Koppal Karnataka India

**Abhijit Medikeri**

MS, Assistant Professor,  
Department of General Surgery,  
KIMS, Koppal Karnataka India

## Clinical study of solitary nodule of thyroid and role of FNAC in the management of solitary nodule of thyroid

**Dr. Suresh, Vinayak N Tukka and Abhijit Medikeri**

**DOI:** <https://doi.org/10.33545/surgery.2021.v5.i2f.720>

### Abstract

**Background:** Solitary nodule of thyroid has increased in incidence in the present day as compared to two decades before. Because of possibility of malignancy, some clinicians especially those in surgical subspecialties recommended that all nodules have to be removed.

**Objectives:** Clinical study of solitary nodule of thyroid and role of FNAC in the management of solitary nodule of thyroid.

**Method:** This prospective study includes 70 patients, presenting in KIMS, Koppal who were clinically diagnosed as solitary nodule of thyroid. All patients were admitted and were subjected to thyroid profile, USG and FNAC. All patients were operated appropriately depending on the FNAC report. Histopathological examination of the operated specimen was done for all the patients. Depending on the histo-pathological report appropriate postoperative therapies were administered to all the patients and all the patients were followed up appropriately.

**Result:** The peak incidence of solitary nodule was observed in 3<sup>rd</sup> to 5<sup>th</sup> decade, constituting 60% of the cases studied. Females predominated in number over males in occurrence of solitary nodule in ratio of 1:8.16. 33% of all clinically solitary nodule turned out to be multi-nodular goiter. Incidence of malignancy in solitary thyroid nodule was 10.9%. Male to female ratio in case of malignant nodule was 1:5. Incidence of carcinoma in males presenting as solitary nodule was higher (16.67%) compared to that of females (10.20%). The most common cause of malignancy was papillary carcinoma (67%) followed by follicular carcinoma (33%).

**Conclusion:** USG can be accurately used to detect patients with multinodular goiter who clinically present as solitary nodule of thyroid. Common causes of solitary nodule of thyroid are MNG, follicular adenoma and adenomatous goiter.

**Keywords:** solitary nodule, malignancy, euthyroid, FNAC

### Introduction

The solitary thyroid nodule has aroused interest of thyroidologist since the time of Warren H Cole (1949) and his study concluded that incidence of malignancy is higher when compared with multinodular goitre [1].

Thyroid nodules are very common entities, though varying in incidence in different geographical regions [2]. The prevalence of palpable nodules in general population is 4-7%. Solitary nodules of thyroid are about four times more common in women than in men. Overall incidence of malignancy in solitary thyroid nodule ranges from 10-30% [3].

A single nodule in the thyroid is a definite clinical entity with important pathological significance. It is necessary you consider the status of opposite lobe when considering the 'solitariness' of the nodule. Ignoring palpability of opposite lobe is likely to lead to a higher incidence of solitary nodule turning out to be multi-nodular goiter.

Another factor that influences the ultimate histopathological outcome of solitary nodule of solitary nodule thyroid is whether the definition of solitariness is entirely clinical or proved by investigations like U/S, radio iodine scan etc. in general a solitary nodule is defined as "a palpable single clinically detected nodule in the thyroid gland that is otherwise normal" [4]. Visibility or palpability of opposite thyroid lobe precludes inclusion of such cases in this group.

The usual presentation of a thyroid nodule is an asymptomatic mass that is discovered by either the patient or the clinician. Nodules of at least 0.5cm to 1cm can be usually be detected by palpation, although estimates of nodule size varies from physician to physician. It can be difficult to palpate any nodule in patient with a thick, short neck [5].

**Corresponding Author:**

**Dr. Suresh**

MS, Assistant Professor,  
Department of General Surgery,  
KIMS, Koppal Karnataka India

The hyoid nodule has been subject of vigorous controversy with divergent opinions expressed by those who had wide experience in this field. The optimal management of thyroid nodule continues to be a source of controversy and the operative intervention recommended by most of surgeons is not always considered divine by some physicians advocating either observation or suppression [6].

The importance of discrete swelling lies in the risk of neoplasia compared with other thyroid swellings. Some 15% of isolated swelling prove to be malignant and non- neoplastic, largely consisting of malignancy or follicular adenoma in clinically dominant swelling is approximately half that of truly isolated swelling ,it is substantial and cannot be ignored. [7] Because of possibility of malignancy, some clinicians especially those in surgical subspecialties recommend that all nodules have to be removed. On the other hand endocrinologist recommends FNAC performed as initial step of evaluation in order to avoid unnecessary surgery [8].

So the present study has been planned to Clinical study of solitary nodule of thyroid and role of FNAC in the management of solitary nodule of thyroid

### Methods

The present study on “Clinical study of solitary nodule of thyroid and role of FNAC in the management of solitary nodule of thyroid” has been conducted by utilizing cases admitted and managed in the Department of Surgery at KIMS Koppal over a period of 18months from Jan 2018 to Dec 2020.

Prospective analysis of 55 cases of solitary nodule thyroid in the specified period done. These cases were selected by random sampling method and studied in detail clinically and recorded as per the proforma. Routine investigations and specific investigations including FNAC of the nodule, Thyroid.

profile, IDL, Plain X-ray neck, USG neck were done in all cases. Special investigations like radio-isotope scanning was not performed as the facilities were not available. All the patients were managed by surgery and diagnosis was confirmed by histopathological examination.

The patients were grouped according to different variables like age, sex, size of the nodule, site of the nodule, functional thyroid status, FNAC reports and histo- pathological examination reports, then analyzed and compared with the previous similar studies conducted elsewhere. Finally conclusions were drawn accordingly.

### Treatment

**Pre-operative:** Use of anti-thyroid drugs, beta-blockers, blood transfusions or any other medications were prescribed based on individual status and was noted.

**Operative:** Position of the patient, type of anaesthesia, incision, type of operation planned, per- operative findings and type of operation performed were recorded.

**Post-operative:** Every patient was followed up post-operatively during the course of management in the hospital to note the development of and management of complications.

Follow-up: At the time of discharge, all the patients were advised to attend the surgical OPD regularly for follow up. Any recurrences or complications were noted. Thyroid functional status was assessed, accordingly thyroxine tablets prescribed if necessary.

**Result:** The age of the patients ranges from 18 years to 66 years,

with peaks being in 3<sup>rd</sup> to 5<sup>th</sup> decades. The mean age of presentation is 37.24 years. Cases in 3<sup>rd</sup> to 5<sup>th</sup> decades constitutes 60% of the cases studied.

Solitary nodule of thyroid are much more common in females. Out of 55 cases studied 49 were females and 6 were males, and the ratio comes to M : F = 1 : 8.16 . Also the malignant nodules are common in females. Out of 6 cases of malignancy in the study, 5 were females.

All the cases in the present study presented complaint of swelling in the region of the thyroid. Only few patients presented with pain, discomfort and dysphagia. All the mentioned additional symptoms were of mild degree. Out of 55 cases, 3 cases had pain, 3 cases had discomfort and another 2 had dysphagia. Also none of the patient had lymphadenopathy which was confirmed by ultrasonographic examination. Two patients had symptoms of thyrotoxicosis, and one had features of hypothyroidism. The latter patients' thyroid profile confirmed the functional status.

In our study, duration of onset symptoms varied from 15 days to 8 years. Also duration of malignant nodules extend from 1 month to 4 years.

Out of 55 cases studied, 28 cases presented with nodule in right lobe of the thyroid gland and the remainder in the left lobe of thyroid. One patient among left sided solitary nodule had undergone right lobectomy 30 years back and presented with recurrent nodule in the rest of the lobe.

In the present study, on clinical examination size of the nodule, in its largest dimension, varies from 2cm to 12cm. Most of the patients presented with the size of about 3 to 5 cm. in the study, as such there is no correlation between the size of the nodule and the occurrence malignant nodule.

Out of 55 cases, two presented with features of thyrotoxicosis, one with hypothyroidism and rest all were in euthyroid state. Patients with thyrotoxicosis were made euthyroid using antithyroid drugs and operated and both cases turned out to be toxic follicular adenoma. Patient with hypothyroidism was treated with thyroxine, USG neck revealed multiple nodules and managed by subtotal thyroidectomy, histopathological examination confirmed the diagnosis of multi-nodular goiter.

Fine Needle Aspiration Cytology is the important investigation in the evaluation of solitary nodule of thyroid. All 55 cases were subjected to FNAC during the course of evaluation. FNAC reports are mainly categorized into 6 entities- Benign, follicular neoplasm, suspicious (of malignancy), malignant, lymphocytic thyroiditis, cysts. In our study, out of 16 follicular neoplasms, two turned out to be follicular carcinoma. One suspicious (of papillary carcinoma) case confirmed papillary carcinoma on histopathological examination. Three cases of papillary carcinoma were diagnosed pre- operatively by FNAC alone. Table 1

Two cases diagnosed as cysts by FNAC confirmed to be simple cysts on histopathological examination.

**Table 1:** FNAC of solitary nodule of thyroid

FNAC reports	No. of patients
Benign	32
Follicular neoplasm	16
Suspicious	1
Malignant	3
Lymphocytic Thyroiditis	1
Cysts	2

Out of 55 cases studied, common causes of solitary nodule are MNG, follicular adenoma and adenomatous goiter; the most

common being MNG which constitutes about 33% of cases.

Follicular adenoma and adenomatous goiters found almost at the same incidences, accounting to 25% each.

Out of 55 cases, six were malignant – 4 papillary carcinoma and 2 follicular carcinoma. Ultrasonography detected suspicious findings in two cases among six malignant cases – 1 papillary and 1 follicular.

Three cases of papillary carcinoma were diagnosed with certainty by FNAC, one case was suspicious which turned out to be papillary CA on histopathological examination. Table 2  
Two cases of follicular carcinoma were diagnosed follicular neoplasm, one of them showed suspicious features on ultrasonographic examination.

**Table 2: Histopathological Examination**

HPE Reports	No. of patients
Follicular adenoma	14
Adenomatous goitre	14
MNG	18
Carcinoma	6
Lymphocytic thyroiditis	1
Simple cyst of thyroid	2
Total	55

From the study, out of 6 carcinoma, 4 were papillary and 2 follicular: no case of medullary or anaplastic or lymphoma was detected. Papillary carcinoma accounts to 67% and follicular carcinoma accounts to 33%.

### Discussion

The observations and results of the present study were compared with the available previous similar studies.

In the another study separately in 2005, it was reported the mean age at presentation as 36.7years and 38.6years respectively [9, 10]. Another researcher reported, in 2012, the mean age of presentation as 37years. From the present study, the mean age at presentation found to be 37.27years, correlates with the previous studies [11].

Most of the earlier series reported peak incidence of solitary nodule thyroid in the 3<sup>rd</sup> and 4<sup>th</sup> decades. In the present study, the peak incidence found to be 3<sup>rd</sup> to 5<sup>th</sup> decades, which constitutes about 60% of the cases studied.

In the study done by Dorairajan [4] (1996) and Das DK (1999) [12] reported ratio of sex incidence as 1:9 and 1:5.39 respectively. In the present study, its found to be 1:8.16, which correlates with previous studies [13, 14].

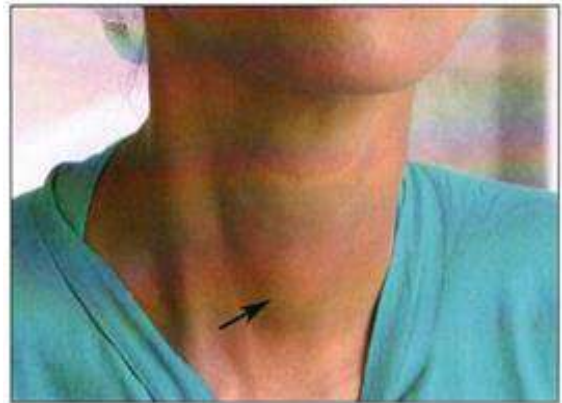Because of periods of fluctuations in the demands of the hormonal requirement in female in their life cycle (puberty, menstrual cycles, pregnancy, menopause), the chances of thyroid nodule formation are very high as compared with male counterparts.

In the present study, neoplastic conditions include adenomas and all malignant lesions. From the study, the ratio of non-neoplastic to neoplastic cases is about 1.89:1, which is comparable to the other studies done earlier.

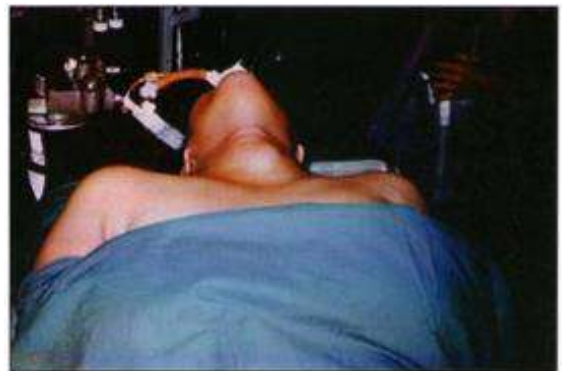In the present study, among 4 cases of papillary CA, 3 were diagnosed with certainty by FNAC and the rest one was suspicious of malignancy. But both the follicular CA were initially reported as follicular neoplasm. From the study, distribution of malignancy is about 7.27, which is comparable with the earlier studies.

From the present study, commonest cause of solitary nodule is MNG, which is comparable with the other studies. [15] The common causes are follicular adenoma and adenomatous goitre.

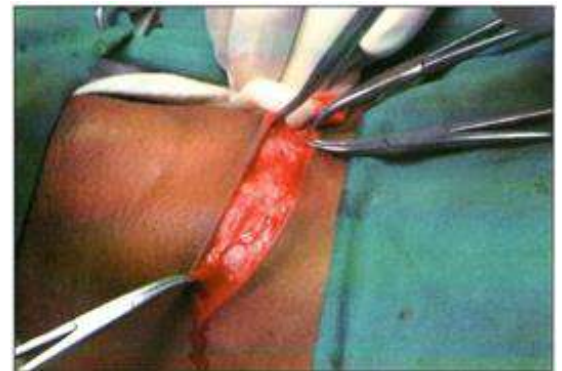From the literature, the incidence of malignancy in thyroid nodule ranges from 5% to 30%. From the present study, the incidence found to be 10.9%, which is comparable with the study done by Deshpande A *et al* [16].



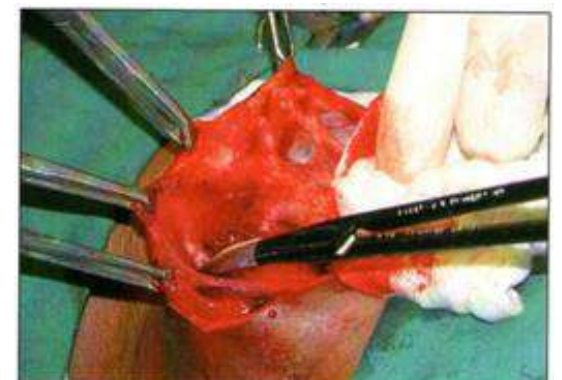
**Fig 1: Clinical picture of solitary nodule of thyroid**



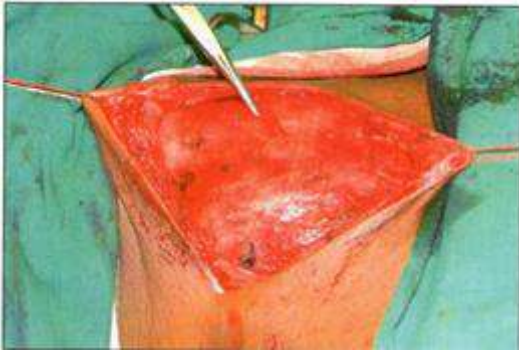**Fig 2: Position for thyroidectomy**



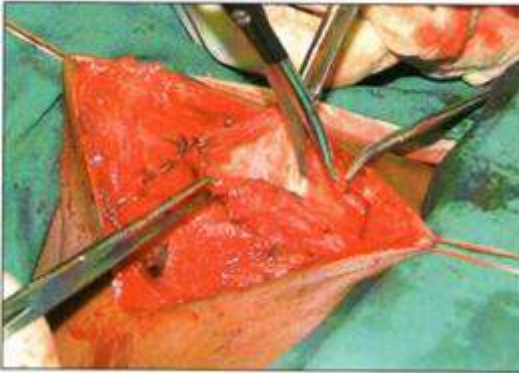
**Fig 3: Incision for thyroidectomy**



**Fig 4: Raising of flaps.**



**Fig 5:** Flaps raised exposing the strap muscles.



**Fig 6:** Opening of the strap muscles.

### Conclusion

It was concluded that Solitary nodule of thyroid is more common in females and in the age group of 20-50years. Most of the patients with solitary nodule of thyroid are in euthyroid state and only few present with toxicity and hypothyroidism. commonest cause of solitary nodule of thyroid is multi-nodular goitre. FNAC is the investigation of choice in the evaluation of solitary nodule of thyroid. It has few pitfalls. In such situations, only histopathology can confirm the exact pathology. It detects. papillary carcinoma in a solitary nodule with high sensitivity and specificity.

### Acknowledgements

I would like to express my profound gratitude to all my patients, for their cooperation and faith, without them it would be impossible to complete my study.

### Declarations

Funding: None

Conflict of interest: None

Ethical approval: Permission for the study was obtained from the College authorities prior to commencement.

### References

1. Cole WH, Majarakis JD. Incidence of carcinoma of thyroid in nodular goiter. *J Clin Endo Crinol* 1949;9:1007-11.
2. Gillespe C, Malis D. Evaluation and management of solitary thyroid nodule in a child. *Otolaryngol Clin N Am* 2003;36:117-28
3. Harrison BJ, Maddox PR, Smith Dm. Disorders of thyroid gland. In: Cuschieri A, Steele RJC, Moossa AR, editors. *Essential surgical practice*. 4<sup>th</sup> ed. London: Arnold 2002, 95-110.
4. Dorairajan N, Jayashree N. Solitary nodule of the thyroid and the role of fine needle aspiration cytology in diagnosis.

*J Indian Med Assoc* Feb 1996;94(2):50-2.

5. Burch HB. Evaluation and management of the solitary thyroid nodule. *Endocrinol Metab Clin North Am* 1995;24(4):663-94.
6. Belfiore A, Rosa GL. Fine needle aspiration biopsy of the thyroid. *Endocrinol Metab Clin North Am* 2001;30(2):361-94.
7. Krukowski ZH. The thyroid gland and the thyroglossal tract. In: Russel RCG, Williams NS, Chrstopher JK, Bulstrode, editors. *Bailey and love's – Short practice of surgery*. 24<sup>th</sup> ed. London: Arnold 2004, 776-805.
8. Oertel YC. Fine needle aspiration and the diagnosis of thyroid cancer. *Endocrinol Metab Clin North Am* 1996;25(1):69-90
9. Walton BR, Koch KE. Presentation and management of a thyroglossal duct cyst with a papillary carcinoma. *South Med J* 1997;90(7):758-761.
10. Wang CY, Chang TC. Preoperative thyroid ultrasonography and fine-needle aspiration cytology in ectopic thyroid. *Am Surg* 1995;61(12):1029-1031
11. Stahl WM Jr, Lyall D. Cervical cysts and fistulae of thyroglossal tract origin. *Ann Surg* 1954;139:123. [PubMed: 13114863]
12. Das S. The throid and parathyroids. In: Das S, editor. *A concise textbook of surgery*. 3<sup>rd</sup> ed. Calcutta 2004, 642-76.
13. Reed AF. The relations of the inferior laryngeal nerve to the inferior thyroid artery. *Anat Rec* 1943;85:17.
14. Lekacos NL, Tzardis PJ, Sfikakis PG, Patoulis SD, Restos SD. Course of the recurrent laryngeal nerve relative to the inferior thyroid artery and the suspensory ligament of Berry. *Int Surg* 1992;77:287. [PubMed: 1478811]
15. Kreyer R, Pomaroli A. Anastomosis between the external branch of the superior laryngeal nerve and the recurrent laryngeal nerve. *Clin Anat* 2000;13:79-82.
16. Deshpande A. Cytomorphology of Anaplastic thyroid carcinoma-a study of 35 cases. *J Cytol* 2005;22(4):165-70.