



E-ISSN: 2616-3470
P-ISSN: 2616-3462
© Surgery Science
www.surgeryscience.com
2019; 3(1): 149-153
Received: 22-11-2018
Accepted: 24-12-2018

Anil Kumar Sharma
Assistant Professor, Department of
General Surgery, J.L.N Medical
College Ajmer, Rajasthan, India

Mukesh Kumar
Postgraduate Resident,
Department of General Surgery,
J.L.N Medical College Ajmer,
Rajasthan, India

Amit Singh
Assistant Professor, Department of
General Surgery, J.L.N Medical
College Ajmer, Rajasthan, India

Rekha Porwal
Senior Professor and H.O.D.,
Department of General Surgery,
J.L.N Medical College Ajmer,
Rajasthan, India

Shruti K Somani
Postgraduate Resident,
Department of General Surgery,
J.L.N Medical College Ajmer,
Rajasthan, India

Aakanksha Soni
Postgraduate Resident,
Department of General Surgery,
J.L.N Medical College Ajmer,
Rajasthan, India

Correspondence
Amit Singh
Assistant Professor, Department of
General Surgery, J.L.N Medical
College Ajmer, Rajasthan, India

A prospective randomized study comparing ultrasonic dissector with monopolar electrocautery for dissection in modified radical mastectomy

Anil Kumar Sharma, Mukesh Kumar, Amit Singh, Rekha Porwal, Shruti K Somani and Aakanksha Soni

DOI: <https://doi.org/10.33545/surgery.2019.v3.i1c.28>

Abstract

Aim: The present study is designed to compare the efficacy and safety of ultrasonic dissector with monopolar electrocautery for dissection in modified radical mastectomy in terms of lymph vessels sealing, haemostasis, intra-operative and post-operative complications and hospital stay in patients of carcinoma breast.

Method: A prospective randomized controlled study of 70 patients of carcinoma breast was conducted at J.L.N. Medical College, Ajmer. The patients assigned in to two groups (35 in each) through randomization. Dissection in modified radical mastectomy was done by either ultrasonic dissector or monopolar electrocautery according to group allocation. Data was collected prospectively and analysed.

Results: Time for dissection and total duration of surgery, intra-operative blood loss, drainage volume, duration of drain and stay in hospital was significantly less while using ultrasonic dissector compared to using electrocautery. This was found statistically significant ($p < 0.05$). But no statistically significant differences were found in intra-operative complications and post-operative complications (like flap necrosis found in 5.7% patients with ultrasonic dissector and in 2.9% patients with electrocautery).

Conclusion: From our study, we can conclude that the ultrasonic dissector is as safe and effective as the electrocautery and its use has significant advantages over electrocautery in term of reduction of operative time, blood loss, post-operative drain volume and the number of days the drain was kept in situ and thereby the length of hospital stay. There was however no significant difference in the incidence of post-operative complications.

Keywords: Breast carcinoma, electrocautery, harmonic focus, modified radical mastectomy, ultrasonic dissector

Introduction

Breast carcinoma is the most frequently diagnosed cancer among women in world about 25.2% all cancer [1] while in India accounts 27% of all cancer [2] in women. As long term survival of breast cancer patients depends on stage of breast carcinoma at time of presentation, one of the main focuses of breast cancer management lies within the axillary region, as one of the primary metastatic pathways. Therefore axillary lymph node involvement is one of the most important prognostic factors (in patients with breast cancer) and axillary lymph node dissection has become a standard procedure within breast cancer treatment. Surgical treatment for breast cancer has shifted dramatically from radical operations to breast conserving surgical techniques. Modified radical mastectomy remains the most frequently performed surgical procedure for breast cancer.

The present study is designed to compare the efficacy and safety of ultrasonic dissector with electrocautery for dissection in modified radical mastectomy (MRM).

Method

A prospective randomized study of 70 patients of carcinoma breast was conducted at J.L.N. Medical College and Hospital, Ajmer. The candidates for the study were cases of carcinoma breast undergoing modified radical mastectomy (MRM).

All the 70 cases of carcinoma breast who met the inclusion and exclusion criteria of the study were allocated to either group A (Dissection using ultrasonic dissector) or group B (Dissection using electrocautery) by simple random technique through opaque sealed envelope technique.

Outcome Variables

1. Operative time for dissection in minutes
2. Intra-operative blood loss
3. Post-operative pain using VAS (visual analogue scale)
4. Drainage volume in ml
5. Duration of drain in days
6. Stay in Hospital in days
7. Post-operative complication like seroma formation, wound infection, hematoma, Flap necrosis

In our study, two drains were inserted intraoperative. The first was in the axilla and the second was under the skin flap. Both were connected to a closed suction drain bottle and the daily output was measured. The protocol for removal of the drain was output less than 30ml in 24 hours for two consecutive days. The patients were discharged 24 hours after removal of the drain.

Inclusion Criteria

The patients with operable carcinoma breast (T1-T4, N1-N2, and M0)

Exclusion Criteria

1. Metastatic breast carcinoma
2. History of previous axillary surgery
3. History of radiation therapy

Statistical Analysis

Statistical testing was conducted with the statistical package for the social science system version SPSS 17.0; IBM Corporation Chicago. Continuous variables are presented as mean \pm SD, and categorical variables are presented as absolute numbers and percentage. The comparison of normally distributed continuous variables between the groups was performed using Student's t test. Nominal categorical data between the groups were compared using Chi-squared test or Fisher's exact test as appropriate. $P < 0.05$ was considered statistically significant.

Results

The study included a total of 70 women divided into 2 groups. Group A had 35 patients who underwent MRM (Modified radical mastectomy) using the ultrasonic dissector (Harmonic focus). Group B consisted of 35 patients who underwent the same with dissection using electrocautery. The mean age in group A was 50.5 years and 51 years in group B.

The selected patients were then staged and treatment initiated. In group A 8.6% patients were in stage IIA, 22.9% patients were in stage IIB, 11.4% patients were in stage IIIA and 57.1% patients

were in stage IIIB. In group B 5.7% patients were in stage IIA, 40.0% patients were in stage IIB, 20.0% patients were in stage IIIA, 28.6% patients were in stage IIIB and 5.7% patients were in stage IIIC. (Figure.1).

The total duration of surgery in group A ranged from 57 to 110 mins (mean = 77.20 mins) and group B ranged from 65 to 120 mins (mean=90.2 mins). The difference is statistically significant ($p=0.001$). Comparing the variables, the time for axillary dissection was much shorter in group A than group B. While group A had an average time of 30.86 minutes (20 to 44 mins), group B had an average time of 40.63 minutes (27 to 50 mins). This difference was statistically significant ($p < 0.001$). (Table.1).

The mean mop count in group A was 5.51 ± 1.84 and in group B was 7.20 ± 1.32 . This difference was found to be statistically significant ($p < 0.001$). (Figure.2) Intra operative complication encountered was haemorrhage in 2 patients in group B. This was not found statistically significant ($p > 0.05$). Nerve injury or injury to any other structure was not encountered. (Figure.3)

Postoperative mean pain between the two groups was found to be statistically not significant in group A (5.63 ± 1.00) and in group B (5.80 ± 0.93) ($p > 0.05$). The post-operative drain output between the two groups was compared. The post-operative drain output was less in group A than group B. The mean POD1 drain output in group A was 101.14 ± 17.28 ml (80 to 150 ml) and in group B was 120.57 ± 21.96 ml (80 to 150 ml), POD2 drain output in group A was 44.57 ± 17.38 ml (20 to 100 ml) and in group B was 66.57 ± 23.13 ml (30 to 100 ml), POD3 drain output in group A was 15.74 ± 8.63 ml (5 to 40 ml) and in group B was 31.86 ± 18.31 ml (5 to 70 ml). The mean total drain output for first three days in group A was 161.00 ± 40.38 ml (100 to 280 ml) and in group B was 219.00 ± 60.46 ml (115 to 310 ml). This difference was found to be statistically significant ($p < 0.001$). (Table. 2,).

The mean duration of stay in hospital in group A was 5.00 ± 0.54 days (4 to 7 days) and in group B was 5.83 ± 0.89 days (4 to 8 days). This result was found to be statistically significant ($p < 0.001$). The patients were followed up on day 7, day 15 and 1 month after surgery. The results are as follows: in group A, 2 patients had flap necrosis while in group B only 1 patient had flap necrosis. Seroma formation was noted in 3 patients in group B and none in group A. The results were statistically non-significant in both the complication. Other complications like haematoma & wound infection were not encountered. (Table.3, Figure.4).

Table 1: Mean time taken for total surgery and time taken for axillary dissection.

	Group A (n=35)		Group B (n=35)		P value
	Mean \pm SD	Min-Max	Mean \pm SD	Min-Max	
Total duration of surgery (minutes)	77.20 \pm 14.79	57-110	90.20 \pm 14.47	65-120	0.001
Time for axillary dissection (minutes)	30.86 \pm 5.79	20-44	40.63 \pm 6.07	27-50	≤ 0.001

Table 2: Mean drain output in first 3days

	Group A (n=35)		Group B (n=35)		P value
	Mean \pm SD	Min-Max	Mean \pm SD	Min-Max	
POD1 Drain output (ml)	101.14 \pm 17.28	80-150	120.57 \pm 21.96	80-150	≤ 0.001
POD2 Drain output (ml)	44.57 \pm 17.38	20-100	66.57 \pm 23.13	30-100	≤ 0.001
POD3 Drain output (ml)	15.74 \pm 8.63	5-40	31.86 \pm 18.31	5-70	≤ 0.001
Total Drain output (ml)	161.00 \pm 40.38	100-280	219.00 \pm 60.46	115-310	≤ 0.001

Table 3: Comparison of Post-operative complications at different time intervals

Complications	Group A (n=35)		Group B (n=35)		P value
	Frequency	%	Frequency	%	
Flap necrosis					
1-7 days	1	2.9%	1	2.9%	1.000
7-15 days	1	2.9%	0	0.00%	1.000
1 month	0	0.00%	0	0.00%	-
Seroma formation					
1-7 days	0	0.00%	2	5.7%	0.493
7-15 days	0	0.00%	1	2.9%	1.000
1 month	0	0.00%	0	0.00%	-

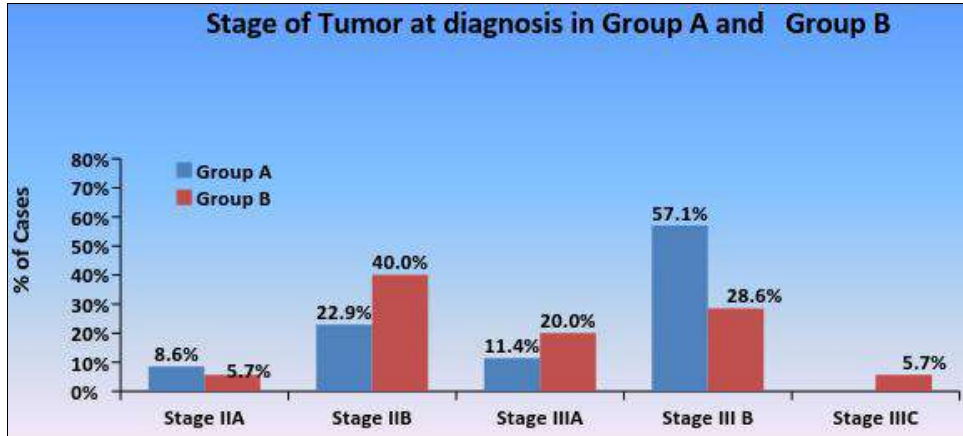


Fig 1: Graph showing the distribution in different stages.

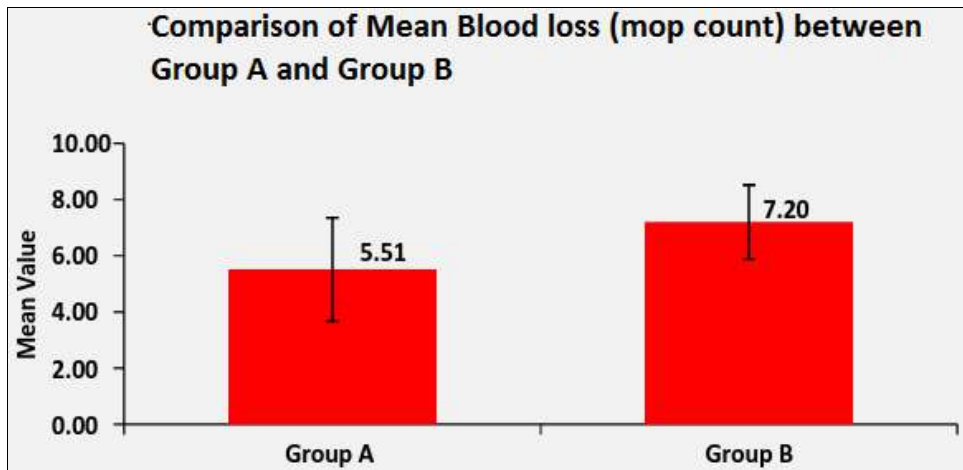


Fig 2: Graph comparing the blood loss

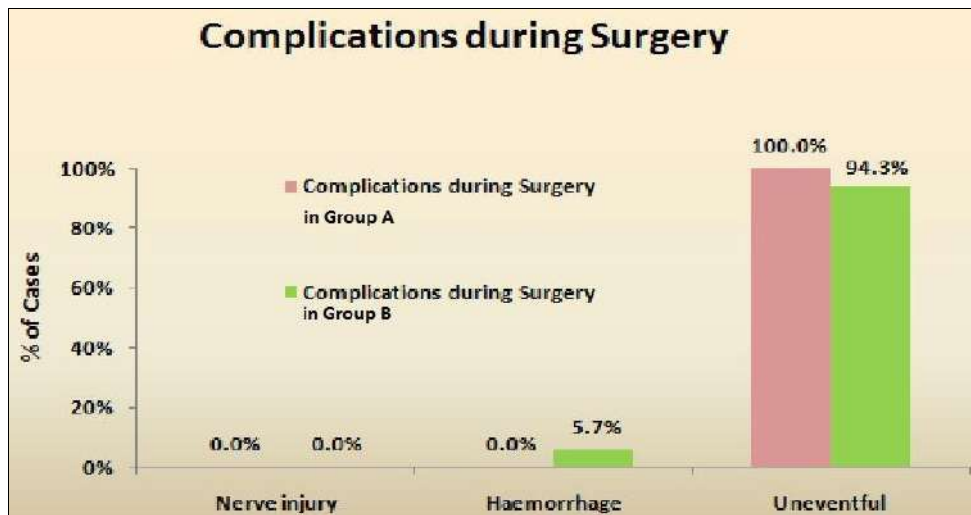


Fig 3: Graph showing complications encountered intraoperative

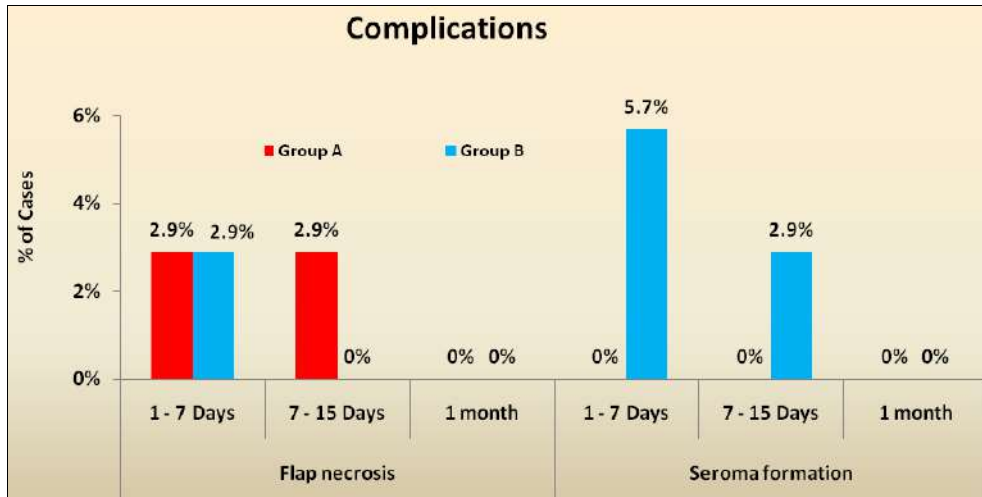


Fig 4: Graph showing the complications at different time intervals

Discussion

The electrocautery has been in use for mastectomies since 1970s and it has been proved to significantly reduce the operative time and blood loss compared to the conventional scalpel. It is however, also associated with an increase in complications of the surgical wound. Apart from seroma, cellulitis, infections and necrosis has been suggested to increase with electrocautery. It has been demonstrated that skin flaps created by steel scalpel have better tensile strength, fibroblastic activity, contain more collagen and fewer leucocytes and have lower wound drainage as compared to electrocautery. The reason behind the adverse effects of electrocautery on wound healing is that electrocautery uses direct thermal heat that penetrates into deeper tissues resulting in more devitalized tissue, and lyses of subcutaneous tissues [3].

The harmonic scalpel has been in use since the 1990s [4]. It is made up of a disposable cutting device and a generator. Piezoelectric crystals are used to convert the electric energy into mechanical energy (ultrasonic waves) [3]. The hand piece of the device vibrates at 55,500 Hz and the energy transferred into the tissues causes breakage of hydrogen bonds and the formation of denatured protein coagulum. This coagulum seals off the vessels and lymphatic resulting in decreased blood loss and lymphatic drainage [5]. Thus the effects of the harmonic scalpel are cavitation, coagulation and cutting abilities [3]. This energy, unlike electrocautery, penetrates only 25-100µm and comparatively produces less thermal energy [3] (temperature not exceeding 150°C) [6].

In a study by Deo S.V.S, Shukla N.K, Asthana N. *et al.* [5] they described their experience with the harmonic scalpel (ultracision). Their study concluded that the ultracision reduced the blood loss and the duration of drainage. This result has been consistent with our study. The mop count used to measure blood loss was much lower (mean= 5.51) as compared to the electrocautery group (mean= 7.20). This result is also consistent with studies conducted by Sanguinetti, *et al.* [7], Mori T, Abe H, Kawai Y, *et al.* [8] He Q, Zhuang D, Zheng L, *et al.* [9] and Adwani A and Ebbs SR [10].

In our study, we observed a reduction in the time required for axillary dissection (p<0.001) as well as the duration of surgery (p = 0.001). This has been demonstrated in a study by Mori T, Abe H, Kawai Y, *et al.* [8] where they compared the Harmonic Focus with electrocautery.

There was no significant difference noted in our study with regards to other intra operative complications or post-operative

pain (p>0.05 in both variables).

With regard to the drain output, there was significant reduction in the drain output volume on the first 3 post-op days as well as the number of days the drain was in-situ. The drain output on day 1 had a mean of 101.14 ml in ultrasonic group as compared to 120.57 ml in electrocautery group (p<0.001). The drain output in the subsequent days showed a similar difference. It can thus be concluded that the ultrasonic dissector reduces the drainage volume when compared to electrocautery. This is supported by many other studies carried out by S.V.S, Shukla N.K, Asthana N. *et al.* [5] Sanguinetti, *et al.* [7] Huang J, Yu Y, Wei C, *et al.* [11] and Mori T, Abe H, Kawai Y, *et al.* [8] To quote a few. The number of days the drain was kept in-situ also showed a significant difference (4.17 vs 4.89 days, p<0.001).

In our study we did not observe any significant difference in the post-operative complication. In a total of 70 patients, 3 patients developed seroma and 3 had skin flap necrosis. Out of this, all 3 patients who developed seroma belonged to group B (electrocautery group). 2 of them developed seroma in the first 7 post-op days while the third developed in the second week post-op. Of those who had skin flap necrosis, 2 were from group A, the first having skin necrosis in the first 7 days while the other in the second week. The third patient, who belonged in group B, presented with skin necrosis within the first 7 days. The difference was not significant (p>0.05) in both the complications. We thus concluded that the use of ultrasonic dissector did not have significance in the reduction of complications like seroma formation or flap necrosis when compared to electrocautery. This is supported by Adwani A and Ebbs SR [10], and Kontos M, Kothari A, Hamed H [12] in their studies where they did not find any significant difference in the rate of seroma formation when comparing the Harmonic scalpel with electrocautery in axillary dissection.

In our study we have observed a significant reduction in the blood loss, duration of surgery and duration of axillary dissection while using the Harmonic scalpel. With regards to the complications, there was no significant reduction in the incidence of Seroma or flap necrosis.

Conclusion

We can thus conclude that the ultrasonic dissector is as safe and effective as the electrocautery and its use has significant advantages over electrocautery in terms of reduction of operative time, blood loss, post-operative drain volume and the number of days the drain was kept in-situ and thereby the length

of hospital stay. There was however no significant difference in the incidence of post-operative complications.

Limitations

The limitations of our study:

No long-term follow-up for other complications like lymphedema.

References

1. Globocan. World Fact Sheet, Selection of Cancer Information, International Agency for Research on Cancer, Lyon, France, 2013.
2. Globocan. India Fact Sheet, Selection of Cancer Information, International Agency for Research on Cancer, Lyon, France, 2013.
3. Yilmaz KB, Dogan L, Nalbant H, Akinci M, Karaman N, Ozaslan C *et al.* Comparing scalpel, electrocautery and ultrasonic dissector effects: the impact on wound complications and pro-inflammatory cytokine levels in wound fluid from mastectomy patients. *Journal of breast cancer.* 2011; 14:58-63.
4. Ribeiro GH, Kerr LM, Haikel RL, Peres SV, Matthes AG, Depieri Michelli RA *et al.* Modified radical mastectomy: a pilot clinical trial comparing the use of conventional electric scalpel and harmonic scalpel. *International journal of surgery (London, England).* 2013; 11:496-500.
5. Deo SV, Shukla NK, Asthana S, Niranjana B, Srinivas G. A comparative study of modified radical mastectomy using harmonic scalpel and electrocautery. *Singapore Medical Journal.* 2002; 43:226-228.
6. Rohaizak M, Khan FJ, Jasmin JS, Mohd Latar NH, Abdullah SS. Ultracision versus electrocautery in performing modified radical mastectomy and axillary lymph node dissection for breast cancer: a prospective randomized control trial. *The Medical Journal of Malaysia.* 2013; 68:204-207.
7. Sanguinetti A, Docimo G, Ragusa M, Calzolari F, D'Ajello F, Ruggiero R *et al.* Ultrasound scissors versus electrocautery in axillary dissection: our experience. *G Chir.* 2010; 31:151e3.
8. Mori T, Abe H, Kawai Y *et al.* A prospective randomized trial comparing harmonic scalpel and electrocautery in breast surgery *J Clin Oncol.* 2013; 31(e12014).
9. He Q, Zhuang D, Zheng L, Fan Z, Zhou P, Zhu J *et al.* Harmonic focus versus electrocautery in axillary lymph node dissection for breast cancer: a randomized clinical study. *Clin Breast Cancer.* 2012; 12(6):454-458.
10. Adwani A, Ebbs SR. Ultracision reduces acute blood loss but not seroma formation after mastectomy and axillary dissection: a pilot study. *Int J Clin Pract.* 2006; 60:562-564.
11. Huang J, Yu Y, Wei C, Qin Q, Mo Q, Yang W. Harmonic Scalpel versus Electrocautery Dissection in Modified Radical Mastectomy for Breast Cancer: A Meta-Analysis. *Plos.org,* 2015.
12. Kontos M, Kothari A, Hamed H. Effect of harmonic scalpel on seroma formation following surgery for breast cancer: a prospective randomized study. *Journal of BUON: official journal of the Balkan Union of Oncology.* 2008; 13:223-230.