



E-ISSN: 2616-3470

P-ISSN: 2616-3462

© Surgery Science

[www.surgeryscience.com](http://www.surgeryscience.com)

2021; 5(3): 68-69

Received: 10-05-2021

Accepted: 24-06-2021

**Ujjawal Jain**

Junior Resident, Department of  
General Surgery, Indira Gandhi  
Medical College, Shimla, Himachal  
Pradesh, India

**Vivek Rajdev**

Junior Resident, Department of  
General Surgery, Indira Gandhi  
Medical College, Shimla, Himachal  
Pradesh, India

**Mukul Sharma**

Senior Resident, Department of  
General Surgery, Indira Gandhi  
Medical College, Shimla, Himachal  
Pradesh, India

**Arun Chauhan**

Associate Professor, Department of  
General Surgery, Indira Gandhi  
Medical College, Shimla, Himachal  
Pradesh, India

**Corresponding Author:**

**Ujjawal Jain**

Junior Resident, Department of  
General Surgery, Indira Gandhi  
Medical College, Shimla, Himachal  
Pradesh, India

## Isolated pelvic hydatidosis: A rare presentation of a common disease

**Ujjawal Jain, Vivek Rajdev, Mukul Sharma and Arun Chauhan**

**DOI:** <https://doi.org/10.33545/surgery.2021.v5.i3a.736>

### Abstract

Hydatid cyst is a zoonotic disease caused by tapeworm of the genus *Echinococcus*. Humans act as accidental or dead-end host. It commonly affects liver, lungs and kidneys. A pelvic hydatid cyst is usually secondary to hydatid cyst involving other organs. Isolated primary pelvic hydatid cyst is a rare entity, occurring in 0.2-2% cases. The present case is a 46 years old male with primary pelvic hydatid cyst who was managed by surgical evacuation of cyst along with albendazole therapy.

**Keywords:** Hydatid cyst, pelvic hydatid cyst, echinococcosis, pelvic hydatidosis

### Introduction

Echinococcosis (hydatid disease) is a zoonosis caused by the larval (metacestode) stages of flat worms belonging to the genus *Echinococcus* and the family Taeniidae<sup>[1]</sup>. Humans are accidental intermediate (dead end) hosts and animals (herbivores and omnivores) are both intermediate and definitive hosts<sup>[2]</sup>. Four species identified are *E. granulosus*, *E. multilocularis*, *E. vogeli* and *E. oligarthus*. The 2 main species responsible for human infection are *E. granulosus* and *E. multilocularis*<sup>[3]</sup>.

In humans, 50% to 75% of the cysts occur in the liver, 25% are located in the lungs, but they can be found in any organ of the body<sup>[4]</sup>. Primary pelvic hydatid cyst without any evidence of any other site involvement is rare and reported to be 0.2% to 2% of all hydatid disease cases. It usually presents with pressure symptoms on surrounding structures such as rectum and urinary bladder<sup>[5]</sup>. We are presenting a case report of primary pelvic hydatid cyst presenting with obstructive symptoms to both rectum and urinary bladder.

### Case Report

A 46 years old gentleman presented with complaints of dull aching pain in lower abdomen for 3 months and swelling in lower abdomen for 2 months, increased frequency of micturition with feeling of incomplete evacuation of bladder, post void dribbling and constipation. There was no history of nausea, vomiting, fever, jaundice, hematuria or bleeding per rectum.

On examination, his pulse rate was 76 beats/min and blood pressure was 118/78 mm of mercury. General physical examination was normal. Abdominal examination revealed a smooth, firm, slightly tender and non-mobile lump palpable just above the pubic symphysis with lower margins not palpable. On digital rectal examination, prostate was normal, there was an external compression on anterior wall of rectum with minimal luminal narrowing with normal rectal mucosa.

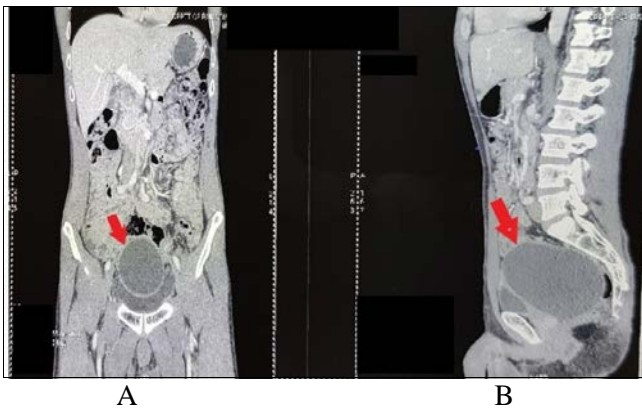
Investigations revealed Hemoglobin of 15.7 g/dL, platelet count of 2, 14, 000/cumm, Total Leukocyte Count of 6,700/cumm, serum urea of 20 mg/dL, creatinine of 0.70 mg/dL with normal serum electrolytes and normal liver function test. Urine culture was sterile. Serum *Echinococcus* IgG by Enzyme Linked Immuno-Sorbent Assay (ELISA) was positive. Chest X-ray and Electrocardiogram (ECG) were normal.

Ultrasonography (USG) revealed a well-defined, thin-walled cystic lesion of 10 x 15 cm posterosuperior to urinary bladder with no internal septations or calcifications. Liver and spleen were normal. Contrast Enhanced Computed Tomography (CECT) scan of abdomen and pelvis was suggestive of well-defined peripherally enhancing hypodense lesion of size 12 x 8 x 7 cm seen in the pelvis at the level of sacrum between urinary bladder and rectum with no obvious communication seen with urinary bladder or rectum (Fig.1).

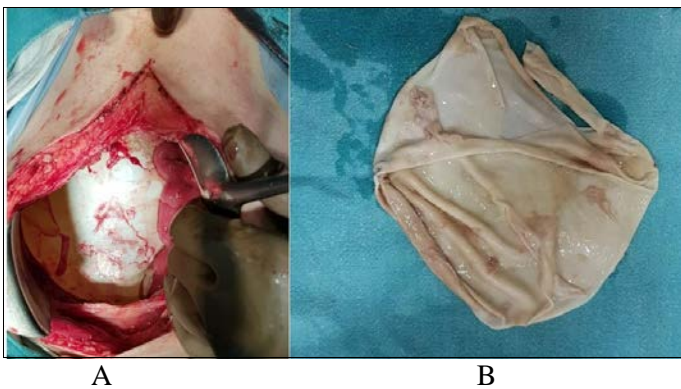
Patient was put on preoperative albendazole therapy for 1 month based on positive hydatid serology.

Exploratory laparotomy was done and liver, spleen and omentum were found normal. A 15 x 15 cm cystic lesion was found in the pelvis, behind the urinary bladder and in front of anterior wall of rectum with minimal adhesions present between cyst wall and surrounding structures (Fig.2a). Intact cystic lesion was delivered through the abdominal wound without any peritoneal spillage. A drain kept in pelvis and abdominal wound closed in layers. On cut section, cystic lesion had laminated membrane with clear hydatid fluid and no daughter cyst in the cavity (Fig.2b).

Post-operative period was uneventful. Patient was discharged on 5<sup>th</sup> post-operative day and was given albendazole therapy of 3 cycles of 28 days each with a gap of 2 weeks each and complete hemogram and Liver Function Tests were done in each gap period. Patient is asymptomatic on follow-up. Histopathology was suggestive of hydatid cyst.



**Fig 1a, b:** CECT scan of abdomen and pelvis showing well-defined peripherally enhancing hypodense lesion in the pelvis at the level of sacrum between urinary bladder and rectum in a) coronal plane b) sagittal plane (Original picture).



**Fig 2a, b:** a) Intra-operative picture of the primary pelvic hydatid cyst; b) Post-operative picture of the evacuated laminated membrane of the hydatid cyst.

## Discussion

Hydatid cyst is caused by various species of *Echinococcus* of family Taeniidae. Animals (Herbivores and omnivores) serve as both intermediate and definitive hosts for this disease. Humans on the other hand are infected accidentally and are termed as dead end hosts [1, 3].

In humans, the parasite passes through filter of liver and lung therefore liver and lungs are the most common site involved. Usually, pelvic hydatidosis are secondary to rupture of liver or spleen hydatid cyst. Primary pelvic hydatid is defined when

there is no other hydatid cyst present in liver, spleen or any other intra-abdominal organ and is a rare entity with 0.2%-2% cases reported. Pathophysiology is not well understood and there are theories of direct hematogenous and lymphatic spread and deposits into pelvic cavity. According to another theory, small liver hydatid cyst rupture and undergo spontaneous resolution, while its contents get peritoneal seedling [6].

Primary pelvic hydatid cyst can present as cystic mass arising from pelvis with pressure effects on adjacent structures leading to obstructive uropathy, constipation or obstructed labour [7]. Hydatid cyst should be considered in differential diagnosis of an unusual pelvic mass in a patient living in endemic area. Serological test may be helpful but should be interpreted in correlation with epidemiological data, clinical features and imaging investigations.

USG and CECT scan may aid in determining exact location and nature of cystic mass in pelvis and also exclude hydatid cyst of any other organ. Gharbi classification on USG is well accepted even for primary pelvic hydatid cyst [8].

Combination of surgery and albendazole therapy are useful modalities of treatment. Pre-operative diagnosis may help in selecting correct course in treatment with use of pre-operative albendazole therapy, preventing spillage in abdominal cavity and post-operative albendazole therapy [9].

## Conclusion

Isolated pelvic hydatid cyst is a rare entity, even in endemic countries like India. It can be asymptomatic or may present with features of bladder and/or bowel obstruction. Diagnosis is by hydatid serology and imaging modalities. It is treated by surgical excision along with pre- and post-operative albendazole therapy. A high index of suspicion is warranted in endemic areas for early diagnosis and institution of adequate preoperative medical therapy.

## References

1. Ravis E, Theron A, Lecomte B, Gariboldi V. Pulmonary cyst embolism: A rare complication of hydatidosis. *Eur J Cardiothoracic Surg* 2018;53(1):286-287. Doi: 10.1093/ejcts/ezx286.
2. Eckert J, Deplazes P. Biological, epidemiological, and clinical aspects of echinococcosis, a zoonosis of increasing concern. *Clin Microbiol Rev* 2004;17(1):107-35. Doi: 10.1128/CMR.17.1.107-135.2004.
3. Agudelo Higuera NI, Brunetti E, McCloskey C. Cystic Echinococcosis. *J Clin Microbiol* 2016;54(3):518-23. Doi: 10.1128/JCM.02420-15.
4. McManus DP, Zhang W, Li J, Bartley PB. Echinococcosis. *Lancet* 2003;362(9392):1295-304. Doi: 10.1016/S0140-6736(03)14573-4.
5. Kumar N, Garg R, Namdeo R. Primary pelvic hydatid cyst: A rare case presenting with obstructive uropathy. *Int J Surg Case Rep* 2018;53:277-280. doi:10.1016/j.ijscr.2018.09.044
6. Singh S, Reddy M. A rare case of primary peritoneal hydatid cyst. *Int J Reprod Contracept Obstet Gynecol* 2017;6:360-3. Doi:10.18203/2320-1770.ijrcog20164698
7. Seenu V, Misra MC, Tiwari SC, Jain R, Chandrashekhar C. Primary pelvic hydatid cyst presenting with obstructive uropathy and renal failure. *Postgrad Med J* 1994;70(830):930-932. Doi:10.1136/pgmj.70.830.930
8. Sarkar S, Sanyal P, Das MK, Kumar S, Panja S. Acute Urinary Retention due to Primary Pelvic Hydatid Cyst: A Rare Case Report and Literature Review. *J Clin Diagn Res* 2016;10(4):PD06-PD8. Doi: 10.7860/JCDR/2016/17831.7550
9. Shams-Ul-Bari, Arif SH, Malik AA, Khaja AR, Dass TA, Naikoo ZA. Role of albendazole in the management of hydatid cyst liver. *Saudi J Gastroenterology* 2011;17(5):343-347. Doi:10.4103/1319-3767.84493