



International Journal of Surgery Science

E-ISSN: 2616-3470
P-ISSN: 2616-3462
© Surgery Science
www.surgeryscience.com
2019; 3(1): 156-158
Received: 28-11-2018
Accepted: 30-12-2018

Dr. Honeypalsinh H Maharaul
Assistant Professor, Department of
Surgery, SBKSMIRC, Sumandeep,
Vidyapeeth, Pipariya, Vadodara,
Gujarat, India

Dr. Devalbhai M Patel
Resident, Department of Surgery,
SBKSMIRC, Sumandeep,
Vidyapeeth, Pipariya, Vadodara,
Gujarat, India

Use of staplers in gastrointestinal surgery in comparison to conventional hand suture methods

Dr. Honeypalsinh H Maharaul and Dr. Devalbhai M Patel

DOI: <https://doi.org/10.33545/surgery.2019.v3.i1c.30>

Abstract

Introduction: An anastomosis becomes necessary when a segment of the gastrointestinal tract is resected for benign or malignant disease and gastrointestinal continuity needs to be restored. The two most commonly used anastomotic techniques are handsewn anastomosis and stapled anastomosis.

Aim of Study: The aim of my study is to evaluate the outcome of uses of stapler in gastrointestinal surgeries in comparison to conventional hand suture methods.

Objectives of the study:

- To assess the advantages and disadvantages of stapler use in gastrointestinal surgeries in terms of following:
 1. Mean operating time.
 2. Anastomosis Leak.
 3. Stricture formation.

Conclusion: Stapled anastomosis is better in terms of time, complication and cost effective than Handsewn anastomosis.

Keywords: Staplers, gastrointestinal, conventional

Introduction

An anastomosis becomes necessary when a segment of the gastrointestinal tract is resected for benign or malignant disease and gastrointestinal continuity needs to be restored. The resected segment can be anywhere between the pharynx and the anus ^[1]. A successful anastomosis needs a well-nourished patient with no systemic illness, no fecal or purulent contamination, gentle tissue handling, well-vascularized tissues, adequate hemostasis, and meticulous surgical technique besides other factors ^[2, 3, 4]. Important complications following intestinal anastomosis include anastomotic leak, bleeding, wound infection, anastomotic site stricture, and prolonged functional ileus, especially in children. The two most commonly used anastomotic techniques are handsewn anastomosis and stapled anastomosis.

Material & methods

All patients admitted at Dhiraj general Hospital posted for laparotomy for resection anastomosis were explained about the risk factor.

A detailed history was taken and all patients were subjected to thorough clinical examination including per abdominal and per rectal examination. Routine lab investigations like blood and screening of chest were done.

Data was analysed postoperatively and other post-operative complications such as

- 1) Early complication -Anastomosis leak
- 2) Late complication- Stricture formation
- 3) Recovery time to normal function

All patients were followed up at 1 week, 15 days, 3 months post operatively.

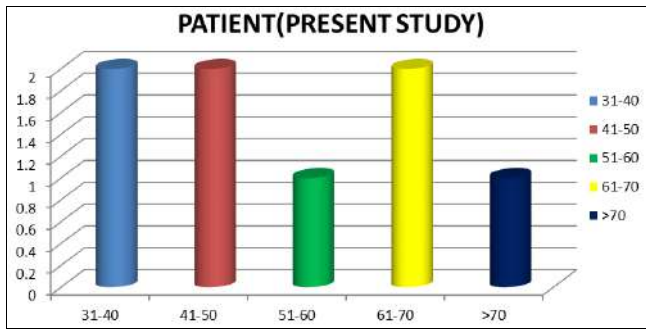
Correspondence

Dr. Devalbhai M Patel
Resident, Department of Surgery,
SBKSMIRC, Sumandeep,
Vidyapeeth, Pipariya, Vadodara,
Gujarat, India

Result and Discussion

1) Age Distribution

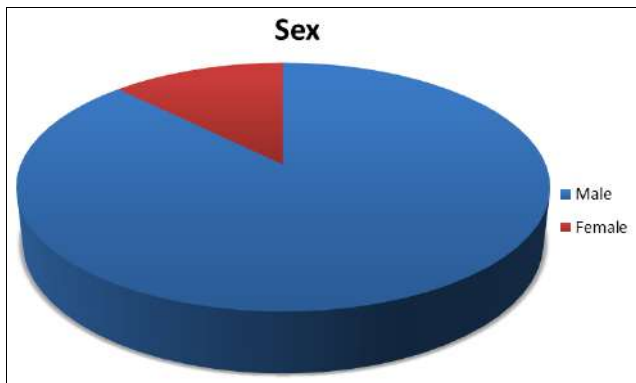
Age Group	Patient(Present Study)
31-40	2
41-50	2
51-60	1
61-70	2
>70	1



In present study patient belonged to various age group were enrolled in study. No Age predominance was found.

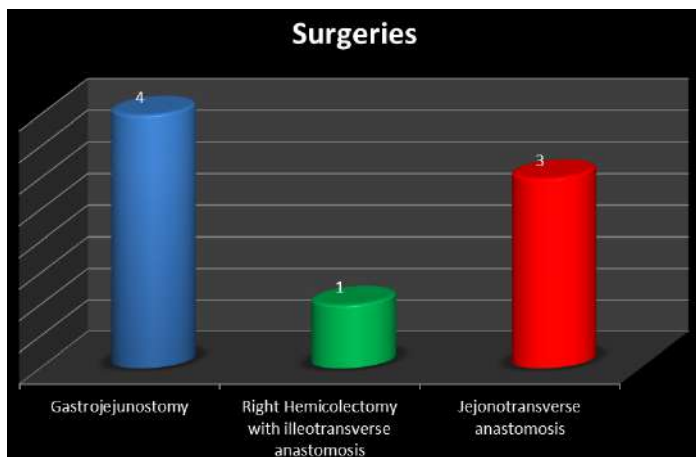
2) Sex Distribution

Sex	Male	Female
Study	7	1



There were 7 male and 1 female patients. Male Predominance was found in present study

3) Surgeries



Gastrojejunostomy was done in 4 patient benign pyloric stenosis (Gastric Outlet Obstruction)

1. Patient with with multiple caecal ulcers underwent Right hemicolectomy with illeotransverse anastomosis.
2. Patient underwent jejunotransverse anastomosis (Figure 1&2) for Small bowel ischemia.

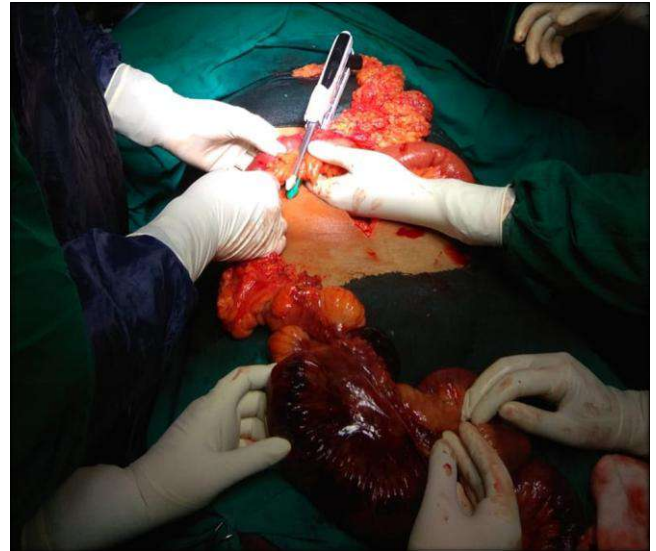


Fig 1: Jejunotransverse anastomosis for ischemic bowel.

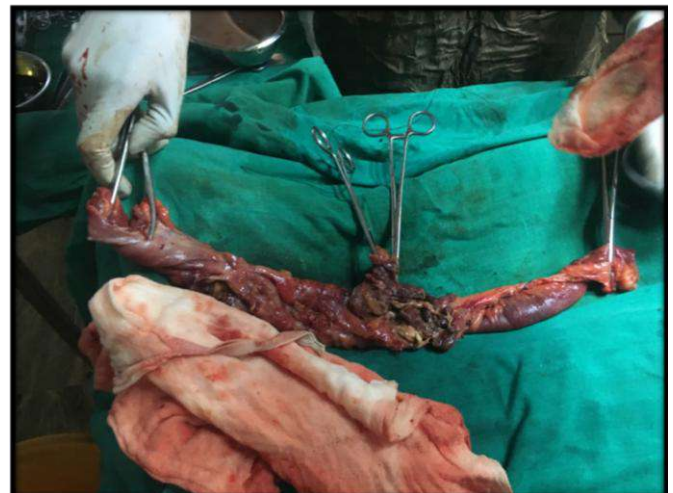

Fig 2: Resected specimen: Caecum with ileum and ascending colon

4) Time of surgery

Time Of Surgery	No. Of Surgery
45-60 min	4
61-90 min	3
>90 min	1

Most of surgery was completed in 60 minutes with the help of stapler while 3 surgeries took up to 90 min and 1 surgery took 2 hrs.

5) Complication

Complications	No
Anatomises leak	0
Stricture Formation	0

None of the patient developed complication in our study

Conclusion

Stapled anastomosis is better in terms of time, complication and cost effective than Handsewn anastomosis.

References

1. American College of Surgeons: Principles and Practice. Intestinal Anastomosis, 644-55.
2. Kate V, Roberts KE. Intestinal Anastomosis. Medscape, 2011.
3. Nichols RL, Condon RE. Preoperative preparation of the colon. Surg Gynecol Obstet. 1971; 132:323-37.
4. Güenaga KF, Matos D, Wille-Jørgensen P. Mechanical bowel preparation for elective colorectal surgery. Cochrane Database Syst Rev, 2011; CD001544.
5. Lammers Richard L, Trott Alexander T. Methods of wound closure. In: Roberts JR, Hedges JR, editors. Clinical Procedures in Emergency Medicine. 4th ed. Philadelphia: Saunders, 671.
6. Catena F, La Donna M, Gagliardi S, Avanzolini A, Taffurelli M. Stapled versus hand-sewn anastomosis in emergency intestinal surgery. Results of a prospective randomized study. Surg Today. 2004; 34:123-6.
7. Zeebregts CJ, Heijmen RH, van den Dungen JJ, van Schilfgaarde R. Non-suture methods of vascular anastomosis. Br J Surg. 2003; 90:261-71.
8. Sandor I. Hútl-felefelekapsosgyomorbelvarrasesegy u varromuszerismertetese. Orv Hetil. 1936; 80:657.
9. Kolvenbach R, Shiffrin E, Schwierz E, Wassiljew S, Caggianos C. Evaluation of an aortic stapler for an open aortic anastomosis. J Cardiovasc Surg (Torino). 2007; 48:659-65.
10. Shiffrin EG, Moore WS, Bell PR, Kolvenbach R, Daniline EI. Intravascular stapler for "open" aortic surgery: Preliminary results. Eur Vasc Endovasc Surg. 2007; 33:408-11.