



International Journal of Surgery Science

E-ISSN: 2616-3470

P-ISSN: 2616-3462

© Surgery Science

www.surgeryscience.com

2021; 5(4): 239-241

Received: 25-08-2021

Accepted: 27-09-2021

Dr. Mangesh Pawar

Assistant Professor, Kasturba
Hospital Burns Unit affiliated to
Department of Plastic Surgery,
BYL Nair Ch. Hospital and
TNMC, Mumbai, Maharashtra,
India

Dr. Nishant Tripathi

Senior Resident, Department of
Plastic Surgery, BYL Nair Ch.
Hospital and TNMC, Mumbai,
Maharashtra, India

Dr. Priyank Patwa

Senior Resident, Department of
Plastic Surgery, BYL Nair Ch.
Hospital and TNMC, Mumbai,
Maharashtra, India

Dr. Pooja Mistry

Senior Resident, Department of
Plastic Surgery, BYL Nair Ch.
Hospital and TNMC, Mumbai,
Maharashtra, India

Dr. Arvind Hosamani

Senior Resident, Department of
Plastic Surgery, BYL Nair Ch.
Hospital and TNMC, Mumbai,
Maharashtra, India

Corresponding Author:

Dr. Mangesh Pawar

Assistant Professor, Kasturba
Hospital Burns Unit affiliated to
Department of Plastic Surgery,
BYL Nair Ch. Hospital and
TNMC, Mumbai, Maharashtra,
India

A prospective, comparative study of outcomes with Melolin, collagen sheet and traditional vaseline gauze dressing for healing of skin graft donor site in burns cases

Dr. Mangesh Pawar, Dr. Nishant Tripathi, Dr. Priyank Patwa, Dr. Pooja Mistry and Dr. Arvind Hosamani

DOI: <https://doi.org/10.33545/surgery.2021.v5.i4d.793>

Abstract

Donor site following skin graft harvest have plenty of options available for dressing. We compared outcomes of Melolin, Collagen sheet and traditional Vaseline gauze for this purpose.

Aim: The aim of the present study was to evaluate the outcomes Melolin, Collagen sheet and traditional Vaseline gauze for healing of skin graft donor site.

Materials and Methods: Total 45 patients of Skin grafting procedure between August 2020 and July 2021 Burns unit affiliated to a tertiary care-teaching unit in Mumbai were taken in this research. Data was collected as VAS scores for pain evaluation, re-epithelialization time in days, infection rate and VSS score for scar quality for each dressing material. Mean Values of all parameters were calculated and compared.

Results: Mean VAS score in Melolin group was 3.6, Collagen sheet group was 2.73 and Vaseline gauze group was 5.2. Re-epithelialization in Melolin group was achieved in 13.53 days (Mean), Collagen sheet group in 12.73 days (Mean) and Vaseline gauze group in 15.2 days (Mean). Mean Infection rate in Melolin group was 0.2143, Collagen sheet group was 0.0667 whereas Vaseline gauze showed 0.3333. Mean VSS score of 4.73 in Melolin group, 4.6 in Collagen sheet group and 5.2 in Vaseline gauze group. Mean VSS score of 4.73 in Melolin group, 4.6 in Collagen sheet group and 5.2 in Vaseline gauze group.

Conclusion: Melolin, Collagen Sheet showed low pain scores, faster re-epithelialization, low infection rate and comparable VSS scores with regularly used Vaseline gauze.

Keywords: Melolin, collagen sheet, traditional vaseline gauze dressing, skin graft

Introduction

Burns wound heal by re-epithelialization. The deep wounds, which fail to re-epithelialize, requires closure by skin grafting leading to additional wound. The donor site wound following the harvest of skin graft heals by re-epithelialization. Until it re-epithelializes, it requires coverage by a temporary dressing. The options for this purpose are plenty however commonly a 'Vaseline gauze' impregnated with topical antimicrobial agent is used in many centers^[1]. These dressings are known to dry with time thus the moist wound environment is not maintained. They are also associated with infection, pain and blood oozing from the donor site during dressing change. To overcome these problems we have used Melolin and Collagen sheet for donor site dressing and compared its outcome with regularly used Vaseline gauze. This paper describes efficacy of three different dressing material namely Melolin, Collagen sheet and Vaseline gauze in skin graft donor site wound healing.

Material and Methods

This was a prospective randomized study comparing the effectiveness of three dressing material- Melolin, Collagen sheet and Vaseline gauze for skin graft donor site dressing in burns cases. The study was done in conformity with the guiding statements of 'Declaration of Helsinki'. Informed consent was obtained from all cases participating in this research. In August 2020- July 2021, this research was conducted in a Burns unit affiliated to a tertiary care-teaching unit in Mumbai. Total 45 participants were included in the study. Participants were divided in three groups (15 each) as described below.

Following harvest of partial thickness skin graft and hemostasis of the donor site, the donor area in first group was covered with Melolin sheet as a first layer, followed by a layer of Gamjee cotton roll dressing. The above two dressing layer were then supported by a roller bandage followed by a crepe bandage. The entire dressing was removed on third day, after wound wash similar dressing was reapplied until re-epithelialization was achieved.

The donor area in second group was covered with a wet saline washed collagen sheet as a first layer. Once the collagen sheet was dried it was then covered with a layer of Gamjee cotton roll dressing. The above two dressing layer were then supported by a roller bandage followed by a crepe bandage. All the layers of dressing except the adherent collagen was removed by around fifth to seventh day. After wound wash again a new collagen sheet was applied over the wound and it was covered again in a similar fashion as mentioned above till complete re-epithelialization.

The donor area in third group was covered with a layer of vaseline gauze. Followed by Gamjee cotton roll, roller bandage and crepe bandage from inside to outside. On next day the dressing was changed except the adherent vaseline gauze and it was repeated until complete re-epithelialization was achieved.

The efficacy of the three dressing material was compared by following parameters.

- 1) Pain severity using Visual Analogue Scale score (VAS score). VAS score at the end of 1 hour following dressing was noted [2].
- 2) Infection rate (erythema, exudate, wound swab for bacteriology)
- 3) Re-epithelialization time in days (From surgery day to complete healing)
- 4) Scar quality using Vancouver scar scale (VSS Score). VSS score was noted at the end of 1 month following healing of the donor wound [3].

The above data was collected and Mean Values of each parameter was calculated. The Mean Values were compared by statistical analysis to study the efficacy of each dressing material for donor site dressing.

Results

Total 45 patients were included in the study ranging from 20 to 55 years. They were divided into three groups with 15 participants in each group.

Mean VAS score in Melolin group was 3.6, Collagen sheet group was 2.73 and Vaseline gauze group was 5.2. On comparison of the above mean VAS score, a statistically significant p-value of <.00001 was obtained (Figure 1).

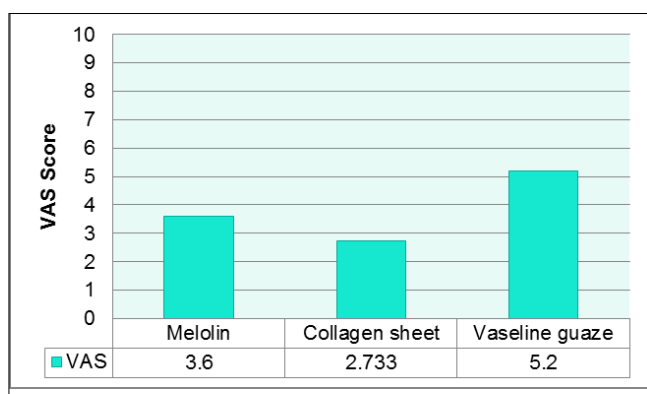


Fig 1: Mean VAS score

Complete Re-epithelialization in Melolin group was achieved in 13.53 days (Mean), Collagen sheet group in 12.73 days (Mean) and Vaseline gauze group in 15.2 days. On Comparison of the above mean values a statistically significant p-value of <.00001 was obtained (Figure 2).

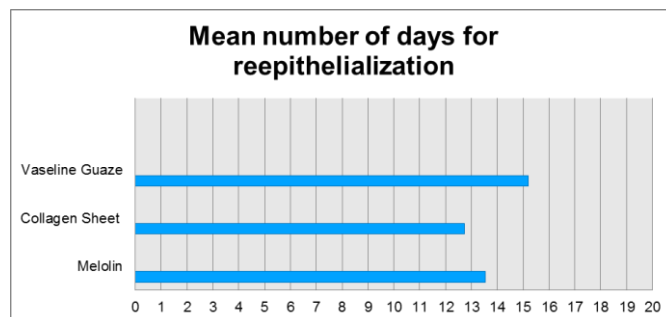


Fig 2: Mean reepithelilization days

Mean Infection rate in Melolin group was 0.2143, Collagen sheet group was 0.0667 whereas Vaseline gauze showed 0.3333. On comparison of the above mean values, it was found not to be a statistically significant with p-value of 0.203.

The healed scars showed a mean VSS score of 4.73 in Melolin group, 4.6 in Collagen sheet group and 5.2 in Vaseline gauze group. On comparison of the mean values, a statistically significant p-value of 0.000929 was obtained (Figure 3).

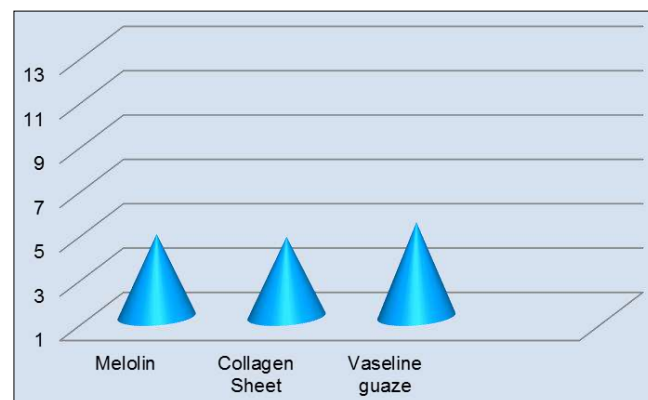


Fig 3: Mean VSS score

Discussion

Many dressing options for skin graft donor site has been described [4, 5, 6]. Our study showed Melolin and Collagen sheet are also equally effective for managing the skin graft donor site as compared to regularly used Vaseline gauze.

Melolin is a bilayered dressing material. It has a perforated polyester film as an innermost layer and an absorbent lint as an outside layer [7]. It acts as a non-adherent, moisture retaining dressing material. It is non-adherent and less traumatic to wound site. Hence, the pain associated with the dressing is reduced. Collagen sheet closely fulfils the principle "Replacing like tissue with like tissue". It resembles to a skin tissue. It acts as a scaffold for regeneration of epidermis and dermis. It resist infection as well as it reduces pain by adhering to wound bed. Healing is fastened by use of collagen sheet [8].

Our study assessed the efficacy of these three dressing material. Pain assessment by VAS score showed Melolin and Collagen sheet were better tolerated as compared to Vaseline gauze. Re-epithelialisation was better seen in Collagen sheet (Mean - 12.73 days) followed by Melolin (Mean - 13.53 days) and then Vaseline gauze (Mean - 15.2 days). Infection rate were slight

higher in Vaseline gauze group as compared with other two groups but it was not found to be statistically significant. Scar evaluation showed a better VSS score in Melolin and Collagen sheet group as compared to Vaseline gauze group.

Conclusion

Our study of Melolin, Collagen Sheet compared to regularly used Vaseline gauze on skin graft donor site showed that they are better tolerated for donor site dressing by reducing pain. They were also efficacious by having faster re-epithelialisation and low infection rates compared to Vaseline gauze.

References

1. Birol Civelek *et al.* The effect of sucralfate, an agent for gastroprotection on the healing of split thickness skin graft donor sites, *Eur J Plast Surg* 2007;30:25-28.
2. Langley GB, Sheppeard H. The visual analogue scale: its use in pain measurement. *Rheumatol int* 1985;5:145-148.
3. Baryza MJ, Baryza GA. The Vancouver Scar Scale: an administration tool and its interrater reliability. *J Burn Care Rehabil* 1995;16(5):535-8.
4. Akan M. Ice application to minimize pain in the split thickness skin graft donor site. *Aesthet Plast Surg* 2003;27:305-307.
5. Atwood AI. Calcium alginate dressing accelerates split skin graft donor site healing. *Br J Plast Surg* 1989;42:373-379.
6. Barnea Y, Amir A, Leshem D, Zaretski A, Weiss J, Shafir R, et al. Clinical comparative study of aquacel and paraffin gauze dressing for split-skin donor site treatment. *Ann Plast Surg* 2004;53:132-136.
7. Robb WA. Clinical trial of melolin: a new non-adherent dressing. *Br J Plast Surg* 1961;14:47-9.
8. Lazovic G *et al.* The application of collagen sheet in open wound healing. *Annals of burns and fire disasters* 2005;18,3:151-6.